



OPEN ACCESS

Terminology and definitions on groin pain in athletes: building agreement using a short Delphi method

Adam Weir,¹ Per Hölmich,^{1,2} Anthony G Schache,³ Eamonn Delahunt,⁴ Robert-Jan de Vos⁵

► Additional material is published online only. To view please visit the journal online (<http://dx.doi.org/10.1136/bjsports-2015-094807>).

For numbered affiliations see end of article.

Correspondence to

Dr Robert-Jan de Vos, Department of Orthopaedics, Erasmus Medical Centre, PO Box 2040, Rotterdam 3000 CA, The Netherlands; r.devos@erasmusmc.nl

Accepted 2 April 2015
Published Online First
23 April 2015

ABSTRACT

Background Groin pain in athletes occurs frequently and can be difficult to treat, which may partly be due to the lack of agreement on diagnostic terminology.

Objective To perform a short Delphi survey on terminology agreement for groin pain in athletes by a group of experts.

Methods A selected number of experts were invited to participate in a Delphi questionnaire. The study coordinator sent a questionnaire, which consisted of demographic questions and two 'real-life' case reports of athletes with groin pain. The experts were asked to complete the questionnaire and to provide the most likely diagnosis for each case. Questionnaire responses were analysed by an independent researcher. The Cohen's κ statistic was used to evaluate the level of agreement between the diagnostic terms provided by the experts.

Results Twenty-three experts participated (96% of those invited). For case 1, experts provided 9 different terms to describe the most likely diagnosis; for case 2, 11 different terms were provided to describe the most likely diagnosis. With respect to the terms provided for the most likely diagnosis, the Cohen's κ was 0.06 and 0.002 for case 1 and 2, respectively. This heterogeneous taxonomy reflects only a slight agreement between the various diagnostic terms provided by the selected experts.

Conclusions This short Delphi survey of two 'typical, straightforward' cases demonstrated major inconsistencies in the diagnostic terminology used by experts for groin pain in athletes. These results underscore the need for consensus on definitions and terminology on groin pain in athletes.

comparing studies difficult.⁶ This review on the treatment of groin pain in athletes included 72 studies, of which 33 different diagnostic terms were used.

Improving homogeneity in groin injury terminology could be achieved by a systematic expert opinion approach. The Delphi survey methodology is widely used to ascertain consensus on issues, such as diagnosing medical conditions.⁷ This predefined decision method uses standardised criteria to evaluate agreement and is therefore more valuable than less formalised consensus approaches.

Our aim was to identify the current heterogeneity of terminology used to diagnose groin pain in athletes. To assess this heterogeneity, we used a short Delphi method in a group of expert clinicians in the field of groin pain in athletes. This procedure served as part of the preparation for the first Doha Agreement Meeting on Definitions and Terminology on Groin Pain in Athletes to which the 23 participating experts (listed in the Acknowledgement section) were invited.⁸

METHODS

Design

The study was initiated and managed by researchers (AW and PH) of the 'Sports Groin Pain Centre' at Aspetar orthopaedic and sports medicine hospital, Doha, Qatar. Five researchers were involved in the survey design. All invited experts were asked to participate in a Delphi questionnaire.

Expert group selection

The invited experts were selected by the study initiators based on at least one of the following criteria: (1) three or more publications in the field of groin pain in athletes; (2) experience in scientific methodology (designing systematic review, Delphi procedure and agreement meeting); or (3) clinical expert and designated member of the conference organising committee. The experts did not represent specific organisations.

Delphi procedure

One of the initiating researchers acted as coordinator (AW) and prepared a questionnaire, which was sent to all invited experts by email. The first part of this questionnaire consisted of demographic questions. The experts were asked to provide information about: their age, sex and occupation; the number of working years since their qualification; the number of patients with groin pain evaluated per year (and the percentage of athletes in this

INTRODUCTION

Groin injuries are prevalent in sports involving rapid directional changes.^{1 2} From an anatomical perspective, the groin region includes several inter-related structures, thus the ability to precisely identify the source of the pain can be difficult.³ Symptoms may arise from gynaecological, urogenital, gastrointestinal, neurological and musculoskeletal structures.^{4 5} This complexity makes the evaluation of groin injuries challenging and likely results in the use of differing terminology by clinicians.

Groin pain terminology can therefore be confusing, leading to difficulties with the interpretation of research results. A systematic review in this issue emphasises the need for uniform terminology, as heterogeneous classification makes interpreting and



Open Access
Scan to access more
free content



CrossMark

To cite: Weir A, Hölmich P, Schache AG, et al. *Br J Sports Med* 2015;**49**: 825–827.

population); and the number of patients with groin pain evaluated in a research context (for the experts not working as clinicians).

The second part of the questionnaire consisted of two clinical case presentations in which the history, physical examination and selected imaging findings were comprehensively described. These were 'real-life' cases from the practice of the coordinating researcher. The experts all completed a standardised questionnaire and provided their diagnoses. There was no limit to the number of diagnoses that the expert could list, but the first diagnosis was regarded as the most likely and the last diagnosis as the least likely. Experts were asked to answer the questions with only the details provided; no extra information was given, so that every expert would base his or her answers on the same information. All the questions were answered in English and non-native speakers were asked to use the closest English translation of their native language diagnosis. The results were returned to the coordinator (AW) with the experts being blinded to each others' answers. Once all members had completed and returned the questionnaire, a summary of the results was circulated to the members.

Cases

Case 1 described a 27-year-old male amateur runner and soccer player with a first episode of unilateral groin pain. The history, examination and X-rays and MRI of the pelvis (both including reports from a musculoskeletal radiologist) were displayed.

Case 2 described a 31-year-old male professional soccer player with recurrent bilateral groin pain and persistent left-sided groin pain. The history, examination, X-rays of the pelvis and hips (including report), and ultrasound report from a musculoskeletal radiologist were displayed. A detailed description of these cases can be found in the online supplementary file.

Data management

All replies were collected by the coordinating researcher (AW) and analysed by an independent researcher (R-JdV). This researcher summarised the demographics of the experts and the diagnoses they provided based on the given information of the two case presentations. Data with normal distribution were displayed as mean \pm SD and skewed data as median \pm IQR. The Cohen's κ statistic was used to evaluate the level of agreement between the diagnostic terms provided by the experts. Based on the existing literature, a $\kappa < 0$ reflects 'poor', 0–0.20 'slight', 0.21–0.4 'fair', 0.41–0.60 'moderate', 0.61–0.8 'substantial' and above 0.81 'almost perfect' agreement. Negative values indicate agreement less than a value that would be expected by chance, which could be regarded as potential systematic disagreement among the experts.⁹

RESULTS

Demographics of the expert group

Twenty-four experts were contacted to participate in this short Delphi study and 23 (96%) agreed to participate. The expert group represented 11 different countries and three different continents. Their mean (SD) age was 49.7 (10.3) years and 21 (91%) were male. The group consisted of sports physicians (n=6), physiotherapists (n=6), general surgeons (n=5), orthopaedic surgeons (n=4), a radiologist, and a combined orthopaedic and general surgeon. The mean (SD) years of experience postqualification was 22.8 (8.9). The median number of groin patients (IQR) that the experts evaluated in the previous year was 150 (30–400) and a median (IQR) of which 90 (30–90) were athletes.

Diagnostic terms in case 1

For case 1, a first diagnosis was provided by all 23 experts, a second diagnosis by 13 and a third diagnosis by 3. The 23 experts provided 9 different terms to describe the first diagnosis, 11 different terms to describe the second diagnosis and 3 different terms to describe the third diagnosis (table 1).

Diagnostic terms in case 2

For case 2, a first diagnosis was provided by all 23 experts, a second diagnosis by 10 and a third diagnosis by 4. The 23 experts provided 11 different terms to describe the first diagnosis, 9 different terms to describe the second diagnosis and 4 different terms to describe the third diagnosis (table 2).

Agreement between experts

For the first, second and third diagnostic terms in case 1, the Cohen's κ was 0.06, –0.03 and –0.13, respectively. Likewise, the Cohen's κ was, respectively, 0.002, –0.01 and 0.000 for the first, second and third diagnostic terms in case 2. This result reflects a disagreement to slight agreement in the choice of diagnostic terms among the experts.

DISCUSSION

This study aimed to identify the current diagnostic terminology used for athletes with groin pain among 23 experienced researchers and clinicians from around the world. The results of this short Delphi survey confirm the disparity in current terminology. In the first case, 9 different terms were provided for the most likely diagnosis, and in the second case, 11 different terms were provided for the most likely diagnosis. There was only slight agreement in diagnostic terminology among the experts in both cases.

The results of this study illustrate that a lack of agreement on diagnostic terminology is a major problem in the field of groin pain in athletes. While different terms may in some instances refer to the same diagnosis (eg, adductor tendinitis and adductor tendinopathy), the lack of consensus on diagnostic

Table 1 The various terms used by the 23 experts to describe the diagnoses for case 1

| | First diagnosis (n=23) N (%) | Second diagnosis (n=13) N (%) | Third diagnosis (n=3) N (%) |
|--------------------------------------|---------------------------------------|--|--------------------------------------|
| Adductor-related groin pain | 6 (26) | | |
| Adductor tendinopathy | 6 (26) | 2 (9) | 1 (4) |
| Adductor enthesopathy | 4 (17) | | |
| FAI | 2 (9) | 1 (4) | 1 (4) |
| Adductor tendinitis | 1 (4) | | |
| Adductor strain | 1 (4) | 1 (4) | |
| Pubic bone stress injury | 1 (4) | | |
| Low-grade capsular/enthesitis stress | 1 (4) | | |
| Pubic bone fibrocartilage separation | 1 (4) | | |
| Osteitis pubis | | 2 (9) | |
| Adductor teno-osseous defect | | 1 (4) | |
| Adductor tear | | 1 (4) | |
| Cam lesion | | 1 (4) | |
| Pubic bone marrow oedema | | 1 (4) | |
| Pubic ring failure | | 1 (4) | |
| Pubic symphysis osteoarthritis | | 1 (4) | |
| Combination of multiple diagnoses | | 1 (4) | |
| Pubic plate tear | | | 1 (4) |
| FAI, femoroacetabular impingement. | | | |

Table 2 The various terms used to describe the diagnoses for case 2

| | First diagnosis (n=23) N (%) | Second diagnosis (n=10) N (%) | Third diagnosis (n=4) N (%) |
|---|---------------------------------------|--|--------------------------------------|
| Inguinal-related groin pain | 9 (39) | | |
| Sportsman's hernia | 3 (13) | | |
| Incipient hernia | 2 (9) | | |
| Inguinal disruption | 2 (9) | | |
| Posterior wall weakness | 1 (4) | 1 (4) | |
| Gilmore's groin | 1 (4) | | |
| Inguinal canal aponeurosis strain | 1 (4) | | |
| Inguinal ligament enthesopathy | 1 (4) | | |
| Pubic bone fibrocartilage separation | 1 (4) | | |
| Hip chondral surface damage | 1 (4) | | |
| Core muscle injury | 1 (4) | | |
| Hip labral tear | | 2 (9) | |
| Adductor tendinopathy | | 1 (4) | |
| Femoroacetabular impingement | | 1 (4) | |
| Pubic symphysis pathology | | 1 (4) | |
| Conjoined tendon enthesopathy | | 1 (4) | |
| Superficial inguinal ring insufficiency | | 1 (4) | |
| Rectus abdominis strain | | 1 (4) | |
| Combination of multiple diagnoses | | 1 (4) | 1 (4) |
| Public cleft arthritis | | | 1 (4) |
| Transversus abdominis strain | | | 1 (4) |
| Posterior wall tear | | | 1 (4) |

taxonomy makes it almost impossible to compare different study results.⁵ One systematic review in this *BJSM* issue revealed that 33 different diagnostic terms were used for groin pain in athletes,⁶ and this inconsistency meant that the data could not be pooled. The use of uniform terminology and definitions that are based on clinical findings is imperative to interpret and compare studies investigating groin pain in athletes, as well as for the implementation of research findings into clinical decision-making. To reach consensus in this terminology, an agreement meeting was planned with the group of experts following the completion of this Delphi procedure. The results of this agreement meeting are included in the June 2015 issue (#12) of *BJSM* (*Doha Agreement meeting on terminology and definitions in groin pain in athletes*). In science, consistency in the use of terminology and definitions together with minimum reporting standards can improve clinical management and quality of study design and reporting.

To our knowledge, the Delphi method has never been applied before in the field of groin pain terminology. A previous study examined the alternative approaches used by a panel of experts from a variety of specialities and the different diagnostic terms they proposed for the same patients.⁴ Our study was specifically designed to register the different diagnostic terms used by a broad range of experts. Furthermore, in order to prevent interpretation bias, the questionnaire responses were anonymised and the researchers performing the analysis were blinded as to which questionnaire was completed by each expert. A limitation of this Delphi survey is that a short version has been employed. A standard Delphi survey methodology consists of three subsequent rounds of questionnaire distribution and completion by an expert panel.¹⁰ Our short Delphi survey only consisted of

one round, because our aim was to assess the current level of agreement in terminology. A future survey among experts and among a group of novice clinicians who have read the new agreement statement on terminology could be performed to examine whether the proposed terminology in the June 2015 issue (#12) of *BJSM* facilitates improved agreement.

CONCLUSION

Many different diagnostic terms were provided by a panel of international experts evaluating the same case presentations. The level of agreement between the experts was found to be only slight for the term describing the most likely diagnosis, and slight agreement to disagreement for the terms provided to describe the other possible diagnoses. These results highlight the need for more systematic terminology and definitions when reporting on groin pain in athletes. In clinical practice, the challenge will be to implement new terminology and test whether it helps to achieve the ultimate goal—improving care of athletes.

What is already known?

Many different terms are used in the scientific literature to describe the diagnosis regarding groin pain in athletes.

What are the new findings?

The results of this short Delphi survey confirm the disparity in current terminology; the agreement between different experts on the same case was found to be poor.

Author affiliations

¹Aspetar Sports Groin Pain Center, Aspetar Orthopaedic and Sports Medicine Hospital, Doha, Qatar

²Arthroscopic Center Amager, SORC-C, Copenhagen University Hospital, Amager-Hvidovre, Denmark

³Department of Mechanical Engineering, University of Melbourne, Melbourne, Australia

⁴School of Public Health, Physiotherapy & Population Science, University College Dublin, Dublin, Ireland

⁵Department of Orthopaedics, Erasmus University Medical Centre, Rotterdam, The Netherlands

Acknowledgements The authors thank the expert group for their cooperation in this survey. The expert group consisted of the following other members: Brukner P, Ekstrand J, Griffin DR, Khan KM, Lovell G, Meyers WC, Muschawek U, Orchard JW, Paajanen H, Philippon M, Reboul G, Robinson P, Schilders E, Serner A, Silvers HJ, Thorborg K, Tyler TF, Verrall GM, Vuckovic Z.

Contributors AW designed the study, undertook the questionnaire management, collected and interpreted the data, and revised the paper. PH designed the study and revised the paper. AGS and ED interpreted the data, and revised the paper. R-JdV performed data analysis and summary, analysed and interpreted the data, and made the first draft of the paper.

Competing interests None declared.

Patient consent Obtained.

Provenance and peer review Not commissioned; externally peer reviewed.

Open Access This is an Open Access article distributed in accordance with the Creative Commons Attribution Non Commercial (CC BY-NC 4.0) license, which permits others to distribute, remix, adapt, build upon this work non-commercially, and license their derivative works on different terms, provided the original work is properly cited and the use is non-commercial. See: <http://creativecommons.org/licenses/by-nc/4.0/>

REFERENCES

- 1 Holmich P, Bradshaw C. In: Brukner P, Bahr R, Blair S, *et al.* (eds). *Brukner and Khan's Clinical Sports Medicine*. 4th edition, chapter 29. Sydney: McGraw-Hill, 2012:545–78.
- 2 Paajanen H, Ristolainen L, Turunen H, *et al.* Prevalence and etiological factors of sport-related groin injuries in top-level soccer compared to non-contact sports. *Arch Orthop Trauma Surg* 2011;131:261–6.
- 3 Ferguson M, Patricios J. What is the relationship between groin pain in athletes and femoroacetabular impingement? *Br J Sports Med* 2014;48:1074–5.
- 4 Ekberg O, Persson NH, Abrahamsson PA, *et al.* Longstanding groin pain in athletes; a multidisciplinary approach. *Sports Med* 1988;6:56–61.
- 5 Weir A. From disruption to consensus: the thousand mile journey. *Br J Sports Med* 2014;48:1075–7.
- 6 Serner A, van Eijck CH, Beumer BR, *et al.* Study quality on groin injury management remains low: a systematic review on treatment of groin pain in athletes. *Br J Sports Med* 2015 Published Online First.
- 7 Fink A, Kosecoff J, Chassin M, *et al.* Consensus methods: characteristics and guidelines for use. *Am J Public Health* 1984;74:979–83.
- 8 Weir A, Brukner P, Delahunt E, *et al.* Doha Agreement meeting on terminology and definitions in groin pain in athletes. *Br J Sports Med* 2015.
- 9 Landis JR, Koch GG. The measurement of observer agreement for categorical data. *Biometrics* 1977;33:159–74.
- 10 Sereda M, Hoare DJ, Nicholson R, *et al.* Consensus on hearing aid candidature and fitting for mild hearing loss, with and without tinnitus: Delphi review. *Ear Hear* 2015 Published Online First.

Supplementary file – description of the presented cases

Case 1

History

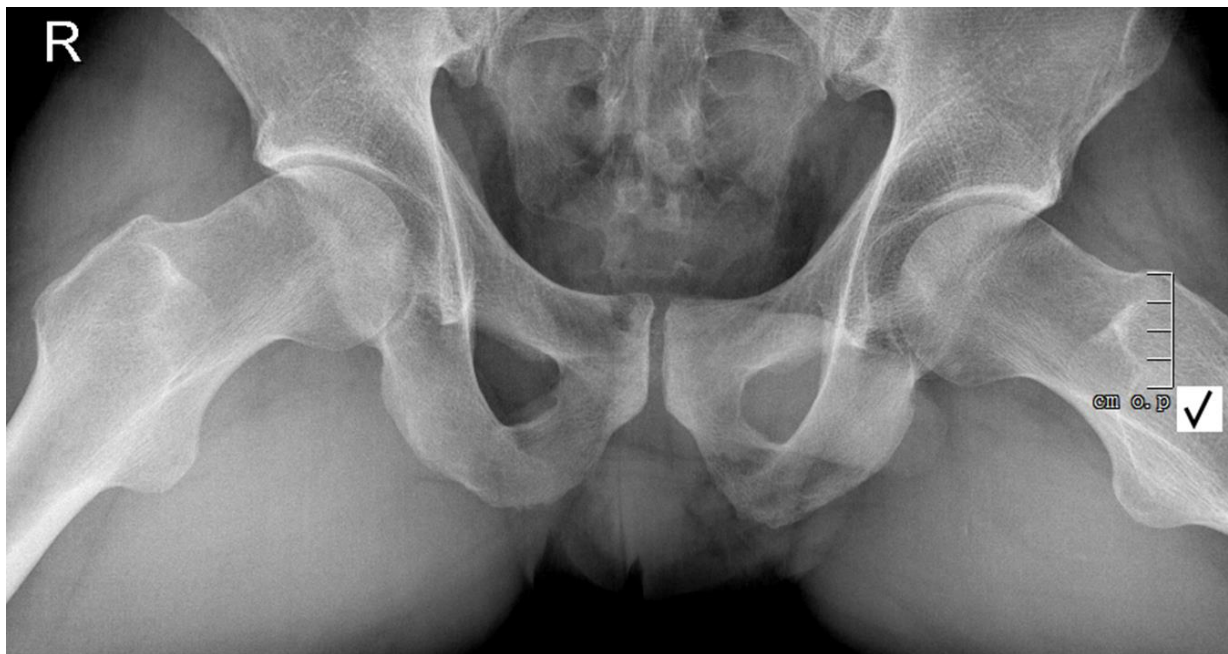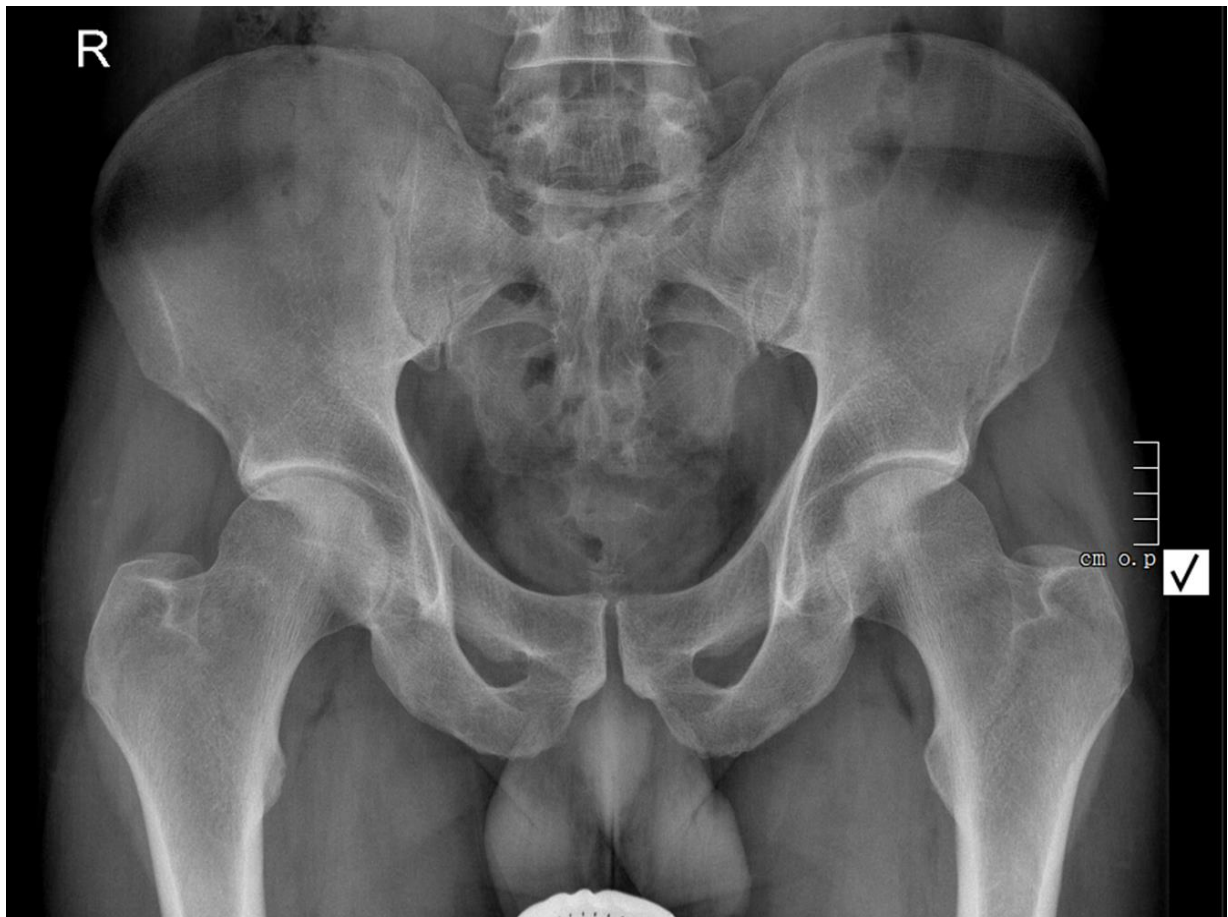- 27 year old male amateur runner and soccer player
- Normally trains on a daily basis – 3 times a week football and 3 times a week running
- No previous history of groin injuries
- Gradual onset 1st episode left sided groin pain – over the past 8 weeks
- Pain located around proximal adductors and on insertion on the pubic bone
- The pain is worse on sprinting, kicking and changing directions in football and mild pain at the end of 5km runs
- Initially able to train and play without performance being affected
- Since 2 weeks pain after warming-up
- Now unable to sprint fully or kick with any power
- Past medical history: none
- Previous injury: 2 years ago lateral ankle ligament injury right side, good recovery. Several contusions that did not need medical attention
- Medically fit, no health issues
- Medication: none. No allergies

Physical examination

- General – healthy athletic male. Mild varus alignment both legs
- Lumbar spine – normal pain free range of motion
- Horizontal pelvis
- Hip: Normal pain free flexion. 20° internal and 50° external rotation bilaterally. No pain on FABER or FADIR test
- Inspection groin region: no swelling, bruising or scars
- Palpation: pain on palpation of left proximal adductor tendon and attachment at the pubic bone
- No pain on palpation of iliopsoas, rectus abdominus, inguinal canal/ring, inguinal ligament, conjoined tendon, other structures in the groin region.
- Resistance testing:
 - Hip adduction 0°, 45°, 90° – pain felt at left adductor insertion, moderate strength
 - Hip flexion 0° and 90° – no pain, good strength
 - Hip abduction 0° and 45° – no pain, good strength
 - Abdominal sit up 45° hip flexion – no pain, good strength
 - Oblique sit ups 45° hip flexion – no pain, good strength
- Stretch tests: symmetrical length of adductors with mild pain on stretching of left adductors felt in proximal adductors. Symmetrical length on testing hip flexors and no pain on stretching

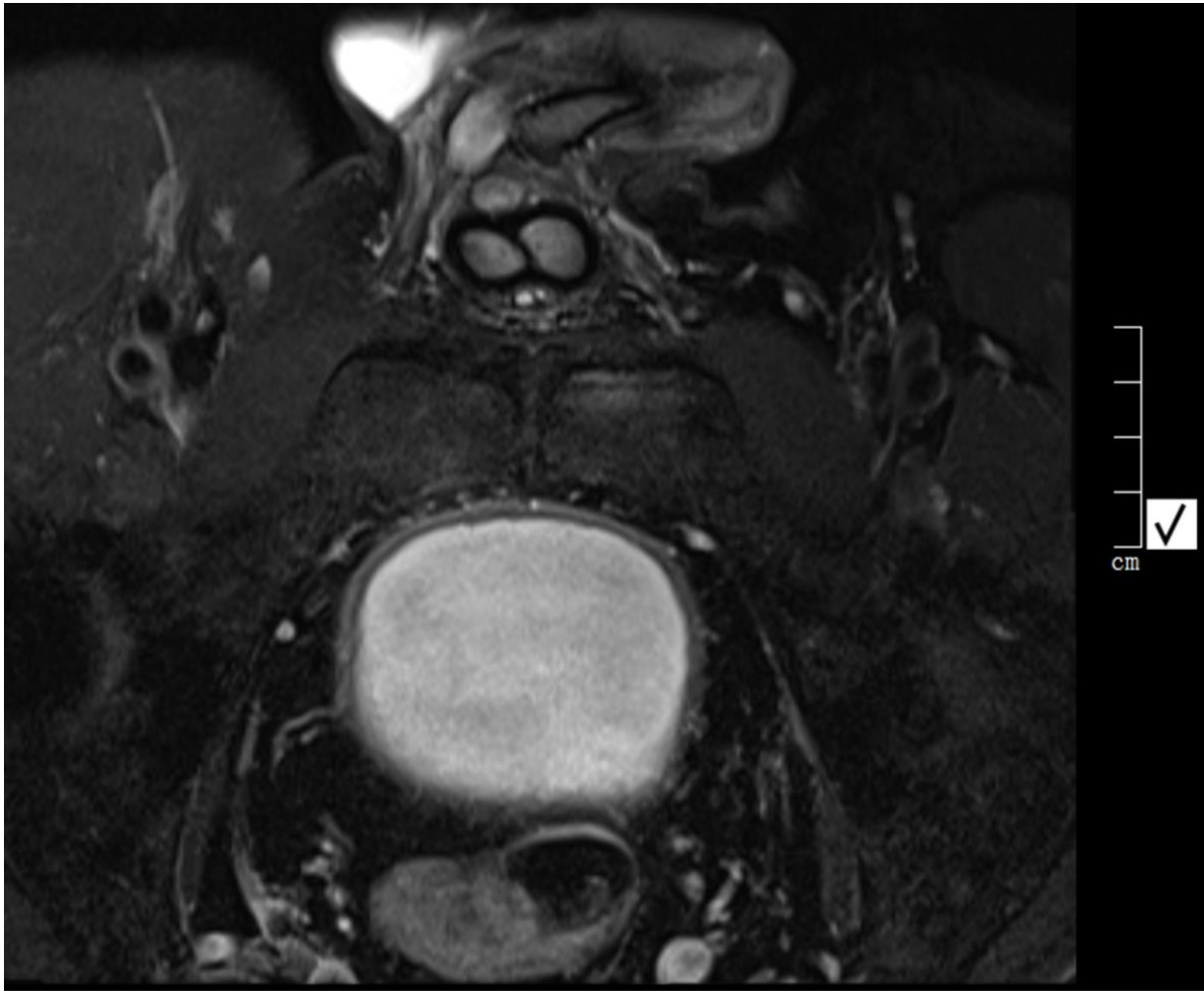
Imaging

X-rays of pelvis (AP and Dunn view)



Report of the musculoskeletal radiologist: There is a moderate reduction of the articular surface of the lateral articular surface of the right hip. There is a reduced head –neck offset junction on the Dunn view.

MRI of pelvis (Axial view)



Report of the musculoskeletal radiologist: There is bone marrow oedema of the left pubic ramus. There is no visible cleft or tear of the left adductor tendon but there is adductor longus enthesiopathy. Cystic changes at right adductor tendon origin due to previous injury. No rectus femoris abnormality. No signs of advanced pubic symphysis osteoarthritis. Normal fascia transversalis. Conclusion: left adductor longus tendinopathy without associated cleft or tear.

Case 2

History

- 31 year old male professional soccer player
- Normally trains on a daily basis
- Several episodes of pain in both adductors and in inguinal region over the years
- Normally treated with short duration of rest, modified training and some oral anti-inflammatories
- In the past the pain settled with 2-3 weeks
- Now: Gradual onset left sided groin pain – over the past 6 weeks
- Pain located around inguinal region on the left side
- The pain is worse on sprinting and changing directions
- Initially able to train and play without performance being affected
- Since 4 weeks pain after warming-up
- Now unable to sprint fully or change direction at speed
- Past medical history: right-sided partial medial meniscectomy
- Previous injury: 5 years ago right-sided partial medial meniscectomy, good recovery. Several contusions that did not need medical attention. Previous hamstrings strain left side 3 years ago with good recovery
- Medically fit, no health issues
- Medication: none. No allergies

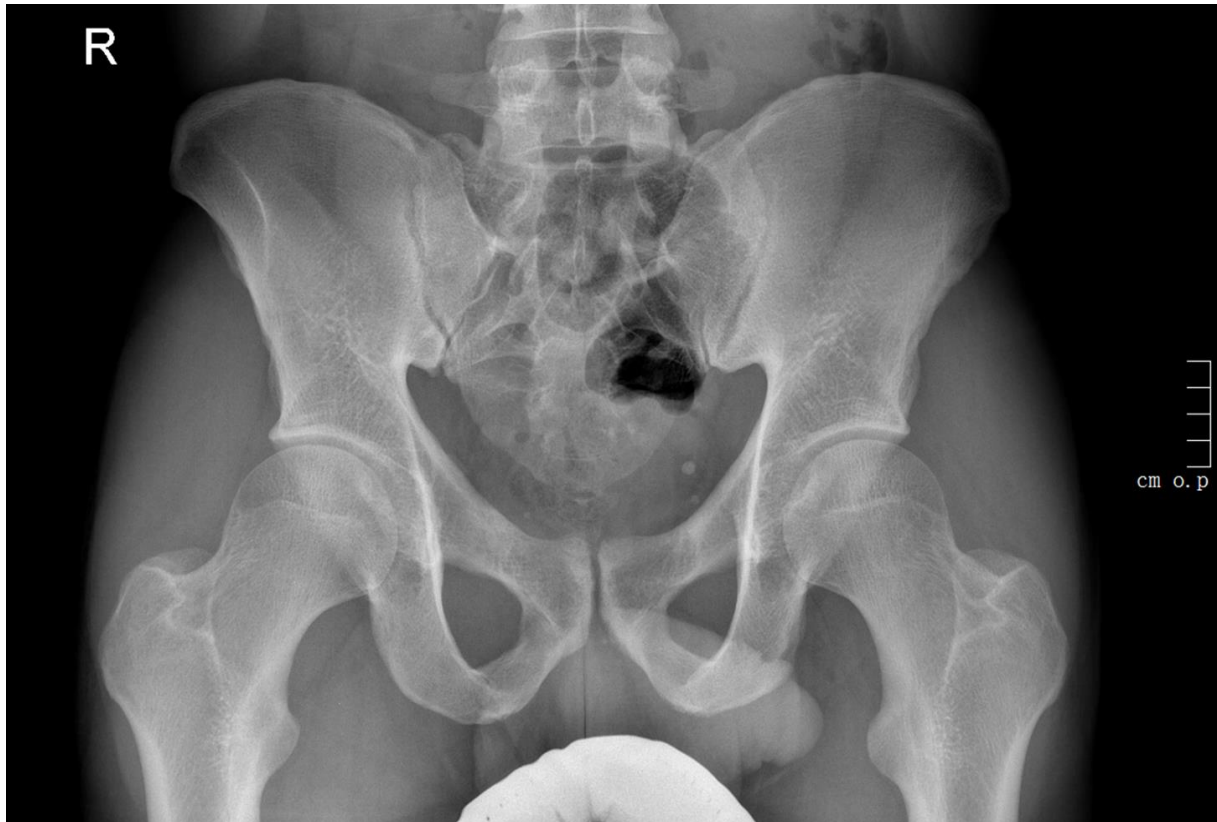Physical examination

- General – healthy athletic male. Mild varus alignment both legs
- Lumbar spine – normal pain free range of motion
- Horizontal pelvis
- Hip: Normal pain free flexion. 10° internal and 40° external rotation bilaterally. No pain on FABER or FADIR test
- Inspection groin region: no swelling, bruising or scars
- Palpation: Pain on palpation of the left external inguinal ring, conjoined tendon and inguinal ligament. There is no palpable inguinal hernia. No pain on palpation of proximal adductor tendon or attachment at the pubic bone. No pain on palpation of iliopsoas, rectus abdominus or other structures in the groin region
- Resistance testing:
 - Hip adduction 0°, 45°, 90° – no pain, good strength
 - Hip flexion 0° and 90° – no pain, good strength
 - Hip abduction 0° and 45° – no pain, good strength
 - Abdominal sit up in 45° hip flexion – pain in left inguinal region, good strength
 - Oblique sit ups 45° hip flexion – pain in left inguinal region, good strength

- Stretch tests: symmetrical length of adductors with no pain on stretching. Symmetrical length on testing hip flexors and no pain on stretching

Imaging

X-rays of pelvis (AP view)



Report of the musculoskeletal radiologist: Hip and sacroiliac joints normal. No soft tissue abnormality. Moderate sclerosis of pubic symphysis.

Ultrasonography

Report of the musculoskeletal radiologist: There is no musculotendinous strain. No avulsion of the adductor longus tendon. Rectus abdominus muscles normal. The psoas muscles are normal. There is moderate bilateral bulging of the posterior wall of the inguinal canal, more on the left. No inguinal hernia.