


American Medical Society for Sports Medicine sports ultrasound curriculum for sports medicine fellowships

Mederic M Hall ¹, David Bernhardt,² Jonathan T Finnoff,^{3,4} Douglas Hoffman,⁵ Melody Hrubes,⁶ Kenneth Mautner,⁷ Ashwin Rao,⁸ Jeremiah Wayne Ray,⁹ Jay Smith,³ Anna Waterbrook¹⁰

► Additional material is published online only. To view, please visit the journal online (<http://dx.doi.org/10.1136/bjsports-2021-103915>).

For numbered affiliations see end of article.

Correspondence to

Dr Mederic M Hall, Orthopedics and Rehabilitation, The University of Iowa Roy J and Lucille A Carver College of Medicine, Iowa City, IA 52242, USA; mederic-hall@uiowa.edu

This article is being simultaneously published in the British Journal of Sports Medicine and Clinical Journal of Sport Medicine.

Accepted 14 February 2021
Published Online First 9 May 2021

ABSTRACT

Sports ultrasound is commonly used by sports medicine physicians to enhance diagnostic and procedural accuracy. This expert consensus statement serves as an update to the 2015 American Medical Society for Sports Medicine recommended sports ultrasound curriculum for sports medicine fellowships. Although written in the context of the American sports medicine fellowship training model, we present a stepwise progression in both diagnostic and interventional sports ultrasound that may be applicable to the broader sports medicine community. The curriculum is divided into 12 units with each unit including didactic instructional sessions, practical hands-on instruction, independent scanning practice sessions and mentored clinical experience. To assist with prioritisation of learning, we have organised relevant pathology and procedures as *essential*, *desirable* and *optional*. The expanded content can serve as an outline for continuing education postfellowship or for any physician to further advance their sports ultrasound knowledge and skill. We also provide updated scanning protocols, sample milestones and a sample objective structured clinical examination to aid fellowships with implementation of the curriculum and ongoing assessment of fellow progress.

INTRODUCTION

The American Medical Society for Sports Medicine (AMSSM) developed a recommended musculoskeletal ultrasound curriculum for sports medicine fellows in 2010.¹ The curriculum was revised in 2015 and the term sports ultrasound (Sports US) was introduced to reflect the use of ultrasound by sports medicine physicians for both musculoskeletal and non-musculoskeletal applications.² Since that time, Sports US has become nearly ubiquitous in sports medicine clinics, training rooms and at sporting events throughout the USA. In 2017, ultrasound training was formally added to the Accreditation Council for Graduate Medical Education (ACGME) core programme requirements for sports medicine fellowships, solidifying the importance of ultrasound as a diagnostic and procedural tool for the sports medicine physician. This current revision recognises the ongoing evolution of Sports US in practice and aims to provide updated training guidelines to ensure that sports medicine fellows are prepared to integrate Sports US successfully into their practice on completion of fellowship.

Working group selection and process

The AMSSM Sports Ultrasound Committee Chair (MMH) was tasked with assembling a working group to review the 2015 curriculum and provide updates as needed. An expert panel was carefully selected to include diversity of primary specialty (emergency medicine, family medicine, paediatrics and physical medicine and rehabilitation) and significant experience in both fellowship education and the clinical applications of Sports US. The group was approved by the AMSSM Board of Directors.

The prior curricula were reviewed by the entire panel and opportunities for improvements were identified. Similar curricula from other specialty societies also were reviewed. Informal feedback was requested during AMSSM Sports Ultrasound Committee meetings and through electronic communications from both fellowship directors and prior/current fellows. The group was then divided into smaller working groups to address individual sections. These groups reviewed the key literature and developed a working outline which was brought to the larger group for discussion. Consensus was reached in all areas with every member of the panel approving the final recommended curriculum.

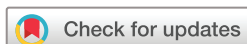Key updates

Several notable changes have been made to the curriculum. First, the scanning protocols have been updated and provide an educational/instructional tool to assist with familiarisation of regional anatomy relevant to the practice of sports medicine (online supplemental appendix 1). Sports medicine fellows should strive to become competent in the scanning techniques and normal anatomy listed. While not meant to be prescriptive for clinical practice, online supplemental appendix 1 is organised to facilitate identification of structures needed for a complete regional ultrasound examination. Structures listed as *required* should be prioritised during the learning process and strongly considered when performing a complete regional examination. The *optional* structures often will be included in addition to the *required* structures based on the specific clinical question or independently as part of a focused limited examination.

In addition, the concept of *core competencies* has been replaced. We now characterise individual pathologies and procedures as *essential*, *desirable* or *optional*. *Essential pathology and procedures* should be prioritised during the sports medicine fellowship as they are integral to the practice of sports medicine. *Desirable pathology and procedures* are those



► <http://dx.doi.org/10.1136/bjsports-2021-104667>



© Author(s) (or their employer(s)) 2022. No commercial re-use. See rights and permissions. Published by BMJ.

To cite: Hall MM, Bernhardt D, Finnoff JT, et al. *Br J Sports Med* 2022;**56**:127–137.

that may be less common or more advanced but are of significant importance to the sports medicine physician. These should be introduced after the fellow becomes competent in the essential concepts. Finally, *optional pathology and procedures* have been detailed to serve as aspirational content recognising that many of these concepts will require continued learning beyond fellowship training. This applies to the *optional* structures listed in the scanning protocols as well. The fundamentals, however, should be in place for all sports medicine physicians to develop these skills.

Another significant change to this curriculum is the formal inclusion of Sports US evaluation of acute trauma. Although the previous curriculum introduced non-musculoskeletal applications such as the FAST (focused assessment with sonography for trauma) examination, only musculoskeletal core competencies were included in the curriculum. Herein, we include a practical curriculum in applications and protocols relevant to sports medicine practice in the field. With the increasing availability of on-site ultrasound capabilities, these applications have moved beyond theoretical and are now being actively used by many sports medicine physicians to provide prompt diagnosis and aid in critical decision making. While the role of ultrasound in evaluation and management of acute trauma continues to be defined in sports medicine practice, these concepts are supported in the Emergency Medicine and Critical Care literature.^{3,4}

Finally, in keeping with recent developments in graduate medical education, we have provided suggested milestones (online supplemental appendix 2) to aid in the evaluation of fellow progression and competency in Sports US. These milestones now recognise the importance of identifying pathology and performing procedures and generating a detailed and accurate report. Appropriate reporting of diagnostic findings and procedural details is an essential skill and has been integrated into the curriculum. A sample objective structured clinical examination (OSCE) is also included (online supplemental appendix 3).

OVERVIEW OF CURRICULUM STRUCTURE

The curriculum has been organised into 12 units as presented in [box 1](#). Each unit follows a general progression beginning with introduction of core concepts followed by progression of skills in acquiring and interpreting diagnostic images and finally interventional procedural techniques. The core components of the curriculum continue to be: (1) didactic instructional sessions, (2) didactic practical hands-on instruction, (3) supplementary education and (4) mentored clinical experience.

Didactic instructional sessions

Didactic instruction can occur via a dedicated Sports US course or scheduled teaching sessions during fellowship. Multiple online resources have been developed to assist programmes in meeting this requirement and can be found on the AMSSM website (<https://www.amssm.org/>). Each Fellowship programme is encouraged to provide the fellow with further pertinent information relevant to each educational unit. Some online resources are provided in online supplemental appendix 4.

Unit 1 includes introductory lectures discussing ultrasound principles and physics, image acquisition and optimisation, normal and pathological appearance of tissues, ultrasound artefacts, advantages and limitations of ultrasound relative to other imaging modalities, appropriate labelling and reporting, coding and billing and appropriate ultrasound unit maintenance and cleaning. Unit 2 reviews pharmacological principles of

Box 1 Sports ultrasound curriculum outline*†

1. Principles of sports ultrasound and introduction to diagnostic scanning techniques.
2. Introduction to ultrasound-guided interventional procedures.
3. Sports ultrasound evaluation of trauma and other acute conditions.
4. Sports ultrasound of the shoulder (including neck, chest and upper arm as indicated).
5. Sports ultrasound of the elbow and forearm.
6. Sports ultrasound of the wrist.
7. Sports ultrasound of the hand and finger.
8. Sports ultrasound of the hip and pelvis.
9. Sports ultrasound of the thigh.
10. Sports ultrasound of the knee.
11. Sports ultrasound of the leg and ankle.
12. Sports ultrasound of the foot.

*Each unit includes: (1) didactic instructional sessions, (2) didactic practical hands-on instruction, (3) supplementary educational activities including independent scanning practice sessions and (4) mentored clinical experience.

†Units 4–12 are organised to facilitate a stepwise learning progression: (1) review of scanning protocols and normal anatomy, (2) relevant regional pathology and (3) ultrasound-guided interventional procedures associated with the region.

commonly used medications, patient selection, sterile technique, ergonomics, procedural risks and treatment of common adverse events and introduces the techniques of ultrasound-guided interventional image optimisation and needle/device dynamic tracking using both in-plane and out-of-plane techniques. Unit 3 introduces the topic of Sports US evaluation of acute trauma. This topic may be less familiar to some fellows and faculty. Programmes may consider partnering with Emergency Medicine colleagues as needed; online resources are being developed for the AMSSM website (<https://www.amssm.org/>). Didactic instruction should introduce trauma scanning techniques/protocols and review indications, limitations and the importance of repeat examinations and complimentary advanced imaging.

The remaining units are divided by body region and the didactic instructional sessions are organised into three sections to facilitate a stepwise learning progression: (1) review of scanning protocols and normal anatomy; (2) relevant regional pathology and (3) ultrasound-guided interventional procedures associated with that region. Each of these sections will be supplemented with practical hands-on instruction, self-directed independent scanning sessions and clinical experiences as detailed below. It is recommended that fellows demonstrate both the knowledge and skills associated with each section prior to progressing to the next section (eg, competency in the diagnostic shoulder scanning protocol and recognition of all relevant anatomy should precede instruction and practice in interventional procedures about the shoulder).

Didactic practical hands-on instruction

Hands-on didactic practice sessions should be completed under the direct supervision of a qualified mentor. A qualified mentor is defined as an individual who has completed an accredited sports medicine fellowship since the addition of ultrasound to the ACGME core programme requirements and/or who has met the qualifications outlined by the American Institute of Ultrasound in Medicine (AIUM) Training Guidelines (<https://www.aium.org/>).

aium.org/). During these sessions, fellows should apply the knowledge and skills acquired during the didactic instructional sessions in a controlled and supervised environment.

The didactic practical hands-on sessions should include the following: (1) practice and demonstration of performing a complete ultrasound evaluation of each region listed in the scanning protocols including proper image optimisation and acquisition (see online supplemental appendix 1); (2) practice and demonstration of proper image labelling and storage. Transfer of images should follow guidelines outlined by the Health Insurance Portability and Accountability Act; (3) review of saved images from the fellow's self-directed practice scanning sessions and provision of constructive feedback regarding study completeness, proper image optimisation, labelling, storage and transfer. Deficiencies should be reconciled during subsequent scanning sessions; (4) practice and demonstration of interventional skills, preferably using unembalmed cadaveric specimens. If cadaveric specimens are not available, the fellow should practice appropriate imaging of target structures on live models and should practice needle/device imaging and guidance techniques using turkey breasts, pig feet, pig legs, firm tofu, phantoms or another appropriate medium. As the fellow's skills improve, more advanced Sports US examination techniques and interventional procedures should be introduced into the didactic practice sessions (see *desirable* and *optional* categories below).

Supplementary education

The fellow's education should include supplementary educational experiences to reinforce the knowledge and skills gained during the didactic sessions and mentored clinical experience. Independent scanning practice sessions are required, and their importance should be stressed. It is only through regular scanning that proficient technique can be achieved. These sessions should include obtaining normal complete regional scans for review with the fellow's mentor. During these sessions, the fellow should also practice positioning for procedures and ultrasound-guided needle/device tracking using the appropriate medium as describe above.

Other recommended supplementary experiences include: (1) using online education material including the AMSSM Sports US Online Didactics, virtual meetings and webinars; (2) reading reference texts and journal articles; (3) presenting Sports US related articles at journal club and (4) attending live Sports US conferences and presentations. The integration of recommended supplementary educational experiences may vary from fellowship to fellowship based on available resources and the overall curriculum structure.

Mentored clinical experience

This component of the fellow's Sports US training process is required to ensure that the fellow is proficient in performing the recommended diagnostic and interventional Sports US skills in clinical practice. As knowledge and skills are acquired through the didactic and independent scanning sessions, the fellow should, under the direct supervision of a qualified mentor, begin to perform diagnostic scanning and interventional procedures on patients in a clinical setting. During this experience, fellows should practice and eventually demonstrate competency as described in the sample milestones (see online supplemental appendix 2). Special attention should be paid to obtaining proficiency in performing all regional examinations, recognising *essential* pathological conditions and performing *essential* interventional procedures. Once these skills are established, the fellow

may progress through the *desirable* and *optional* pathology and interventional procedures as time and resources allow. As the fellow gains proficiency in the clinical applications of Sports US, the level of supervision may be modified as allowed by institutional policy governing teaching rules.

RECOMMENDED CURRICULUM AND LEARNING OBJECTIVES FOR SPORTS ULTRASOUND TRAINING

The following curriculum has been organised into units. Suggested resources and references have been grouped at the end of the curriculum and are available on the AMSSM website (<https://www.amssm.org/>). While the curriculum should be thought of as fluid and longitudinal throughout the year, introductory Units 1 and 2 should be completed first and prioritised early in the fellowship year. Unit 3 may also be considered earlier in the fellowship year given the increased likelihood of trauma and other acute conditions during contact and collision sports that are more common in the fall. The order of the remaining units may be modified as needed and will likely be taught concurrently as the fellow progresses from essential to desirable to optional content. We strongly recommend, however, achieving diagnostic proficiency of a specific region prior to progressing to interventional procedures for that region. Fellows should not be taught to put a needle or other device through a structure they cannot name and readily identify.

Given the unpredictable nature of acute trauma in sport and variance in presentation of specific conditions, we recognise that it may not be feasible for fellows to acquire multiple images of the pathological state for each of the recommended units. The minimum requirement should include hands on instruction in the scanning protocols and independent normal scans submitted for review. Becoming familiar with the absence of pathology is essential. Fellowship programmes could consider partnering outside of the traditional sports medicine and primary specialty clinics as needed for exposure to relevant examples of pathological studies. This could include the emergency department, Orthopaedic and Rheumatology clinics, as well as medicine and intensive care wards. Every effort should be made to ensure that fellows achieve competence in the core concepts represented by the *essential pathology and procedures* listed below.

This curriculum allows flexibility for programmes that have varying prioritisation of ultrasound training in their overall fellowship curriculum. This flexibility will fulfil ACGME programme requirements, AIUM training guidelines and prerequisites for the Alliance for Physician Certification & Advancement Registered in Musculoskeletal sonography certification. Successful completion will ensure the acquisition of enough Sports US skills to allow independent practice in diagnostic and interventional Sports US.

UNIT 1: PRINCIPLES OF SPORTS ULTRASOUND AND INTRODUCTION TO DIAGNOSTIC SCANNING TECHNIQUES

Didactic instructional sessions

1. Identify and discuss the function of basic controls on an ultrasound machine console, including:
 - Transducer selection.
 - Presets.
 - Depth.
 - Focal zone/focal region.
 - Gain.
 - Time gain compensation/depth gain compensation.
 - Zoom (including read zoom and write zoom).
2. Instruction on basic ultrasound physics, including:

- How an ultrasound image is generated.
- Inter-relationship of machine controls (eg, frequency, resolution and depth).
- Doppler imaging (difference between power Doppler and colour Doppler).
- 3. Discuss how to optimise an ultrasound image.
 - Superficial structures.
 - Deep structures.
- 4. Discuss the benefits and limitations of ultrasound relative to other imaging modalities.
- 5. Understand the use of Doppler for imaging vascular structures including neovessels.
- 6. Describe transducers movements.
 - Slide.
 - Heel-toe.
 - Tilt.
 - Compression.
 - Rotation.
 - Pivot.
 - Stand-off and oblique stand-off.
- 7. Describe the normal ultrasound appearance of bone, cartilage, ligament, fascia, fat, muscle, nerve, tendon, thoracoabdominal structures and vasculature.
- 8. Discuss the common abnormal ultrasound appearances of bone, cartilage, ligament, fascia, fat, muscle, nerve, tendon, thoracoabdominal structures and vasculature.
- 9. Identify and discuss the source and/or implications of ultrasound artefacts, including:
 - Acoustic shadowing.
 - Anisotropy.
 - Through transmission.
 - Refraction.
 - Reverberation.
- 10. Describe appropriate labelling of ultrasound images.
 - Use of text insertion and arrows.
 - Appropriate use of measurement callipers.
- 11. Understand how to capture, store and transfer ultrasound images.
- 12. Discuss use of appropriate terminology.
- 13. Discuss appropriate diagnostic reporting and coding/billing per institutional guidelines.
- 14. Understand appropriate ultrasound maintenance and transducer cleaning/disinfection.

Didactic practical hands-on instruction

1. Introduction to the ultrasound cart.
2. Review of institutional ultrasound procedure room policies and protocols.
3. Demonstration of basic scanning techniques including image optimisation, transducer movements, patient and physician ergonomics and so on.

UNIT 2: INTRODUCTION TO ULTRASOUND-GUIDED INTERVENTIONAL PROCEDURES

Didactic instructional sessions

1. Understand the rationale for ultrasound-guided procedures.
 - Indications.
 - Contraindications.
2. Describe appropriate labelling of ultrasound interventional images.
3. Understand how to capture, store and transfer ultrasound procedure images.
4. Discuss use of appropriate procedural terminology.

5. Discuss appropriate procedural reporting.
6. Understand coding and billing guidelines including requirements for image archiving.
7. Discuss general principles of ultrasound-guided procedures.
 - Patient selection.
 - Ergonomics.
 - Sterile technique.
 - Describe the advantages and disadvantages of needle tracking using an in-plane versus out-of-plane approach and provide clinical examples of when each approach may be beneficial.
 - Understand image optimisation for needle location, relocation and dynamic tracking, including transducer manipulation, jiggling, rotation and stylet movement.

Didactic practical hands-on instruction

1. Image a needle using an in-plane and out-of-plane approach under ultrasound guidance in a phantom, turkey breast, cadaveric specimen, or other imaging medium.
2. Demonstrate the ability to efficiently relocate a lost needle during both an in-plane and out-of-plane needle tracking approach.
3. Demonstrate the ability to guide a needle into a target region or structure using both an in-plane and out-of-plane approach in a phantom, turkey breast, cadaveric specimen or other imaging medium.

UNIT 3: SPORTS ULTRASOUND EVALUATION OF TRAUMA AND OTHER ACUTE CONDITIONS

Didactic instructional sessions

1. The rationale for ultrasound assessment of the acutely injured athlete.
2. Limitations of ultrasound in the setting of acute trauma.
3. Indications for repeat ultrasound examinations or complementary advanced imaging.
4. Specific applications and techniques.
 - General principles of fracture and dislocation evaluation.
 - Skin and soft tissue (including foreign body identification and differentiation of cellulitis from abscess).
 - Thoracoabdominal trauma.
 - Introduction to vascular ultrasound (venous thrombosis).
 - Ocular trauma.
 - Collapsed athlete.
 - Shortness of breath/pulmonary evaluation.

Didactic practical hands-on instruction

1. Hands-on instruction in diagnostic scanning protocols.
2. Supervised practice of diagnostic scanning protocols
 - Appropriate patient positioning.
 - Transducer selection.
 - Ergonomics.
 - Technique.

Supplementary education and mentored clinical experience

1. *Independent examinations* (three separate normal scans demonstrating the structures and protocols from online supplemental appendix 1 are to be submitted to the mentor for review; see Milestones Level 2, online supplemental appendix 2).
2. *Essential pathology and protocols* (demonstrative cases should be submitted for review, including draft reports; see Milestones Level 3, online supplemental appendix 2).
 - Common sites of fracture.

- Rib.
 - Clavicle.
 - Distal radius/ulna.
 - Metacarpal.
 - Fibula.
 - Metatarsal.
 - Glenohumeral joint dislocation.
 - Phalanx dislocation.
 - eFAST (extended focused assessment of sonography in trauma).
 - Differentiation of cellulitis from abscess.
 - Identification of superficial foreign body.
3. *Desirable pathology and protocols* (demonstrative cases should be submitted for review, including draft reports; see Milestones Level 4, online supplemental appendix 2).
 - Scaphoid fracture.
 - Other long bone fractures.
 - Ocular trauma assessment.
 - RUSH (Rapid ultrasound in hypotension).
 4. *Optional pathology and protocols* (demonstrative cases should be submitted for review, including draft reports; see Milestones Level 5, online supplemental appendix 2).
 - Other non-long bone extremity fractures.
 - Other joint dislocation.
 - Identification of superficial and deep venous thrombosis.
 - Pulmonary assessment.
 - Limited cardiac assessment for evaluation of pericardial effusion and global systolic function.

UNIT 4: SPORTS ULTRASOUND OF THE SHOULDER (INCLUDING NECK, CHEST AND UPPER ARM AS INDICATED)

Didactic instructional sessions

1. Review scanning protocols and online live scanning demos.
2. Pathology lectures.
3. Procedures lectures.

Didactic practical hands-on instruction

1. Hands-on instruction in diagnostic scanning protocols and procedural technique.
2. Supervised practice of diagnostic scanning protocols and procedural image acquisition
 - Appropriate patient positioning.
 - Transducer selection.
 - Ergonomics.
 - Technique.
3. As resources allow, it is recommended that ultrasound-guided procedures be practiced on an unembalmed cadaveric specimen. If this is not feasible, then fellows should practice all aspects of needle visualisation and tracking using other appropriate medium. The principles of the procedures listed below should be reviewed in a formal didactic setting.

Supplementary education and mentored clinical experience

1. *Independent complete regional examinations* (three separate normal scans are to be submitted to the mentor for review; see Milestones Level 2, online supplemental appendix 2).
2. *Essential pathology* (demonstrative cases should be submitted for review, including draft reports; see Milestones Level 3, online supplemental appendix 2).
 - Subacromial-subdeltoid bursitis.
 - Subacromial impingement (at acromion or coracoacromial ligament).
 - Rotator cuff tendinosis.

- Full thickness rotator cuff tear.
 - Long head of the biceps tendinopathy.
 - Glenohumeral joint effusion and/or synovitis.
 - Acromioclavicular joint osteoarthritis.
 - Acromioclavicular joint sprain.
3. *Essential procedures* (demonstrative cases should be submitted for review, including draft reports; see Milestones Level 3, online supplemental appendix 2).
 - Intra-articular glenohumeral joint aspiration/injection.
 - Intra-articular acromioclavicular joint injection.
 - Subacromial-subdeltoid bursa injection.
 - Biceps tendon sheath injection.
 4. *Desirable pathology* (demonstrative cases should be submitted for review, including draft reports; see Milestones Level 4, online supplemental appendix 2).
 - Long head of biceps subluxation/dislocation.
 - Rotator cuff partial thickness tear.
 - Spinoglenoid notch cyst.
 - Fatty infiltration and/or atrophy of the rotator cuff muscles.
 - Pectoralis major muscle and/or tendon tear.
 5. *Desirable procedures* (demonstrative cases should be submitted for review, including draft reports; see Milestones Level 4, online supplemental appendix 2).
 - Barbotage of calcific tendinopathy.
 - Rotator interval approach to glenohumeral joint injection.
 6. *Optional pathology* (demonstrative cases should be submitted for review, including draft reports; see Milestones Level 5, online supplemental appendix 2).
 - Adhesive capsulitis (ie, coracohumeral ligament thickening, hyperaemia and so on).
 - Subcoracoid impingement.
 - Radial neuropathy.
 - Axillary neuropathy (eg, quadrilateral space syndrome, post-traumatic and so on).
 - Brachial plexopathy.
 - Sternoclavicular joint osteoarthritis.
 - Sternoclavicular joint effusion and/or synovitis.
 - Sternoclavicular joint sprain with or without instability.
 7. *Optional procedures* (demonstrative cases should be submitted for review, including draft reports; see Milestones Level 5, online supplemental appendix 2).
 - Suprascapular nerve block.
 - Sternoclavicular joint aspiration/injection.
 - Tenotomy with or without debridement of rotator cuff.

UNIT 5: SPORTS ULTRASOUND OF THE ELBOW AND FOREARM

Didactic instructional sessions

1. Review scanning protocols and online live scanning demos.
2. Pathology lectures.
3. Procedures lectures.

Didactic practical hands-on instruction

1. Hands-on instruction in diagnostic scanning protocols and procedural technique.
2. Supervised practice of diagnostic scanning protocols and procedural image acquisition.
 - Appropriate patient positioning.
 - Transducer selection.
 - Ergonomics.
 - Technique.

3. As resources allow, it is recommended that ultrasound-guided procedures be practiced on an unembalmed cadaveric specimen. If this is not feasible, then fellows should practice all aspects of needle visualisation and tracking using other appropriate medium. The principles of the procedures listed below should be reviewed in a formal didactic setting.

Supplementary education and mentored clinical experience

1. *Independent complete regional examinations* (three separate normal scans should be submitted for review; see Milestones Level 2, online supplemental appendix 2).
2. *Essential pathology* (demonstrative cases should be submitted for review, including draft reports; see Milestones Level 3, online supplemental appendix 2).
 - Common extensor tendinopathy.
 - Common flexor tendinopathy.
 - Ulnar collateral ligament injury with or without instability.
 - Ulnar neuropathy at the elbow with or without instability.
3. *Essential procedures* (demonstrative cases should be submitted for review, including draft reports; see Milestones Level 3, online supplemental appendix 2).
 - Intra-articular elbow joint aspiration/injection.
 - Peritendinous or intratendinous injection of the common extensor tendon origin.
 - Peritendinous or intratendinous injection of the common flexor tendon origin.
4. *Desirable pathology* (demonstrative cases should be submitted for review, including draft reports; see Milestones Level 4, online supplemental appendix 2).
 - Distal biceps tendinopathy.
 - Triceps tendinopathy.
 - Elbow joint osteoarthritis.
 - Radial head or neck fracture.
 - Elbow joint effusion and/or synovitis.
 - Posterior interosseous nerve entrapment.
 - Lateral collateral ligament complex injury with or without instability.
 - Posterior impingement of the elbow.
 - Olecranon bursitis.
5. *Desirable procedures* (demonstrative cases should be submitted for review, including draft reports; see Milestones Level 4, online supplemental appendix 2).
 - Distal biceps peritendinous injection/bicipitoradial bursa injection.
 - Posterior interosseous nerve block/perineural injection.
 - Tenotomy with or without debridement elbow tendon.
6. *Optional pathology* (demonstrative cases should be submitted for review, including draft reports; see Milestones Level 5, online supplemental appendix 2).
 - Bicipitoradial bursitis.
 - Median nerve entrapment at the elbow.
 - Posterolateral rotary instability.
 - Olecranon fossa synovitis.
 - Posterolateral impingement (elbow synovial fold syndrome).
7. *Optional procedures* (demonstrative cases should be submitted for review, including draft reports; see Milestones Level 5, online supplemental appendix 2).
 - Ulnar nerve block/perineural injection.
 - Median nerve block/perineural injection.

UNIT 6: SPORTS ULTRASOUND OF THE WRIST

Didactic instructional sessions

1. Review scanning protocols and online live scanning demos.
2. Pathology lectures.
3. Procedures lectures.

Didactic practical hands-on instruction

1. Hands-on instruction in diagnostic scanning protocols and procedural technique
2. Supervised practice of diagnostic scanning protocols and procedural image acquisition.
 - Appropriate patient positioning
 - Transducer selection.
 - Ergonomics.
 - Technique.
3. As resources allow, it is recommended that ultrasound-guided procedures be practiced on an unembalmed cadaveric specimen. If this is not feasible, then fellows should practice all aspects of needle visualisation and tracking using other appropriate medium. The principles of the procedures listed below should be reviewed in a formal didactic setting.

Supplementary education and mentored clinical experience

1. *Independent complete regional examinations* (three separate normal scans should be submitted for review; see Milestones Level 2, online supplemental appendix 2).
2. *Essential pathology* (demonstrative cases should be submitted for review, including draft reports; see Milestones Level 3, online supplemental appendix 2).
 - Wrist joint effusion and/or synovitis.
 - Stenosing tenosynovitis of first dorsal compartment (De-Quervain's tenosynovitis).
 - Median neuropathy at the wrist (carpal tunnel syndrome).
 - First carpometacarpal joint osteoarthritis.
 - Dorsal or volar ganglion cyst.
3. *Essential procedures* (demonstrative cases should be submitted for review, including draft reports; see Milestones Level 3, online supplemental appendix 2).
 - Intra-articular wrist aspiration/injection
 - First carpometacarpal joint injection.
 - Wrist tendon sheath injection.
 - Carpal tunnel injection.
4. *Desirable pathology* (demonstrative cases should be submitted for review, including draft reports; see Milestones Level 4, online supplemental appendix 2).
 - Dorsal scapholunate ligament sprain with or without instability.
 - Extensor carpi ulnaris tendinopathy with or without instability.
 - Extensor tenosynovitis.
 - Flexor carpi radialis tendinopathy.
 - Flexor carpi ulnaris enthesopathy.
 - Scaphoid fracture.
 - Distal radius or ulna fracture.
5. *Desirable procedures* (demonstrative cases should be submitted for review, including draft reports; see Milestones Level 4, online supplemental appendix 2).
 - Ganglion cyst aspiration/injection.
6. *Optional pathology* (demonstrative cases should be submitted for review, including draft reports; see Milestones Level 5, online supplemental appendix 2).
 - Proximal and distal intersection syndromes.

- Fourth dorsal compartment retinacular impingement.
 - Metacarpal bossing.
 - Pisotriquetral osteoarthritis.
 - Ulnar nerve entrapment at Guyon's canal (eg, accessory abductor digiti minimi muscle).
 - Triangular fibrocartilage complex tear vii. Hook of the hamate fracture.
7. *Optional procedures* (demonstrative cases should be submitted for review, including draft reports; see Milestones Level 5, online supplemental appendix 2).
- Ulnar nerve injection at Guyon's canal.
 - Pisotriquetral or other wrist joint aspiration/injection.

UNIT 7: SPORTS ULTRASOUND OF THE HAND AND FINGER

Didactic instructional sessions

1. Review scanning protocols and online live scanning demos.
2. Pathology lectures.
3. Procedures lectures.

Didactic practical hands-on instruction

1. Hands-on instruction in diagnostic scanning protocols and procedural technique.
2. Supervised practice of diagnostic scanning protocols and procedural image acquisition.
 - Appropriate patient positioning.
 - Transducer selection.
 - Ergonomics.
 - Technique.
3. As resources allow, it is recommended that ultrasound-guided procedures be practiced on an unembalmed cadaveric specimen. If this is not feasible, then fellows should practice all aspects of needle visualisation and tracking using other appropriate medium. The principles of the procedures listed below should be reviewed in a formal didactic setting.

Supplementary education and mentored clinical experience

1. *Independent complete regional examinations* (three separate normal scans should be submitted for review; see Milestones Level 2, online supplemental appendix 2).
2. *Essential pathology* (demonstrative cases should be submitted for review, including draft reports; see Milestones Level 3, online supplemental appendix 2).
 - Metacarpal joint effusion and/or synovitis.
 - Flexor tendon stenosing tenosynovitis (trigger finger).
 - Ulnar collateral ligament sprain of the first metacarpophalangeal (MCP) joint with or without instability.
 - Metacarpal fracture.
3. *Essential procedures* (demonstrative cases should be submitted for review, including draft reports; see Milestones Level 3, online supplemental appendix 2).
 - Intra-articular finger joint aspiration/injection.
 - Flexor tendon sheath injection.
4. *Desirable pathology* (demonstrative cases should be submitted for review, including draft reports; see Milestones Level 4, online supplemental appendix 2).
 - Sagittal band injury with or without instability.
 - Central slip injury.
 - Terminal extensor tendon injury (Mallet finger).
 - Flexor digitorum profundus tendon tear (Jersey finger).
 - Phalanx dislocation.
 - Volar plate injury.
 - Proximal interphalangeal joint collateral ligament injury.

5. *Desirable procedures* (demonstrative cases should be submitted for review, including draft reports; see Milestones Level 4, online supplemental appendix 2).
 - Ganglion cyst aspiration/injection.
6. *Optional pathology* (demonstrative cases should be submitted for review, including draft reports; see Milestones Level 5, online supplemental appendix 2).
 - A2 and A4 pulley tears (rock climber's finger).
 - Second to fifth MCP joint collateral ligament injury.
7. *Optional procedures* (demonstrative cases should be submitted for review, including draft reports; see Milestones Level 5, online supplemental appendix 2).
 - Trigger finger release.

UNIT 8: SPORTS ULTRASOUND OF THE HIP AND PELVIS

Didactic instructional sessions

1. Review scanning protocols and online live scanning demos.
2. Pathology lectures.
3. Procedures lectures.

Didactic practical hands-on instruction

1. Hands-on instruction in diagnostic scanning protocols and procedural technique.
2. Supervised practice of diagnostic scanning protocols and procedural image acquisition.
 - Appropriate patient positioning.
 - Transducer selection.
 - Ergonomics.
 - Technique.
3. As resources allow, it is recommended that ultrasound-guided procedures be practiced on an unembalmed cadaveric specimen. If this is not feasible, then fellows should practice all aspects of needle visualisation and tracking using other appropriate medium. The principles of the procedures listed below should be reviewed in a formal didactic setting.

Supplementary education and mentored clinical experience

1. *Independent complete regional examinations* (three separate normal scans should be submitted for review; see Milestones Level 2, online supplemental appendix 2).
2. *Essential pathology* (demonstrative cases should be submitted for review, including draft reports; see Milestones Level 3, online supplemental appendix 2).
 - Adductor tendinopathy.
 - Hip joint effusion and/or synovitis.
 - Iliopsoas tendinopathy and/or bursitis with or without snapping.
 - Gluteus medius/minimus tendinopathy.
 - Greater trochanteric (subgluteus maximus) bursitis.
 - Proximal hamstring tendinopathy.
3. *Essential procedures* (demonstrative cases should be submitted for review, including draft reports; see Milestones Level 3, online supplemental appendix 2).
 - Intra-articular hip aspiration/injection.
 - Greater trochanteric bursa injection.
 - Proximal hamstring peritendinous or intratendinous injection.
4. *Desirable pathology* (demonstrative cases should be submitted for review, including draft reports; see Milestones Level 4, online supplemental appendix 2).
 - Distal rectus abdominis tendinopathy and/or aponeurosis tear.
 - Rectus femoris tendinopathy.

- Anterior acetabular labral tear.
- Osteitis pubis.
- Adductor longus muscle/tendon tear.
- Gluteus medius/minimus tendon tear.
- Morel-Lavallee lesion in hip region.
- Proximal hamstring tendon tear.
- Proximal iliotibial band origin enthesopathy.
- 5. *Desirable procedures* (demonstrative cases should be submitted for review, including draft reports; see Milestones Level 4, online supplemental appendix 2).
 - Iliopsoas bursa injection.
 - Gluteus medius or minimus peritendinous or intratendinous injection.
 - Adductor longus tendon origin peritendinous or intratendinous injection.
- 6. *Optional pathology* (demonstrative cases should be submitted for review, including draft reports; see Milestones Level 5, online supplemental appendix 2).
 - Hip impingement (eg, Cam lesion).
 - Sartorius tendinopathy.
 - Tensor fascia latae tendinopathy.
 - Neuropathy of lateral cutaneous nerve of the thigh.
 - Ischiofemoral impingement.
 - Transversalis fascia tear or insufficiency ('sports hernia').
 - Inguinal and/or femoral hernia.
- 7. *Optional procedures* (demonstrative cases should be submitted for review, including draft reports; see Milestones Level 5, online supplemental appendix 2).
 - Lateral cutaneous nerve of thigh block/perineural injection.
 - Tenotomy with or without debridement hip region tendon.

UNIT 9: SPORTS ULTRASOUND OF THE THIGH

Didactic instructional sessions

1. Review scanning protocols and online live scanning demos.
2. Pathology lectures.
3. Procedures lectures.

Didactic practical hands-on instruction

1. Hands-on instruction in diagnostic scanning protocols and procedural technique.
2. Supervised practice of diagnostic scanning protocols and procedural image acquisition.
 - Appropriate patient positioning.
 - Transducer selection.
 - Ergonomics.
 - Technique.
3. As resources allow, it is recommended that ultrasound-guided procedures be practiced on an unembalmed cadaveric specimen. If this is not feasible, then fellows should practice all aspects of needle visualisation and tracking using other appropriate medium. The principles of the procedures listed below should be reviewed in a formal didactic setting.

Supplementary education and mentored clinical experience

1. *Independent complete regional examinations* (three separate normal scans should be submitted for review; see Milestones Level 2, online supplemental appendix 2).
2. *Essential pathology* (demonstrative cases should be submitted for review, including draft reports; see Milestones Level 3, online supplemental appendix 2).
 - Hamstring muscle tear.

- Quadriceps muscle tear.
- Quadriceps contusion.
- 3. *Essential procedures* (demonstrative cases should be submitted for review, including draft reports; see Milestones Level 3, online supplemental appendix 2).
- 4. Aspiration/injection of fluid collection (ie, haematoma, Morel-Lavallee).
- 5. *Desirable pathology* (demonstrative cases should be submitted for review, including draft reports; see Milestones Level 4, online supplemental appendix 2).
 - Heterotopic ossification in thigh musculature.
 - Morel-Lavallee lesion in thigh region.
 - Grading severity of hamstring and quadriceps muscle injury.
- 6. *Desirable procedures* (demonstrative cases should be submitted for review, including draft reports; see Milestones Level 4, online supplemental appendix 2).
 - Sclerosis of Morel-Lavallee lesion.
- 7. *Optional pathology* (demonstrative cases should be submitted for review, including draft reports; see Milestones Level 5, online supplemental appendix 2).
 - Sciatic nerve entrapment associated with prior hamstring muscle/tendon injury.
 - Other neuropathy (eg, anterior cutaneous nerve of thigh, posterior cutaneous nerve of thigh, obturator, saphenous).
- 8. *Optional procedures* (demonstrative cases should be submitted for review, including draft reports; see Milestones Level 5, online supplemental appendix 2).
 - Sciatic nerve block/perineural injection.
 - Saphenous nerve block/perineural injection in Adductor canal.

UNIT 10: SPORTS ULTRASOUND OF THE KNEE

Didactic instructional sessions

1. Review scanning protocols and online live scanning demos.
2. Pathology lectures.
3. Procedures lectures.

Didactic practical hands-on instruction

1. Hands-on instruction in diagnostic scanning protocols and procedural technique.
2. Supervised practice of diagnostic scanning protocols and procedural image acquisition.
 - Appropriate patient positioning.
 - Transducer selection.
 - Ergonomics.
 - Technique.
3. As resources allow, it is recommended that ultrasound-guided procedures be practiced on an unembalmed cadaveric specimen. If this is not feasible, then fellows should practice all aspects of needle visualisation and tracking using other appropriate medium. The principles of the procedures listed below should be reviewed in a formal didactic setting.

Supplementary education and mentored clinical experience

1. *Independent complete regional examinations* (three separate normal scans should be submitted for review; see Milestones Level 2, online supplemental appendix 2).
2. *Essential pathology* (demonstrative cases should be submitted for review, including draft reports; see Milestones Level 3, online supplemental appendix 2).
 - Knee joint effusion and/or synovitis.

- Knee osteoarthritis (medial and lateral compartment, femoral trochlear sulcus).
 - Extensor mechanism tendinopathy (quadriceps and patellar).
 - Prepatellar bursitis.
 - Iliotibial band tendinopathy and bursitis with or without snapping.
 - Baker's cyst.
 - Medial (tibial) collateral ligament sprain with or without instability.
3. *Essential procedures* (demonstrative cases should be submitted for review, including draft reports; see Milestones Level 3, online supplemental appendix 2).
 - Intra-articular knee aspiration/injection.
 - Iliotibial band/bursa (distal) injection.
 - Baker's cyst aspiration.
 4. *Desirable pathology* (demonstrative cases should be submitted for review, including draft reports; see Milestones Level 4, online supplemental appendix 2).
 - Deep and superficial infrapatellar bursitis.
 - Osgood-Schlatter's disease.
 - Lateral (fibular) collateral ligament sprain with or without instability.
 - Meniscal tear, parameniscal cysts and/or meniscal extrusion with dynamic assessment.
 - Pes anserine tendinopathy and/or bursitis.
 5. *Desirable procedures* (demonstrative cases should be submitted for review, including draft reports; see Milestones Level 4, online supplemental appendix 2).
 - Knee tendon peritendinous or intratendinous injection.
 - Pes anserine bursa injection.
 6. *Optional pathology* (demonstrative cases should be submitted for review, including draft reports; see Milestones Level 5, online supplemental appendix 2).
 - Distal biceps femoris tendinopathy.
 - Semimembranosus tendinopathy.
 - Popliteus tendinopathy.
 - Proximal tibiofemoral joint osteoarthritis, ganglion and/or instability.
 - Posterior cruciate ligament tear.
 - Common fibular neuropathy.
 - Cruciate ligament ganglion cysts.
 - Popliteal artery entrapment syndrome.
 - Medial collateral ligament bursitis.
 - Differentiating sprains/pathology of the superficial and deep (meniscotibial and meniscofemoral) fibres of the medial collateral ligament.
 - Medial patellofemoral ligament sprain with or without instability.
 - Saphenous neuropathy (entrapment at the sartorius and gracilis tendons or of the infrapatellar branches).
 - Hoffa's fat pad impingement.
 7. *Optional procedures* (demonstrative cases should be submitted for review, including draft reports; see Milestones Level 5, online supplemental appendix 2).
 - Common fibular nerve block/perineural injection
 - Genicular nerve block/perineural injection
 - Tendon scraping of patellar tendon
 - Tenotomy with or without debridement for knee tendon.

2. Pathology lectures.
3. Procedures lectures.

Didactic practical hands-on instruction

1. Hands-on instruction in diagnostic scanning protocols and procedural technique.
2. Supervised practice of diagnostic scanning protocols and procedural image acquisition.
 - Appropriate patient positioning.
 - Transducer selection.
 - Ergonomics.
 - Technique.
3. As resources allow, it is recommended that ultrasound-guided procedures be practiced on an unembalmed cadaveric specimen. If this is not feasible, then fellows should practice all aspects of needle visualisation and tracking using other appropriate medium. The principles of the procedures listed below should be reviewed in a formal didactic setting.

Supplementary education and mentored clinical experience

1. *Independent complete regional examinations* (three separate normal scans should be submitted for review; see Milestones Level 2, online supplemental appendix 2).
2. *Essential pathology* (demonstrative cases should be submitted for review, including draft reports; see Milestones Level 3, online supplemental appendix 2).
 - Midportion Achilles tendinopathy.
 - Insertional Achilles tendinopathy.
 - Ankle joint effusion and/or synovitis.
 - Anterior talofibular ligament sprain with or without instability.
 - Anterior-inferior tibiofibular ligament sprain with or without instability.
 - Fibularis longus and brevis tendinopathy with or without instability and/or intrasheath subluxation.
 - Posterior tibialis tendinopathy.
 - Medial gastrocnemius muscle injury.
3. *Essential procedures* (demonstrative cases should be submitted for review, including draft reports; see Milestones Level 3, online supplemental appendix 2).
 - Intra-articular tibiotalar joint aspiration/injection.
 - Ankle tendon peritendinous or intratendinous injection.
4. *Desirable pathology* (demonstrative cases should be submitted for review, including draft reports; see Milestones Level 4, online supplemental appendix 2).
 - Anterior tibialis tendinopathy.
 - Anterior ankle impingement.
 - Calcaneofibular ligament sprain with or without instability.
 - Retrocalcaneal and retro-Achilles/Superficial/Subcutaneous bursitis.
 - Flexor hallucis longus tendinopathy.
 - Deltoid ligament sprain with or without instability.
 - Spring ligament sprain with or without instability.
 - Fibular fracture (stress fracture or acute fracture).
 - Tibial stress fracture.
 - Gastrocnemius or soleus injury (other than medial gastrocnemius).
5. *Desirable procedures* (demonstrative cases should be submitted for review, including draft reports; see Milestones Level 4, online supplemental appendix 2).
 - Subtalar joint aspiration/injection.

UNIT 11: SPORTS ULTRASOUND OF THE LEG AND ANKLE

Didactic instructional sessions

1. Review scanning protocols and online live scanning demos.

6. *Optional pathology* (demonstrative cases should be submitted for review, including draft reports; see Milestones Level 5, online supplemental appendix 2).
 - Talar dome articular cartilage pathology.
 - Superficial fibular nerve entrapment.
 - Subtalar joint effusion and/or synovitis and/or osteoarthritis.
 - Sural neuropathy.
 - Fibularis quartus identification.
 - Plantaris tendinopathy.
 - Tarsal tunnel syndrome (including tibial, medial plantar, lateral plantar, medial calcaneal and inferior calcaneal (Baxter's) nerve entrapment).
 - Deep fibular neuropathy.
 - Posterior impingement.
 - Anterior process of the calcaneus fracture.
 - Talocalcaneal and calcaneonavicular coalitions.
 - Bifurcate ligament injury.
7. *Optional procedures* (demonstrative cases should be submitted for review, including draft reports; see Milestones Level 5, online supplemental appendix 2).
 - Tibial nerve block/perineural injection.
 - Brisement of Achilles or another ankle tendon.
 - Tendon scraping of Achilles tendon.
 - Tenotomy with or without debridement ankle tendon.
 - Fasciotomy for chronic exertional compartment syndrome.
3. *Essential procedures* (demonstrative cases should be submitted for review, including draft reports; see Milestones Level 3, online supplemental appendix 2).
 - Periplantar or intraplantar fascia injection.
 - First metatarsophalangeal joint aspiration/injection.
4. *Desirable pathology* (demonstrative cases of each diagnosis should be submitted for review, including draft reports; see Milestones Level 4, online supplemental appendix 2).
 - Metatarsal fracture.
 - Plantar fibromatosis.
 - Morton's neuroma and/or intermetatarsal bursitis.
 - Plantar plate disorders.
 - Submetatarsal bursitis.
 - Metatarsophalangeal joint urate deposition disease.
5. *Desirable procedures* (demonstrative cases should be submitted for review, including draft reports; see Milestones Level 4, online supplemental appendix 2).
 - Midfoot joint aspiration/injection.
 - Other toe joint aspiration/injection.
 - Morton's neuroma/intermetatarsal bursa injection.
6. *Optional pathology* (demonstrative cases should be submitted for review, including draft reports; see Milestones Level 5, online supplemental appendix 2).
 - Calcaneal stress fracture.
 - Inferior calcaneal (Baxter's) neuropathy including evaluation of abductor digiti minimi muscle fatty infiltration and/or atrophy.
 - Tendinopathy at the Knot of Henry.
 - Medial plantar neuropathy at the Knot of Henry.
 - Deep fibular neuropathy.
 - Neuropathy of medial plantar proper digital nerve (Joplin's neuroma).
 - Great sesamoid disorders.
7. *Optional procedures* (demonstrative cases should be submitted for review, including draft reports; see Milestones Level 5, online supplemental appendix 2).
 - Fasciotomy with or without debridement of the plantar fascia.
 - Medial and/or lateral plantar nerve perineural injection.
 - Inferior calcaneal (Baxter's) nerve perineural injection.
 - Other perineural injection (eg, medial calcaneal, dorsal cutaneous branches, deep fibular, medial plantar proper digital).

UNIT 12: SPORTS ULTRASOUND OF THE FOOT

Didactic instructional sessions

1. Review scanning protocols and online live scanning demos.
2. Pathology lectures.
3. Procedures lectures.

Didactic practical hands-on instruction

1. Hands-on instruction in diagnostic scanning protocols and procedural technique.
2. Supervised practice of diagnostic scanning protocols and procedural image acquisition.
 - Appropriate patient positioning.
 - Transducer selection.
 - Ergonomics.
 - Technique.
3. As resources allow, it is recommended that ultrasound-guided procedures be practiced on an unembalmed cadaveric specimen. If this is not feasible, then fellows should practice all aspects of needle visualisation and tracking using other appropriate medium. The principles of the procedures listed below should be reviewed in a formal didactic setting.

Supplementary education and mentored clinical experience

1. *Independent complete regional examinations* (three separate normal scans should be submitted for review; see Milestones Level 2, online supplemental appendix 2).
2. *Essential pathology* (demonstrative cases should be submitted for review, including draft reports; see Milestones Level 3, online supplemental appendix 2).
 - Plantar fasciopathy.
 - Lisfranc ligament sprain with or without instability.
 - Metatarsophalangeal joint effusion and/or synovitis.
 - Midfoot joint(s) osteoarthritis.

CHALLENGES AND OPPORTUNITIES

We acknowledge that successful implementation and completion of this curriculum may present challenges. Our working group has extensive experience in Sports US clinical application and teaching, and this is reflected in the comprehensive nature of this curriculum. The AMSSM has placed significant emphasis on developing Sports US training, and we believe this expanded curriculum will provide a solid foundation for all sports medicine physicians while also guiding those interested to achieve an expert level.

As previously mentioned, advanced expertise may be difficult to achieve within the current 1-year fellowship structure. Ongoing skill development and progression through the optional components of the curriculum will likely occur over several years, and our intent is not that fellows complete the curriculum in its entirety during their 1-year clinical fellowship. We also acknowledge that some fellowship programmes may not have the optimal resources in place including qualified faculty mentors and available equipment. Nonetheless,

Sports US training has been an ACGME requirement since 2017 and multiple resources have been developed by AMSSM that are freely available to assist programmes in implementing the curriculum.

While this curriculum was specifically written in the context of American sports medicine fellowship training, there is applicability to the international sports and exercise medicine community. Our structured progression can be implemented by any physician interested in using Sports US in the care of their athletes and patients. Given the differences in infrastructure and training, this curriculum may need to be altered to fit the needs of the global sports and exercise medicine community. This presents an exciting opportunity for growth of Sports US worldwide.

RECORD KEEPING AND COMPETENCY

The fellow should maintain detailed records of all Sports US educational activities in which they participate throughout fellowship. The fellow should also maintain a procedure log of all diagnostic and interventional Sports US procedures, including their role in the procedure (eg, observation, performance, interpretation and/or reporting). Detailed record keeping serves these multiple purposes: (1) assists with credentialing, (2) assists in practice accreditation and (3) supports application for certification examinations.

Although maintaining records of the type and number of diagnostic and interventional ultrasound procedures is important, performing a specific number of ultrasound procedures does not necessarily determine competence. A milestone system has been accepted by the ACGME as a more appropriate way of determining competence. The progression of this curriculum was designed to follow the milestone system and sample milestones are provided in the online supplemental appendix 2. While these milestones provide structure and targets for fellows, they should not be considered requirements for graduation. Determination of readiness for graduation remains with the fellowship programme director. Furthermore, given the natural variance in patient population and presentation of certain conditions, it is not expected that all fellows must document every listed pathology and procedure within a certain milestone to demonstrate competence.

Finally, it is recommended that each Fellowship programme develop an objective written and/or practical test to assist in assessing the sports medicine fellow's Sports US knowledge and skill. A sample OSCE is provided in the online supplemental appendix 3.

Author affiliations

- ¹Orthopedics and Rehabilitation, The University of Iowa Roy J and Lucille A Carver College of Medicine, Iowa City, Iowa, USA
- ²Pediatrics, Orthopedics and Rehabilitation, University of Wisconsin-Madison, Madison, Wisconsin, USA
- ³Physical Medicine and Rehabilitation, Mayo Clinic, Rochester, Minnesota, USA
- ⁴United States Olympic and Paralympic Committee, Colorado Springs, Colorado, USA
- ⁵Orthopedics and Radiology, Essentia Health, Duluth, Minnesota, USA
- ⁶Rothman Orthopaedic Institute, New York, New York, USA
- ⁷Orthopedics and Rehabilitation Medicine, Emory University, Atlanta, Georgia, USA
- ⁸Family Medicine, University of Washington, Seattle, Washington, USA
- ⁹Emergency Medicine, University of California Davis, Davis, California, USA
- ¹⁰Emergency Medicine, The University of Arizona College of Medicine Tucson, Tucson, Arizona, USA

Twitter Melody Hrubes @MelodyHrubesMD and Ashwin Rao @badash13

Contributors All authors were involved in the conception of the work, acquisition and interpretation of data, drafting and revising of the work and final approval of the submitted version.

Funding The authors have not declared a specific grant for this research from any funding agency in the public, commercial or not-for-profit sectors.

Competing interests MMH reports personal fees from Tenex Health, personal fees from Sonex Health, other from UpToDate, Inc, outside the submitted work. JTF reports other from DEMOS Publishing, other from up to date, personal fees from COVR Medical, personal fees from Sanofi, personal fees from Aim Specialty Health, outside the submitted work. KM reports personal fees from McGraw Hill, personal fees from Elsevier, other from Tenex, outside the submitted work. JS reports other from Sonex Health, other from Tenex Health, outside the submitted work.

Patient consent for publication Not required.

Provenance and peer review Not commissioned; externally peer reviewed.

Supplemental material This content has been supplied by the author(s). It has not been vetted by BMJ Publishing Group Limited (BMJ) and may not have been peer-reviewed. Any opinions or recommendations discussed are solely those of the author(s) and are not endorsed by BMJ. BMJ disclaims all liability and responsibility arising from any reliance placed on the content. Where the content includes any translated material, BMJ does not warrant the accuracy and reliability of the translations (including but not limited to local regulations, clinical guidelines, terminology, drug names and drug dosages), and is not responsible for any error and/or omissions arising from translation and adaptation or otherwise.

ORCID iD

Mederic M Hall <http://orcid.org/0000-0001-6186-1865>

REFERENCES

- 1 Finnoff J, Lavalley ME, Smith J. Musculoskeletal ultrasound education for sports medicine fellows: a suggested/potential curriculum by the American medical Society for sports medicine. *Br J Sports Med* 2010;44:1144–8.
- 2 Finnoff JT, Berkoff D, Brennan F. American medical Society for sports medicine recommended sports ultrasound curriculum for sports medicine fellowships. *Br J Sports Med* 2015;49:145–50.
- 3 Hahn M, Ray J, Hall MM, et al. Ultrasound in trauma and other acute conditions in sports, part I. *Curr Sports Med Rep* 2020;19:486–94.
- 4 Ray JW, Gende AM, Hall MM, et al. Ultrasound in trauma and other acute conditions in sports, part II. *Curr Sports Med Rep* 2020;19:546–51.

Appendix 1 - AMSSM Recommended Sports Ultrasound Scanning Protocols

These scanning protocols were developed as educational/instructional tools to assist with familiarization of regional anatomy relevant to the practice of sports medicine. These protocols are not meant to be prescriptive for clinical practice. We recommend each institution develop their own clinical scanning protocols taking into consideration requirements for coding and billing and practice-specific factors.

Sports Medicine Fellows should strive to become competent in the scanning techniques and normal anatomy listed below. Recognition and reporting of pathologic findings are addressed in the AMSSM Revised Sports Ultrasound Curriculum for Sports Medicine Fellowships.

ACUTE TRAUMA

Required

1. Common sites of fracture (should also be reviewed in each of the following musculoskeletal section)
 - a. Rib
 - b. Clavicle
 - c. Distal radius/ulna
 - d. Scaphoid
 - e. Metacarpal
 - f. Fibula
 - g. Metatarsal
2. Common sites of dislocation (should also be reviewed in each MSK section below)
 - a. Glenohumeral joint
 - b. Phalanx
3. eFAST (extended Focused Assessment of Sonography in Trauma)

Optional

1. Ocular trauma assessment
2. RUSH (Rapid Ultrasound in Hypotension)
3. Superficial and deep venous thrombosis
4. Pulmonary assessment
5. Limited cardiac assessment for evaluation of pericardial effusion and global systolic function

SHOULDER (to include neck, chest, and upper arm as indicated)

Required

1. Biceps tendon (long head) and muscle
2. Subscapularis tendon
3. Dynamic assessment of biceps subluxation/dislocation & subcoracoid impingement as indicated

Revised 2021

4. Acromioclavicular joint
5. Infraspinatus tendon and muscle
6. Teres minor tendon and muscle
7. Posterior glenohumeral joint
8. Spinoglenoid notch (suprascapular nerve and vessels)
9. Supraspinatus tendon and muscle
10. Subacromial-subdeltoid bursa
11. Coracoacromial ligament
12. Dynamic rotator cuff assessment and impingement testing

Optional (based on clinical question)

1. Pectoralis major tendon and muscle
2. Rotator Interval (including the coracohumeral ligament and superior glenohumeral ligament)
3. Clavicle
4. Sternoclavicular joint
5. Subscapularis muscle
6. Suprascapular notch (suprascapular nerve and vessels)
7. Quadrilateral space (Axillary nerve)
8. Radial nerve
9. Humerus
10. Brachial Plexus

ELBOW

Anterior elbow

Required

1. Brachialis muscle and tendon
2. Brachial artery and vein
3. Median nerve
4. Pronator teres muscle and tendon
5. Radial nerve (trace to bifurcation as indicated)
6. Brachioradialis muscle
7. Anterior humeroradial joint and recesses
8. Anterior humeroulnar joint and recesses
9. Biceps tendon and muscle

Optional (based on clinical question)

1. Bicipitoradial bursa
2. Lateral cutaneous nerve of the forearm

Revised 2021

Medial Elbow*Required*

1. Common flexor/pronator tendon and muscles
2. Ulnar collateral ligament including dynamic valgus stress views as indicated
3. Humero-ulnar joint
4. Ulnar nerve including assessment of instability with flexion/extension views

Optional (based on clinical question)

1. Dynamic assessment of posteromedial impingement and snapping triceps
2. Medial cutaneous nerve of the forearm

Lateral Elbow*Required*

1. Common extensor tendon and muscles
2. Radial collateral ligament
3. Lateral humero-radial joint
4. Radial nerve from mid-arm to the bifurcation
5. Posterior interosseous nerve through supinator muscle
6. Brachioradialis
7. Extensor carpi radialis longus

Optional (based on clinical question)

1. Superficial radial nerve through forearm
2. Posterior cutaneous nerve of the forearm
3. Lateral ulnar collateral ligament
4. Annular ligament
5. Dynamic stress views of the lateral collateral ligament complex
6. Posterolateral synovial fold with dynamic assessment of impingement

Posterior Elbow*Required*

1. Triceps tendon and muscles
2. Olecranon fossa and posterior joint recess
3. Olecranon process
4. Olecranon bursa
5. Ulnar nerve including assessment of instability with flexion/extension views

Optional (based on clinical question)

1. Dynamic assessment of posteromedial impingement
2. Dynamic assessment of snapping triceps

Revised 2021

WRIST

Volar Wrist

Required

1. Carpal tunnel including dynamic evaluation of tendon and nerve motion
2. Flexor retinaculum/Transverse carpal ligament
3. Median nerve
4. Flexor pollicis longus tendon
5. Flexor digitorum profundus and superficialis tendons
6. Palmaris longus tendon
7. Flexor carpi radialis longus tendon
8. Radial artery
9. Joints (e.g. volar radiocarpal joint) including assessment of volar ganglion cyst
10. Ulnar nerve within Guyon's canal
11. Ulnar artery
12. Flexor carpi ulnaris tendon

Optional (based on clinical question)

1. Palmar cutaneous branch of median nerve
2. Thenar motor branch/Recurrent motor branch of median nerve
3. Superficial palmar arterial arch
4. Scaphoid (assessment for fracture)
5. Hook of hamate (assessment for fracture)
6. Triangular fibrocartilage complex (meniscus homologue and triangular fibrocartilage)
7. Pisotriquetral joint
8. Dorsal ulnar cutaneous nerve

Dorsal Wrist

Required

1. Extensor tendons and muscles (6 dorsal compartments)
2. Extensor retinaculum
3. Dorsal scapholunate ligament including dynamic stress views as indicated
4. Joints as clinically indicated (radiocarpal, ulnocarpal, midcarpal, carpometacarpal) including evaluation of dorsal synovial recesses and assessment of dorsal ganglion cyst
5. Superficial radial nerve

Optional (based on clinical question)

1. Dynamic assessment of intersection syndrome at compartment 1-2 and 2-3
2. Dynamic assessment of extensor retinacular impingement
3. First dorsal compartment evaluation for presence of retinaculum (septum) and relation of neurovascular structures (superficial radial nerve branches, cephalic vein, radial artery)
4. Extensor carpi ulnaris subsheath including dynamic assessment of instability
5. Triangular fibrocartilage complex (meniscus homologue and triangular fibrocartilage)

Revised 2021

6. Dorsal ulnar cutaneous nerve

HAND AND FINGER

Required

1. Metacarpophalangeal and interphalangeal joints
2. Volar plates
3. Collateral ligaments
4. Flexor tendons and sheath
5. A1 and A2 pulleys
6. Extensor tendons
7. Ulnar collateral ligament of thumb MCP joint including dynamic stress views as indicated

Optional (based on clinical question)

1. Metacarpals and phalanges for fracture assessment
2. Other pulleys as indicated
3. Sagittal band injury with dynamic assessment of instability as indicated

HIP AND PELVIS

Anterior Hip

Required

1. Femoral head, neck, capsule, and anterior synovial recess
2. Hip joint assessment for effusion
3. Anterior labrum
4. Femoral vessels and nerve
5. Iliopsoas muscle, tendon and bursa
6. Sartorius and tensor fascia latae tendons and muscles
7. Rectus femoris tendon(s) and muscles
8. Dynamic scanning for snapping hip as indicated

Optional (based on clinical question)

1. Dynamic assessment of hip impingement
2. Assessment of inguinal and femoral hernia
3. Lateral cutaneous nerve of the thigh
4. Dynamic assessment for transversalis fascia tear or insufficiency ("sports hernia")

Medial Hip

Required

1. Adductor muscles (Adductor longus/brevis/magnus and gracilis) and tendons

Revised 2021

2. Pubic bone and symphysis including dynamic assessment as indicated
3. Pectineus muscle
4. Distal rectus abdominis muscle and tendon
5. Rectus abdominis-adductor longus aponeurosis
6. Obturator nerve (including anterior and posterior branches)

Optional (based on clinical question)

1. Assessment of inguinal and femoral hernia
2. Dynamic assessment for transversalis fascia tear or insufficiency ("sports hernia")

Lateral Hip

Required

1. Greater trochanter of femur (including identification of anterior, lateral, posterior, and superoposterior facets)
2. Gluteus minimus tendon and muscle
3. Gluteus medius tendon and muscle (anterior and posterior bands)
4. Greater trochanteric (subgluteus maximus) bursa
5. Superficial arch at greater trochanter (Gluteus maximus muscle – iliotibial band – tensor fasciae latae muscle)
6. Dynamic scanning for snapping hip as indicated

Optional (based on clinical question)

1. Proximal iliotibial band origin at iliac crest

Posterior Hip

Required

1. Gluteus maximus muscle and insertion onto iliotibial band
2. Piriformis muscle and tendon
3. Quadratus femoris muscle
4. Proximal hamstring tendon complex (conjoint tendon and semimembranosus)
5. Proximal biceps femoris, semimembranosus, and semitendinosus muscles
6. Ischial tuberosity and bursal region
7. Sciatic nerve
8. Posterior hip joint

Optional (based on clinical question)

1. Dynamic assessment of ischiofemoral impingement
2. Posterior cutaneous nerve of the thigh

Revised 2021

THIGH

Anterior Thigh

Required

1. Rectus femoris muscle and tendons
2. Vastus medialis/lateralis/intermedius muscles and tendons
3. Sartorius muscle and tendon
4. Femoral nerve
5. Femur

Optional (based on clinical question)

1. Anterior cutaneous nerve of the thigh
2. Lateral cutaneous nerve of the thigh

Medial Thigh

Required

1. Adductor longus/brevis/magnus muscles and tendons
2. Gracilis muscle and tendon
3. Sartorius muscle and tendon
4. Femoral nerve
5. Obturator nerve
6. Femur

Optional (based on clinical question)

1. Saphenous nerve

Posterior Thigh

Required

1. Biceps femoris muscle and tendon
2. Semitendinosus muscle and tendon
3. Semimembranosus muscle and tendon
4. Adductor magnus muscle and tendon
5. Sciatic nerve
6. Femur

Optional (based on clinical question)

1. Posterior cutaneous nerve of the thigh

Revised 2021

KNEE

Anterior Knee

Required

1. Distal quadriceps muscles
2. Quadriceps tendon
3. Suprapatellar recess of knee joint
4. Patella and prepatellar bursa
5. Patellar tendon and tibial tubercle
6. Hoffa's fat pad
7. Superficial infrapatellar bursa
8. Deep infrapatellar bursa
9. Vastus medialis and medial retinaculum including the medial patellofemoral ligament and dynamic assessment of stability as indicated
10. Vastus lateralis and lateral retinaculum
11. Trochlear cartilage
12. Anterior horns of medial and lateral menisci

Optional (based on clinical question)

1. Infrapatellar branches of saphenous nerve

Medial Knee

Required

1. Medial (tibial) collateral ligament (superficial and deep portions) with valgus stress testing as indicated
2. Medial meniscus anterior and posterior horns
3. Tibiofemoral joint space
4. Pes anserine tendons and bursa
5. Medial patellar retinaculum and medial patellofemoral ligament
6. Medial patellofemoral joint

Optional (based on clinical question)

1. Saphenous nerve
2. Insertion of semimembranosus tendon

Lateral Knee

Required

1. Iliotibial band
2. Lateral synovial recess of the knee
3. Lateral meniscus anterior and posterior horns
4. Tibiofemoral joint space
5. Lateral (fibular) collateral ligament with varus stress testing as indicated

Revised 2021

6. Biceps femoris tendon and muscles
7. Popliteus tendon and muscle
8. Lateral patellar retinaculum
9. Lateral patellofemoral joint
10. Proximal tibiofibular joint including assessment of instability as indicated
11. Common fibular nerve at fibular tunnel

Optional (based on clinical question)

1. Division of common fibular nerve into superficial and deep branches

Posterior Knee

Required

1. Popliteal artery and vein
2. Semimembranosus, semitendinosus, and biceps femoris (long and short heads) muscles and tendons
3. Medial & lateral gastrocnemius muscles and tendons
4. Evaluation for Baker's cyst at interval between semimembranosus and medial gastrocnemius
5. Sciatic, tibial, and common fibular nerves
6. Posterior horns of medial and lateral menisci
7. Posterior tibiofemoral joint
8. Posterior cruciate ligament
9. Popliteus muscle

Optional (based on clinical question)

1. Dynamic assessment of popliteal artery entrapment syndrome

LEG AND ANKLE

Anterior Leg and Ankle

Required

1. Anterior leg compartment muscles and tendons (tibialis anterior, extensor digitorum longus, extensor hallucis longus, peroneus tertius)
2. Anterior tibiotalar joint
3. Talar dome cartilage
4. Sinus tarsi
5. Anterior inferior tibiofibular ligament including dynamic assessment as indicated
6. Superficial fibular nerve at exit from crural fascia through division into medial and intermediate dorsal cutaneous nerves
7. Deep fibular nerve
8. Distal anterior tibial artery and dorsalis pedis artery

Optional (based on clinical question)

Revised 2021

1. Dynamic assessment of anterior impingement
2. Extensor retinaculum (superior and inferior)

Medial Leg and Ankle

Required

1. Medial gastrocnemius muscle
2. Soleus muscle
3. Flexor retinaculum
4. Deep posterior compartment muscles (tibialis posterior, flexor digitorum longus, and flexor hallucis longus)
5. Deltoid ligament
6. Medial tibiotalar joint
7. Medial aspect of posterior subtalar joint
8. Tarsal tunnel (tibial, medial plantar, and lateral plantar nerves)
9. Posterior tibial artery and veins

Optional (based on clinical question)

1. Spring ligament
2. Saphenous nerve
3. Medial calcaneal nerve
4. Inferior calcaneal (Baxter's) nerve
5. Tibia for stress fracture
6. Dynamic assessment for posteromedial impingement

Lateral Leg and Ankle

Required

1. Fibularis longus and brevis muscles and tendons
2. Superior fibular retinaculum
3. Dynamic assessment for fibular subluxation/dislocation as indicated
4. Fibular trochlea (peroneal tubercle)
5. Fibula for acute traumatic or stress fracture
6. Anterior talofibular ligament including dynamic stress views as indicated
7. Calcaneofibular ligament including dynamic stress views as indicated
8. Anterior tibiofibular ligament including dynamic stress views as indicated
9. Lateral recess of tibiotalar joint including dynamic assessment of impingement as indicated
10. Lateral recess of posterior subtalar joint
11. Sinus tarsi
12. Sural nerve and lateral calcaneal nerve

Optional (based on clinical question)

1. Anterior process of calcaneus
2. Lateral process of talus
3. Bifurcate ligament

Revised 2021

4. Dynamic evaluation for subfibular impingement as indicated

Posterior Leg and Ankle

Required

1. Medial and lateral gastrocnemius muscles
2. Soleus muscle
3. Achilles tendon and paratenon
4. Retrocalcaneal bursa
5. Retro-Achilles/Superficial/Subcutaneous bursa
6. Plantaris tendon
7. Posterior tibiotalar joint
8. Posterior subtalar joint

Optional (based on clinical question)

1. Posterior process of talus including identification of os trigonum if present
2. Dynamic assessment for posterior impingement
3. Deep posterior compartment leg musculature (posterior tibialis, flexor digitorum longus, flexor hallucis longus)

FOOT

Hindfoot

Required

1. Plantar fascia (central and lateral cords)
2. Plantar fat pad including dynamic assessment of compression
3. Tarsal tunnel (tibial, medial plantar, and lateral plantar nerves)
4. Sural nerve and lateral calcaneal nerve
5. Achilles tendon and paratenon
6. Plantaris tendon
7. Retro-Achilles/Superficial Achilles/Subcutaneous bursa

Optional (based on clinical question)

1. Medial calcaneal nerve
2. Inferior calcaneal (Baxter's) nerve
3. Abductor digiti minimi muscle assessment for fatty infiltration and/or atrophy (associated with inferior calcaneal (Baxter's) neuropathy)
4. Dynamic assessment for posterior impingement
5. Calcaneal stress fracture

Midfoot

Required

Revised 2021

1. Talonavicular joint
2. Calcaneocuboid joint
3. Tarsometatarsal joints
4. Dorsal Lisfranc ligament including dynamic assessment of stability
5. Deep fibular nerve
6. Anterior tibialis tendon insertion
7. Posterior tibialis tendon insertion
8. Spring ligament
9. Flexor digitorum longus and flexor hallucis longus at the Knot of Henry
10. Medial plantar nerve
11. Plantar fascia lateral cord insertion at 5th metatarsal base
12. Fibularis brevis insertion at 5th metatarsal base

Optional (based on clinical question)

1. Medial, intermediate, and lateral dorsal cutaneous nerves
2. Fibularis longus tendon insertion
3. Identification of tarsal coalition

Forefoot

Required

1. Metatarsophalangeal and interphalangeal joints
2. Metatarsals and phalanges for acute traumatic or stress fracture as indicated
3. Metatarsal interspace evaluation for Morton's neuroma and intermetatarsal bursitis
4. Plantar plate including dynamic assessment as indicated
5. Flexor tendons
6. Great toe sesamoids including dynamic assessment as indicated

Optional (based on clinical question)

1. Extensor tendon insertions
2. Medial plantar proper digital nerve (plantar medial hallucal nerve)

Revised 2021

Appendix 2 – Suggested Sports Ultrasound Milestones

Acute Trauma				
Level 1	Level 2	Level 3	Level 4	Level 5
<p>Verbally describes the rationale for a diagnostic US assessment of an acutely injured athlete</p> <p>Verbally lists indications for repeat US examinations or complimentary advanced imaging</p>	<p>Correctly acquires, labels, and saves images of all required protocols</p> <p>Demonstrates appropriate patient positioning and physician ergonomics for <i>essential pathology</i> and protocols</p> <p>Verbally describes all <i>essential pathology</i></p>	<p>Correctly identifies and labels <i>essential pathology</i> and generates an appropriate diagnostic report</p> <p>Performs <i>essential protocols</i>, including appropriate image labeling, and generates an appropriate report</p>	<p>Correctly identifies and labels <i>desirable pathology</i> and generates an appropriate diagnostic report</p> <p>Performs <i>desirable protocols</i>, including appropriate image labeling, and generates an appropriate report</p> <p>Integrates current research and literature with guidelines to recommend management or guidelines relevant to the protocol</p>	<p>Consistently and independently performs and teaches the skills outlined in previous levels</p> <p>Correctly identifies and labels <i>optional pathology</i> and generates an appropriate diagnostic report</p> <p>Performs <i>optional protocols</i>, including appropriate image labeling, and generates an appropriate report</p> <p>Publishes peer-reviewed work related to sports ultrasound evaluation of trauma and other acute conditions</p>
<input type="checkbox"/>	<input type="checkbox"/>	<input type="checkbox"/>	<input type="checkbox"/>	<input type="checkbox"/>
Comments:				Not yet achieved Level 1

Shoulder (including neck, chest, and upper arm)				
Level 1	Level 2	Level 3	Level 4	Level 5
<p>Verbally describes the indications for a diagnostic US of the shoulder and lists the structures needed to be imaged during a complete examination</p> <p>Verbally describes the indications, contra-indications, risks and benefits of US-guided shoulder injections</p>	<p>Correctly acquires, labels, and saves images of all required structures</p> <p>Demonstrates appropriate patient positioning and physician ergonomics for both diagnostic and procedural applications</p> <p>Verbally describes all <i>essential procedures</i></p>	<p>Correctly identifies and labels <i>essential pathology</i> and generates an appropriate diagnostic report</p> <p>Performs <i>essential procedures</i>, including appropriate image labeling, and generates an appropriate procedure report</p>	<p>Correctly identifies and labels <i>desirable pathology</i> and generates an appropriate diagnostic report</p> <p>Performs <i>desirable procedures</i>, including appropriate image labeling, and generates an appropriate procedure report</p> <p>Integrates current research and literature with guidelines to recommend management or guidelines relevant to the procedure</p>	<p>Consistently and independently performs and teaches the skills outlined in previous levels</p> <p>Correctly identifies and labels <i>optional pathology</i> and generates an appropriate diagnostic report</p> <p>Performs <i>optional procedures</i>, including appropriate image labeling, and generates an appropriate procedure report</p> <p>Publishes peer-reviewed work related to sports ultrasound of the shoulder</p>
<input type="checkbox"/>	<input type="checkbox"/>	<input type="checkbox"/>	<input type="checkbox"/>	<input type="checkbox"/>
<p>Comments:</p> <p>Not yet achieved Level 1</p>				

Elbow (anterior, medial, lateral, and posterior)				
Level 1	Level 2	Level 3	Level 4	Level 5
<p>Verbally describes the indications for a diagnostic US of the elbow and lists the structures needed to be imaged during a complete examination</p> <p>Verbally describes the indications, contra-indications, risks and benefits of US-guided elbow injections</p>	<p>Correctly acquires, labels, and saves images of all required structures</p> <p>Demonstrates appropriate patient positioning and physician ergonomics for both diagnostic and procedural applications</p> <p>Verbally describes all <i>essential procedures</i></p>	<p>Correctly identifies and labels <i>essential pathology</i> and generates an appropriate diagnostic report</p> <p>Performs <i>essential procedures</i>, including appropriate image labeling, and generates an appropriate procedure report</p>	<p>Correctly identifies and labels <i>desirable pathology</i> and generates an appropriate diagnostic report</p> <p>Performs <i>desirable procedures</i>, including appropriate image labeling, and generates an appropriate procedure report</p> <p>Integrates current research and literature with guidelines to recommend management or guidelines relevant to the procedure</p>	<p>Consistently and independently performs and teaches the skills outlined in previous levels</p> <p>Correctly identifies and labels <i>optional pathology</i> and generates an appropriate diagnostic report</p> <p>Performs <i>optional procedures</i>, including appropriate image labeling, and generates an appropriate procedure report</p> <p>Publishes peer-reviewed work related to sports ultrasound of the elbow</p>
<input type="checkbox"/>	<input type="checkbox"/>	<input type="checkbox"/>	<input type="checkbox"/>	<input type="checkbox"/>
<p>Comments:</p> <p style="text-align: right;">Not yet achieved Level 1</p>				

Wrist (volar and dorsal)				
Level 1	Level 2	Level 3	Level 4	Level 5
<p>Verbally describes the indications for a diagnostic US of the wrist and lists the structures needed to be imaged during a complete examination</p> <p>Verbally describes the indications, contra-indications, risks and benefits of US-guided wrist injections</p>	<p>Correctly acquires, labels, and saves images of all required structures</p> <p>Demonstrates appropriate patient positioning and physician ergonomics for both diagnostic and procedural applications</p> <p>Verbally describes all <i>essential procedures</i></p>	<p>Correctly identifies and labels <i>essential pathology</i> and generates an appropriate diagnostic report</p> <p>Performs <i>essential procedures</i>, including appropriate image labeling, and generates an appropriate procedure report</p>	<p>Correctly identifies and labels <i>desirable pathology</i> and generates an appropriate diagnostic report</p> <p>Performs <i>desirable procedures</i>, including appropriate image labeling, and generates an appropriate procedure report</p> <p>Integrates current research and literature with guidelines to recommend management or guidelines relevant to the procedure</p>	<p>Consistently and independently performs and teaches the skills outlined in previous levels</p> <p>Correctly identifies and labels <i>optional pathology</i> and generates an appropriate diagnostic report</p> <p>Performs <i>optional procedures</i>, including appropriate image labeling, and generates an appropriate procedure report</p> <p>Publishes peer-reviewed work related to sports ultrasound of the wrist</p>
<input type="checkbox"/>	<input type="checkbox"/>	<input type="checkbox"/>	<input type="checkbox"/>	<input type="checkbox"/>
<p>Comments:</p> <p style="text-align: right;">Not yet achieved Level 1</p>				

Hand and Finger				
Level 1	Level 2	Level 3	Level 4	Level 5
<p>Verbally describes the indications for a diagnostic US of the hand and finger and lists the structures needed to be imaged during a complete examination</p> <p>Verbally describes the indications, contra-indications, risks and benefits of US-guided hand and finger injections</p>	<p>Correctly acquires, labels, and saves images of all required structures</p> <p>Demonstrates appropriate patient positioning and physician ergonomics for both diagnostic and procedural applications</p> <p>Verbally describes all <i>essential procedures</i></p>	<p>Correctly identifies and labels <i>essential pathology</i> and generates an appropriate diagnostic report</p> <p>Performs <i>essential procedures</i>, including appropriate image labeling, and generates an appropriate procedure report</p>	<p>Correctly identifies and labels <i>desirable pathology</i> and generates an appropriate diagnostic report</p> <p>Performs <i>desirable procedures</i>, including appropriate image labeling, and generates an appropriate procedure report</p> <p>Integrates current research and literature with guidelines to recommend management or guidelines relevant to the procedure</p>	<p>Consistently and independently performs and teaches the skills outlined in previous levels</p> <p>Correctly identifies and labels <i>optional pathology</i> and generates an appropriate diagnostic report</p> <p>Performs <i>optional procedures</i>, including appropriate image labeling, and generates an appropriate procedure report</p> <p>Publishes peer-reviewed work related to sports ultrasound of the hand and finger</p>
<input type="checkbox"/>	<input type="checkbox"/>	<input type="checkbox"/>	<input type="checkbox"/>	<input type="checkbox"/>
<p>Comments:</p> <p style="text-align: right;">Not yet achieved Level 1</p>				

Hip (anterior, medial, lateral, and posterior)				
Level 1	Level 2	Level 3	Level 4	Level 5
<p>Verbally describes the indications for a diagnostic US of the hip and lists the structures needed to be imaged during a complete examination</p> <p>Verbally describes the indications, contra-indications, risks and benefits of US-guided hip injections</p>	<p>Correctly acquires, labels, and saves images of all required structures</p> <p>Demonstrates appropriate patient positioning and physician ergonomics for both diagnostic and procedural applications</p> <p>Verbally describes all <i>essential procedures</i></p>	<p>Correctly identifies and labels <i>essential pathology</i> and generates an appropriate diagnostic report</p> <p>Performs <i>essential procedures</i>, including appropriate image labeling, and generates an appropriate procedure report</p>	<p>Correctly identifies and labels <i>desirable pathology</i> and generates an appropriate diagnostic report</p> <p>Performs <i>desirable procedures</i>, including appropriate image labeling, and generates an appropriate procedure report</p> <p>Integrates current research and literature with guidelines to recommend management or guidelines relevant to the procedure</p>	<p>Consistently and independently performs and teaches the skills outlined in previous levels</p> <p>Correctly identifies and labels <i>optional pathology</i> and generates an appropriate diagnostic report</p> <p>Performs optional procedures, including appropriate image labeling, and generates an appropriate procedure report</p> <p>Publishes peer-reviewed work related to sports ultrasound of the hip</p>
<input type="checkbox"/>	<input type="checkbox"/>	<input type="checkbox"/>	<input type="checkbox"/>	<input type="checkbox"/>
<p>Comments:</p> <p style="text-align: right;">Not yet achieved Level 1</p>				

Thigh (anterior, medial, and posterior)				
Level 1	Level 2	Level 3	Level 4	Level 5
<p>Verbally describes the indications for a diagnostic US of the thigh and lists the structures needed to be imaged during a complete examination</p> <p>Verbally describes the indications, contra-indications, risks and benefits of US-guided thigh injections</p>	<p>Correctly acquires, labels, and saves images of all required structures</p> <p>Demonstrates appropriate patient positioning and physician ergonomics for both diagnostic and procedural applications</p> <p>Verbally describes all <i>essential procedures</i></p>	<p>Correctly identifies and labels <i>essential pathology</i> and generates an appropriate diagnostic report</p> <p>Performs <i>essential procedures</i>, including appropriate image labeling, and generates an appropriate procedure report</p>	<p>Correctly identifies and labels <i>desirable pathology</i> and generates an appropriate diagnostic report</p> <p>Performs <i>desirable procedures</i>, including appropriate image labeling, and generates an appropriate procedure report</p> <p>Integrates current research and literature with guidelines to recommend management or guidelines relevant to the procedure</p>	<p>Consistently and independently performs and teaches the skills outlined in previous levels</p> <p>Correctly identifies and labels <i>optional pathology</i> and generates an appropriate diagnostic report</p> <p>Performs <i>optional procedures</i>, including appropriate image labeling, and generates an appropriate procedure report</p> <p>Publishes peer-reviewed work related to sports ultrasound of the thigh</p>
<input type="checkbox"/>	<input type="checkbox"/>	<input type="checkbox"/>	<input type="checkbox"/>	<input type="checkbox"/>
<p>Comments:</p> <p style="text-align: right;">Not yet achieved Level 1</p>				

Knee (anterior, medial, lateral, and posterior)				
Level 1	Level 2	Level 3	Level 4	Level 5
<p>Verbally describes the indications for a diagnostic US of the knee and lists the structures needed to be imaged during a complete examination</p> <p>Verbally describes the indications, contra-indications, risks and benefits of US-guided knee injections</p>	<p>Correctly acquires, labels, and saves images of all required structures</p> <p>Demonstrates appropriate patient positioning and physician ergonomics for both diagnostic and procedural applications</p> <p>Verbally describes all <i>essential procedures</i></p>	<p>Correctly identifies and labels <i>essential pathology</i> and generates an appropriate diagnostic report</p> <p>Performs <i>essential procedures</i>, including appropriate image labeling, and generates an appropriate procedure report</p>	<p>Correctly identifies and labels <i>desirable pathology</i> and generates an appropriate diagnostic report</p> <p>Performs <i>desirable procedures</i>, including appropriate image labeling, and generates an appropriate procedure report</p> <p>Integrates current research and literature with guidelines to recommend management or guidelines relevant to the procedure</p>	<p>Consistently and independently performs and teaches the skills outlined in previous levels</p> <p>Correctly identifies and labels <i>optional pathology</i> and generates an appropriate diagnostic report</p> <p>Performs <i>optional procedures</i>, including appropriate image labeling, and generates an appropriate procedure report</p> <p>Publishes peer-reviewed work related to sports ultrasound of the knee</p>
<input type="checkbox"/>	<input type="checkbox"/>	<input type="checkbox"/>	<input type="checkbox"/>	<input type="checkbox"/>
<p>Comments:</p> <p style="text-align: right;">Not yet achieved Level 1</p>				

Leg and Ankle (anterior, medial, lateral, and posterior)				
Level 1	Level 2	Level 3	Level 4	Level 5
<p>Verbally describes the indications for a diagnostic US of the leg and ankle and lists the structures needed to be imaged during a complete examination</p> <p>Verbally describes the indications, contra-indications, risks and benefits of US-guided leg and ankle injections</p>	<p>Correctly acquires, labels, and saves images of all required structures</p> <p>Demonstrates appropriate patient positioning and physician ergonomics for both diagnostic and procedural applications</p> <p>Verbally describes all <i>essential procedures</i></p>	<p>Correctly identifies and labels essential pathology and generates an appropriate diagnostic report</p> <p>Performs <i>essential procedures</i>, including appropriate image labeling, and generates an appropriate procedure report</p>	<p>Correctly identifies and labels <i>desirable pathology</i> and generates an appropriate diagnostic report</p> <p>Performs <i>desirable procedures</i>, including appropriate image labeling, and generates an appropriate procedure report</p> <p>Integrates current research and literature with guidelines to recommend management or guidelines relevant to the procedure</p>	<p>Consistently and independently performs and teaches the skills outlined in previous levels</p> <p>Correctly identifies and labels <i>optional pathology</i> and generates an appropriate diagnostic report</p> <p>Performs <i>optional procedures</i>, including appropriate image labeling, and generates an appropriate procedure report</p> <p>Publishes peer-reviewed work related to sports ultrasound of the leg and ankle</p>
<input type="checkbox"/>	<input type="checkbox"/>	<input type="checkbox"/>	<input type="checkbox"/>	<input type="checkbox"/>
<p>Comments:</p> <p style="text-align: right;">Not yet achieved Level 1</p>				

Foot (hindfoot, midfoot, and forefoot)				
Level 1	Level 2	Level 3	Level 4	Level 5
<p>Verbally describes the indications for a diagnostic US of the foot and lists the structures needed to be imaged during a complete examination</p> <p>Verbally describes the indications, contra-indications, risks and benefits of US-guided foot injections</p>	<p>Correctly acquires, labels, and saves images of all required structures</p> <p>Demonstrates appropriate patient positioning and physician ergonomics for both diagnostic and procedural applications</p> <p>Verbally describes all <i>essential procedures</i></p>	<p>Correctly identifies and labels <i>essential pathology</i> and generates an appropriate diagnostic report</p> <p>Performs <i>essential procedures</i>, including appropriate image labeling, and generates an appropriate procedure report</p>	<p>Correctly identifies and labels <i>desirable pathology</i> and generates an appropriate diagnostic report</p> <p>Performs <i>desirable procedures</i>, including appropriate image labeling, and generates an appropriate procedure report</p> <p>Integrates current research and literature with guidelines to recommend management or guidelines relevant to the procedure</p>	<p>Consistently and independently performs and teaches the skills outlined in previous levels</p> <p>Correctly identifies and labels <i>optional pathology</i> and generates an appropriate diagnostic report</p> <p>Performs <i>optional procedures</i>, including appropriate image labeling, and generates an appropriate procedure report</p> <p>Publishes peer-reviewed work related to sports ultrasound of the foot</p>
<input type="checkbox"/>	<input type="checkbox"/>	<input type="checkbox"/>	<input type="checkbox"/>	<input type="checkbox"/>
<p>Comments:</p> <p style="text-align: right;">Not yet achieved Level 1</p>				

AMSSM Sample Sports Ultrasound Objective Structured Clinical Exam (OSCE)
Revised 2020

Date: _____

Examinee: _____

Examiner: _____

GENERAL PRINCIPLES

- ☐ Transducer selection
- ☐ Image optimization (presets, depth, focus, gain, etc.)
- ☐ Appropriate use of transducer movement to fully evaluate structures and reduce anisotropy
- ☐ Use of Doppler imaging
- ☐ Ergonomics
- ☐ Patient comfort (transducer pressure, appropriate draping, positioning, etc.)

TRAUMA

- ☐ eFAST (extended Focused Assessment of Sonography in Trauma)
 - ☐ Hepatorenal recess
 - ☐ Perisplenic recess
 - ☐ Retro-vesicular or retro-uterine pouch
 - ☐ Subxiphoid pericardial space
 - ☐ Lung sliding

SHOULDER

- ☐ Biceps tendon including evaluation for instability
- ☐ Subscapularis
- ☐ Acromioclavicular joint
- ☐ Infraspinatus muscle and tendon
- ☐ Teres minor muscle and tendon
- ☐ Glenohumeral Joint recess (posterior)
- ☐ Spinoglenoid notch
- ☐ Supraspinatus muscle and tendon
- ☐ Subacromial/Subdeltoid bursa
- ☐ Coracoacromial ligament
- ☐ Dynamic evaluation of impingement

ELBOW

- ☐ Anterior
 - ☐ Brachialis muscle and tendon
 - ☐ Brachial artery and vein
 - ☐ Median nerve
 - ☐ Pronator teres muscle and tendon
 - ☐ Radial nerve (including posterior interosseous nerve and superficial radial nerve)
 - ☐ Brachioradialis muscle
 - ☐ Anterior humeroradial joint and recesses
 - ☐ Anterior humeroulnar joint and recesses
 - ☐ Biceps tendon and muscle
- ☐ Medial
 - ☐ Common flexor/pronator tendon and muscles

AMSSM Sample Sports Ultrasound Objective Structured Clinical Exam (OSCE)
Revised 2020

- ☐ Ulnar collateral ligament including dynamic valgus stress views as indicated
- ☐ Humero-ulnar joint
- ☐ Ulnar nerve including assessment of instability with flexion/extension views
- ☐ Lateral
 - ☐ Common extensor tendon and muscles
 - ☐ Radial collateral ligament
 - ☐ Humero-radial joint
 - ☐ Radial nerve from mid-arm to the bifurcation
 - ☐ Posterior interosseous nerve through supinator muscle
 - ☐ Brachioradialis
 - ☐ Extensor carpi radialis longus
- ☐ Posterior
 - ☐ Triceps tendon and muscles
 - ☐ Olecranon fossa and posterior joint recess
 - ☐ Olecranon process
 - ☐ Olecranon bursa
 - ☐ Ulnar nerve including assessment of instability with flexion/extension views

WRIST/HAND/FINGER

- ☐ Volar wrist
 - ☐ Carpal tunnel including dynamic evaluation of tendon and nerve motion
 - ☐ Flexor retinaculum/Transverse carpal ligament
 - ☐ Median nerve
 - ☐ Flexor pollicis longus tendon
 - ☐ Flexor digitorum profundus and superficialis tendons
 - ☐ Palmaris longus tendon
 - ☐ Flexor carpi radialis longus tendon
 - ☐ Radial artery
 - ☐ Joints (radiocarpal, ulnocarpal, midcarpal, carpometacarpal) including assessment of volar ganglion cyst
 - ☐ Ulnar nerve within Guyon's canal
 - ☐ Ulnar artery
 - ☐ Flexor carpi ulnaris tendon
- ☐ Dorsal Wrist
 - ☐ Extensor tendons and muscles (6 dorsal compartments)
 - ☐ Dynamic assessment of extensor carpi ulnaris instability
 - ☐ Extensor retinaculum
 - ☐ Dorsal scapholunate ligament including dynamic stress views
 - ☐ Joints (radiocarpal, ulnocarpal, midcarpal, carpometacarpal) including evaluation of dorsal synovial recesses and assessment of dorsal ganglion cyst
 - ☐ Superficial radial nerve
- ☐ Hand and finger
 - ☐ Metacarpophalangeal (MCP) and interphalangeal joints
 - ☐ Volar plates
 - ☐ Collateral ligaments
 - ☐ Flexor tendons and sheaths

AMSSM Sample Sports Ultrasound Objective Structured Clinical Exam (OSCE)
Revised 2020

- ☐ A1 and A2 pulleys
- ☐ Extensor tendons
- ☐ Ulnar collateral ligament of 1st MCP joint including dynamic stress views

HIP/PELVIS

- ☐ Anterior
 - ☐ Femoral head, neck, capsule, and anterior synovial recess
 - ☐ Hip joint assessment for effusion
 - ☐ Anterior labrum
 - ☐ Femoral vessels and nerve
 - ☐ Iliopsoas muscle, tendon, and bursa
 - ☐ Sartorius and tensor fascia latae tendons and muscles
 - ☐ Rectus femoris tendon(s) and muscles
 - ☐ Dynamic scanning for snapping hip
- ☐ Medial
 - ☐ Adductor muscle origins (Adductor longus/brevis/magnus and gracilis) and tendons
 - ☐ Pubic bone and symphysis including dynamic assessment as indicated
 - ☐ Pectineus muscle
 - ☐ Distal rectus abdominis muscle and tendon
 - ☐ Rectus abdominis-adductor longus aponeurosis
 - ☐ Obturator nerve (including anterior and posterior branches)
- ☐ Lateral
 - ☐ Greater trochanter of femur (including identification of anterior, lateral, posterior, and superoposterior facets)
 - ☐ Gluteus minimus tendon and muscle
 - ☐ Gluteus medius tendon and muscle (anterior and posterior bands)
 - ☐ Greater trochanteric (subgluteus maximus) bursa
 - ☐ Superficial arch at greater trochanter (Gluteus maximus muscle – iliotibial band – tensor fasciae latae muscle)
 - ☐ Dynamic scanning for snapping hip
- ☐ Posterior
 - ☐ Gluteus maximus muscle and insertion onto iliotibial band
 - ☐ Piriformis muscle and tendon
 - ☐ Quadratus femoris muscle
 - ☐ Proximal hamstring tendon complex (conjoint tendon and semimembranosus)
 - ☐ Proximal biceps femoris, semimembranosus, and semitendinosus muscles
 - ☐ Ischial tuberosity and bursal region
 - ☐ Sciatic nerve
 - ☐ Posterior hip joint

THIGH

- ☐ Anterior
 - ☐ Anterior thigh muscles
 - ☐ Rectus femoris
 - ☐ Vastus medialis
 - ☐ Vastus lateralis

AMSSM Sample Sports Ultrasound Objective Structured Clinical Exam (OSCE)
Revised 2020

- ☐ Vastus intermedius
 - ☐ Sartorius
 - ☐ Femoral nerve
 - ☐ Femur
 - ☐ Medial
 - ☐ Medial thigh muscle bellies and tendons
 - ☐ Adductor longus
 - ☐ Adductor brevis
 - ☐ Adductor magnus
 - ☐ Gracilis
 - ☐ Sartorius
 - ☐ Femoral nerve
 - ☐ Obturator nerve
 - ☐ Femur
 - ☐ Posterior
 - ☐ Posterior thigh muscles
 - ☐ Biceps femoris
 - ☐ Semitendinosus
 - ☐ Semimembranosus
 - ☐ Adductor magnus
 - ☐ Sciatic nerve
 - ☐ Femur
- KNEE**
 - ☐ Anterior
 - ☐ Distal quadriceps muscles
 - ☐ Quadriceps tendon
 - ☐ Suprapatellar recess of knee joint
 - ☐ Patella and prepatellar bursa
 - ☐ Patellar tendon and tibial tubercle
 - ☐ Hoffa's fat pad
 - ☐ Superficial infrapatellar bursa
 - ☐ Deep infrapatellar bursa
 - ☐ Vastus medialis and medial retinaculum including the medial patellofemoral ligament and dynamic assessment of stability
 - ☐ Vastus lateralis and lateral retinaculum
 - ☐ Trochlear cartilage
 - ☐ Anterior horns of medial and lateral menisci
 - ☐ Medial
 - ☐ Medial collateral ligament (superficial and deep portions) with valgus stress testing
 - ☐ Medial meniscus (anterior and posterior horns)
 - ☐ Tibiofemoral joint space
 - ☐ Pes anserine tendons and bursa
 - ☐ Medial patellar retinaculum and medial patellofemoral ligament
 - ☐ Medial patellofemoral joint
 - ☐ Lateral

AMSSM Sample Sports Ultrasound Objective Structured Clinical Exam (OSCE)
Revised 2020

- ☐ Iliotibial band
- ☐ Lateral synovial recess of the knee
- ☐ Lateral meniscus anterior and posterior horns
- ☐ Tibiofemoral joint space
- ☐ Lateral collateral ligament with varus stress testing
- ☐ Biceps femoris tendon and muscles
- ☐ Popliteus tendon and muscle
- ☐ Lateral patellar retinaculum
- ☐ Lateral patellofemoral joint
- ☐ Proximal tibiofibular joint including assessment of instability
- ☐ Common fibular nerve at fibular tunnel
- ☐ Posterior
 - ☐ Popliteal artery and vein
 - ☐ Semimembranosus, semitendinosus, and biceps femoris (long and short heads) muscles and tendons
 - ☐ Medial & lateral gastrocnemius muscles and tendons
 - ☐ Evaluation for Baker's cyst at interval between semimembranosus and medial gastrocnemius
 - ☐ Sciatic, tibial, and common fibular nerves
 - ☐ Posterior horns of medial and lateral menisci
 - ☐ Posterior tibiofemoral joint
 - ☐ Posterior cruciate ligament
 - ☐ Popliteus muscle

LEG AND ANKLE

- ☐ Anterior
 - ☐ Anterior leg compartment muscles and tendons (tibialis anterior, extensor digitorum longus, extensor hallucis longus, peroneus tertius)
 - ☐ Anterior tibiotalar joint
 - ☐ Talar dome cartilage
 - ☐ Sinus tarsi
 - ☐ Anterior inferior tibiofibular ligament including dynamic assessment
 - ☐ Superficial fibular nerve at exit from crural fascia through division into medial and intermediate dorsal cutaneous nerves
 - ☐ Deep fibular nerve
 - ☐ Distal anterior tibial artery and dorsalis pedis artery
- ☐ Medial
 - ☐ Medial gastrocnemius muscle
 - ☐ Soleus muscle
 - ☐ Flexor retinaculum
 - ☐ Deep posterior compartment muscles (tibialis posterior, flexor digitorum longus, and flexor hallucis longus)
 - ☐ Deltoid ligament
 - ☐ Medial tibiotalar joint
 - ☐ Medial aspect of posterior subtalar joint
 - ☐ Tarsal tunnel (tibial, medial plantar, and lateral plantar nerves)

AMSSM Sample Sports Ultrasound Objective Structured Clinical Exam (OSCE)
Revised 2020

- ☐ Posterior tibial artery and veins
- ☐ Lateral
 - ☐ Lateral gastrocnemius muscle
 - ☐ Soleus muscle
 - ☐ Fibularis longus and brevis muscles and tendons
 - ☐ Superior fibular retinaculum
 - ☐ Dynamic assessment for fibular subluxation/dislocation
 - ☐ Fibular trochlea (peroneal tubercle)
 - ☐ Fibula for acute traumatic or stress fracture
 - ☐ Anterior talofibular ligament including dynamic stress views
 - ☐ Calcaneofibular ligament including dynamic stress views
 - ☐ Anterior tibiofibular ligament including dynamic stress views
 - ☐ Lateral recess of tibiotalar joint including dynamic assessment of impingement
 - ☐ Lateral recess of posterior subtalar joint
 - ☐ Sinus tarsi
 - ☐ Sural nerve and lateral calcaneal nerve
- ☐ Posterior
 - ☐ Medial and lateral gastrocnemius muscles
 - ☐ Soleus muscle
 - ☐ Achilles tendon and paratenon
 - ☐ Retrocalcaneal bursa
 - ☐ Retro-Achilles/Superficial/Subcutaneous bursa
 - ☐ Plantaris tendon
 - ☐ Posterior tibiotalar joint
 - ☐ Posterior subtalar joint

FOOT

- ☐ Hindfoot
 - ☐ Plantar fascia (central and lateral cords)
 - ☐ Plantar fat pad including dynamic assessment of compression
 - ☐ Tarsal tunnel (tibial, medial plantar, and lateral plantar nerves)
 - ☐ Sural nerve and lateral calcaneal nerve
 - ☐ Achilles tendon and paratenon
 - ☐ Plantaris tendon
 - ☐ Retro-Achilles/Superficial Achilles/Subcutaneous bursa
- ☐ Midfoot
 - ☐ Talonavicular joint
 - ☐ Calcaneocuboid joint
 - ☐ Tarsometatarsal joints
 - ☐ Dorsal Lisfranc ligament including dynamic assessment of stability
 - ☐ Deep fibular nerve
 - ☐ Anterior tibialis tendon insertion
 - ☐ Posterior tibialis tendon insertion
 - ☐ Spring ligament
 - ☐ Flexor digitorum longus and flexor hallucis longus at the Knot of Henry
 - ☐ Medial plantar nerve

AMSSM Sample Sports Ultrasound Objective Structured Clinical Exam (OSCE)
Revised 2020

- ☐ Plantar fascia lateral cord insertion at 5th metatarsal base
- ☐ Fibularis brevis insertion at 5th metatarsal base
- ☐ Forefoot
 - ☐ Metatarsophalangeal and interphalangeal joints
 - ☐ Metatarsals and phalanges for acute traumatic or stress fracture as indicated
 - ☐ Metatarsal interspace evaluation for Morton's neuroma and intermetatarsal bursitis
 - ☐ Plantar plate including dynamic assessment
 - ☐ Flexor tendons
 - ☐ Great toe sesamoids including dynamic assessment

Signature (completed and reviewed)

Fellow

Faculty evaluator

Appendix 4 – Online Ultrasound Educational Resources

Topic	URL
American Medical Society for Sports Medicine (www.amssm.org)	
Online didactics	https://www.amssm.org/UltrasoundOnlineDidactics.php
YouTube Channel	https://www.youtube.com/channel/UCl-t3cujeNDUApfXyGX5w
American Institute of Ultrasound in Medicine (www.AIUM.org)	
Webinar series	https://www.aium.org/cme/cmeseach.aspx?type=W&Id=0&Stext=
Practice Parameter for the Performance of a Musculoskeletal Ultrasound Examination	https://www.aium.org/resources/guidelines/musculoskeletal.pdf
Practice Parameter for the Performance of Selected Ultrasound-Guided Procedures	https://www.aium.org/resources/guidelines/usGuidedProcedures.pdf
Standards and Guidelines for the Accreditation of Ultrasound Practices	https://www.aium.org/officialStatements/26
Training Guidelines for Physicians, Chiropractors and Other Licensed Medical Providers Who Evaluate and Interpret Diagnostic Musculoskeletal Ultrasound Examinations	https://www.aium.org/officialStatements/51
Training Guidelines for Physicians and Advanced Clinical Providers Performing Point-of-Care Ultrasound Examinations	https://www.aium.org/resources/viewStatement.aspx?id=74
Training Guidelines for Physicians and Chiropractors Who Perform Ultrasound-Guided Musculoskeletal Interventional Procedures	https://www.aium.org/officialStatements/61
Practice Parameter for Documentation of an Ultrasound Examination	https://www.aium.org/resources/guidelines/documentation.pdf
Guidelines for Cleaning and Preparing External- and Internal-Use Ultrasound Transducers and Equipment Between	https://www.aium.org/officialStatements/57

Patients as well as Safe Handling and Use of Ultrasound
Coupling Gel

Official Statement on Transducer Testing and Repair

<https://www.aium.org/officialStatements/73>

European Society of Musculoskeletal Radiology (www.essr.org)

Technical Guidelines

<https://www.essr.org/subcommittees/ultrasound/>

American College of Radiology (www.acr.org)

Practice Parameters and Technical Standards

<https://www.acr.org/-/media/ACR/Files/Practice-Parameters/US-MSK.pdf>

Selected Books

Bianchi S, Martinoli C. Ultrasound of the Musculoskeletal System. Springer, New York, Springer, 2007. 992 pages.

Jacobson JA. Fundamentals of Musculoskeletal Ultrasound, 3rd ed., Elsevier; Philadelphia; 2017. 472 pages

Malanga G, Mautner K (Eds.). Atlas of Ultrasound-guided Musculoskeletal Injections. McGraw-Hill; New York, 2014. 480 pages
