

Slocum, D. B., 1967 "The shin splint syndrome. Medical aspects and differential diagnosis." *Amer.J.Surg.* 114: 875-881.

Snook, G. A., 1975. "Intermittent claudication in athletes." *Amer.J.Sports Med.* 3: 71-75.

Westlin, N. E., 1977 "Traksjonsperiostitis tibia – shin splint." *Nordisk Idrettsmedisinisk Kongress, Beitostolen, Norway, Proceedings:* 101-106.

Wiklund, P-E., 1977 "Closed compartment-syndrom i nedre extremiteten." *Läkartidn.* 74: 121-123.

Williams, J. G. P. and Sperryn, P. N. (ed.), 1976. *Sports Medicine*, 2nd ed., Edward Arnold, London.

CORRIGENDUM

The diagram below relates to Fig. 2 on Page 73, Vol. 13, No. 2 of the article by T. Reilly, J. Hopkins and N. Howlett. The editor regrets that a second copy of the somatogram of Fig. 1 was included inadvertently instead of this graph.

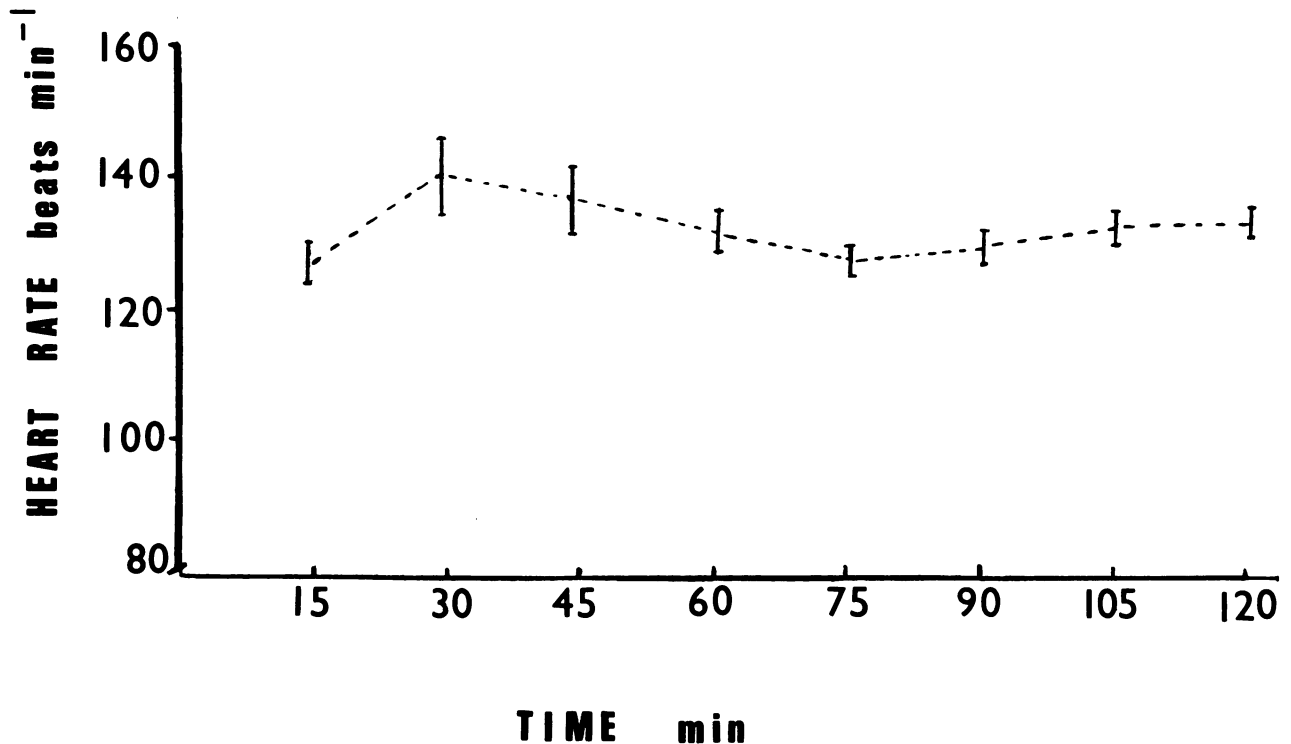


Figure 2: Heart rate ($\bar{x} \pm S.D.$) for successive 15 min periods of the prolonged training session on road.