

CASE REPORT

COMBINED FORCE INJURY OF THE ELBOW JOINT – THE MECHANISM CLARIFIED

G. R. McLATCHIE, MB, ChB, FRCS, J. H. MILLER, MB, ChB, FRCSE, FRCS (Glasgow)
and E. W. MORRIS, MB, BS, FRCSE

Glasgow Royal Infirmary, Glasgow

ABSTRACT

An unusual elbow injury occurring as a result of a poorly executed breakfall in judo is recorded. The treatment, possible mechanism and outcome are described. The poor prognosis of severe lesions is emphasised with reference to current literature.

DEFINITION

Combined force injury of the elbow joint is a composite lesion in which osseous and soft tissue damage occurs. As referred to in the text it implies a fracture of the radial head or neck combined with fracture of the olecranon process of the ulna. Associated medial or lateral collateral ligamentous instability and dislocation of the elbow joint may be present. It is not a Monteggia fracture and its treatment is different.

INTRODUCTION

Such injuries are uncommon and to our knowledge only two articles deal specifically with this lesion (Kopp, 1975, Morris et al, 1978). At the elbow clinic in Glasgow Royal Infirmary this lesion accounts for 1.5% of 1200 elbow fractures which are currently being reviewed. It can wrongfully be diagnosed as a variety of Monteggia fracture dislocation. However, Monteggia in 1814 described the ulnar fracture to be located between the proximal one third of the ulna and the base of the olecranon with anterior dislocation of the radial head. In our series (Morris et al, 1978) combined force fractures are commoner than the better known Monteggia fracture.

CASE REPORT

A 33 year old male judoka attended Glasgow Royal Infirmary with an injury to his right elbow sustained when attempting to perform a breakfall in training. Radiologically he had a fracture of the olecranon process and of the radial neck with posterior dislocation of the elbow joint (Fig. 1). Under anaesthetic medial and lateral instability of the elbow joint was noted. Screw fixation of the olecranon with manipulation of the radial head into the anatomical position was carried out on the night of his injury. He was then placed in a plaster of paris bandage with the elbow at right angles for a period

of 4 weeks when he was found to be pain free and active movements begun.

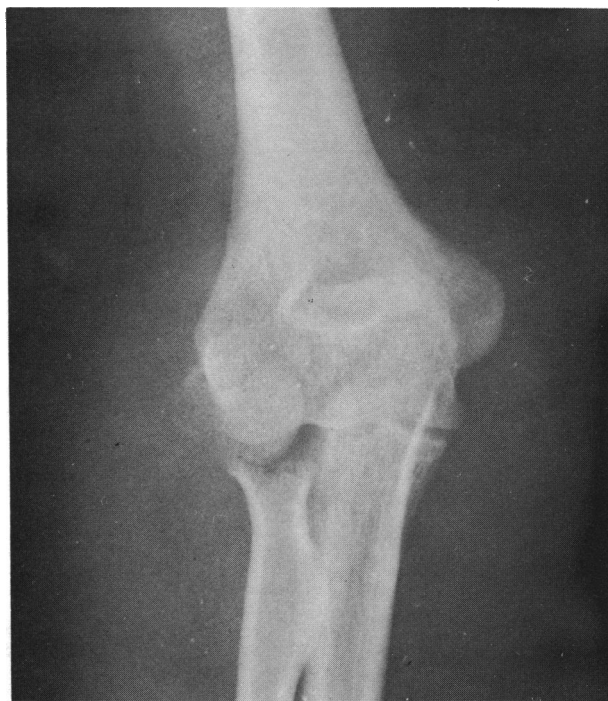

Figure 1a: A combined fracture in an adult. In addition to a radial neck fracture this patient was found at surgery to have a commuted radial head fracture.

He was reviewed 3 monthly. After 6 months limitation of elbow movements was noted:— extension was decreased by 45° compared to his normal left arm, flexion by 15° , supination by 15° and pronation by 25° .

After 1 year he complained that he had painful

tingling in his right forearm. On examination weakness of flexor digitorum profundus in the 5th finger was found and he had hyperaesthesia in the ulnar nerve distribution of his right forearm. Ulnar nerve transposition was carried out but after a year's follow up he still had painful paraesthesia over the ulnar nerve cutaneous distribution with extreme discomfort around the ulnar side of his elbow. Limitation of movement remained the same.

Radiologically the elbow joint was grossly disorganised (Fig. 2) with irregularity of the radial head. The articular surface of the olecranon was also irregular. He had now widespread osteoarthritis of the right elbow joint with a varus deformity. His result was assessed as poor (Radin and Riseborough, 1966) both objectively and functionally but he was prepared to accept this and had given up his sport.

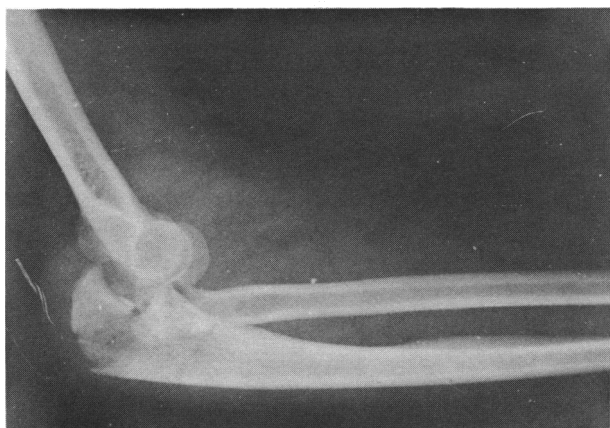

Figure 1b: A combined fracture in an adult.

HYPOTHESIS

The mechanism of injury is interesting. We believe that in this patient's case there are two possibilities (Figs. 3, 4, 5, 6, 7 and 8). When a breakfall is performed badly in judo the outstretched hand makes contact first with the ground, with the full weight of the body upon it (Fig. 3). This provides a longitudinal compression force driving the radial head against the capitellum of the humerus and this fractures it (Fig. 4). The force is so great that the muscles are unable to sustain the elbow in a braced attitude so that it collapses under the body weight and leads to direct impact with the ground (Fig. 5). Following this the distal end of the humerus fractures the olecranon at its base (Fig. 6).

Secondly, a mechanism which we have termed "nut cracker" lesion could also exist. A fall directly on to the

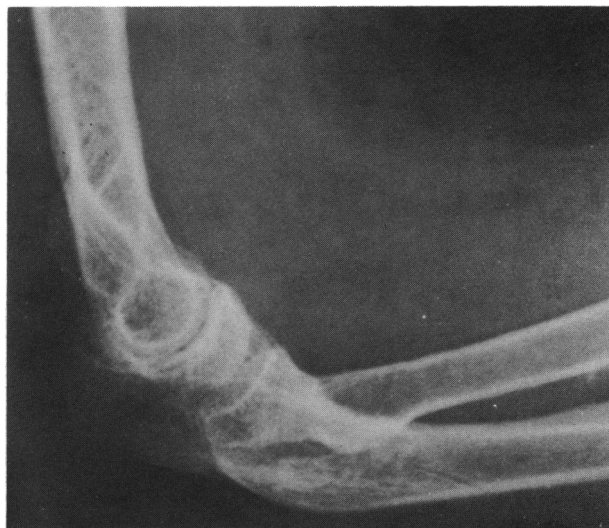

Figure 2: Complications of combined fractures.

1. Osteoarthritis
2. Radial Neck Deformity

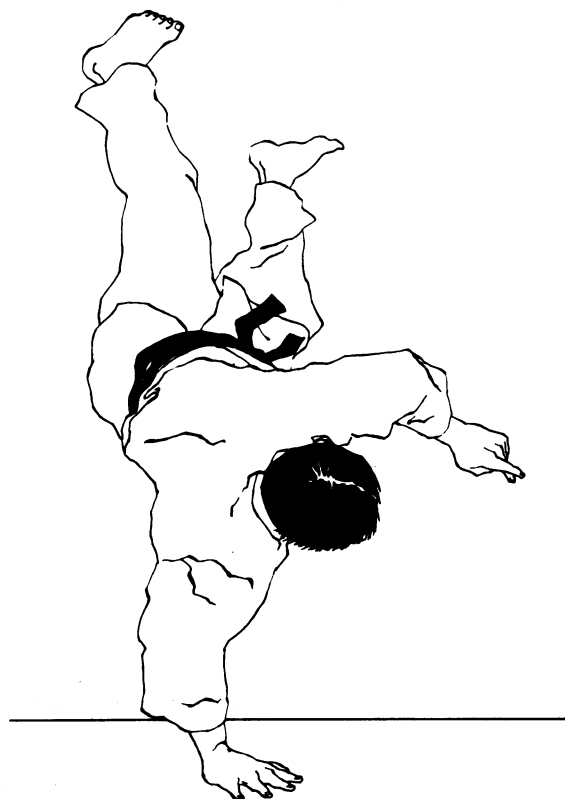


Figure 3: A poorly executed break fall in judo. The judoka, airborne, falls with the full weight of his body on his outstretched hand.

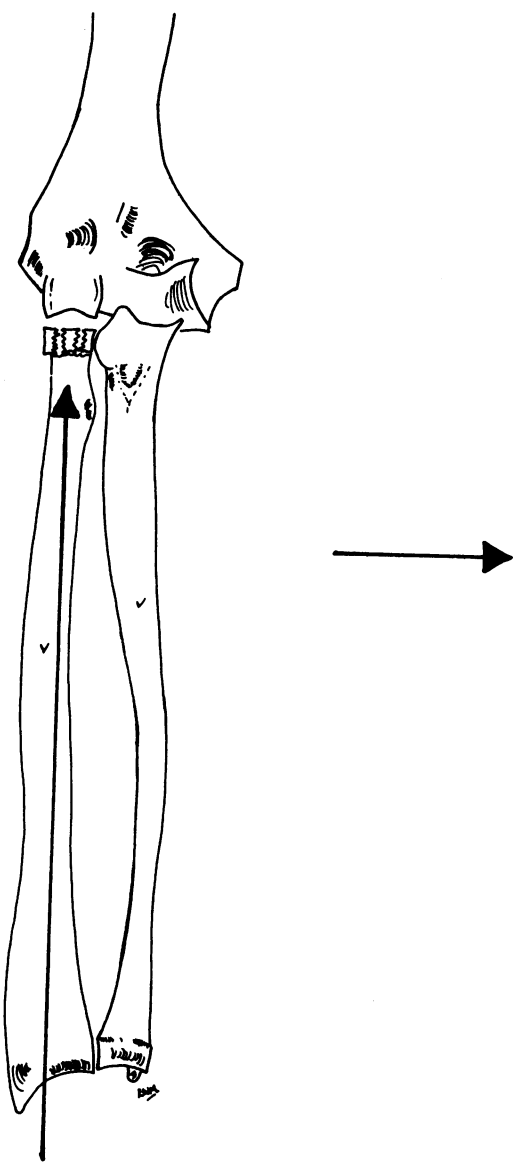


Figure 4: The force from the fall on to the outstretched hand is directed along the radius causing fracture of the radial head.

forearm causes hyperflexion of the elbow joint and direct injury occurs to the olecranon fracturing it (Fig. 7). The radial head is then crushed like a nut in a nut cracker as the hyperflexion force reduces the margin of the radial head into the radial fossa and continuing its application fractures it (Fig. 8). Thomas (1929) substantiates that most fractures of the elbow region result from a fall on to the hand and the force of the fall tends to flex and not extend the elbow.

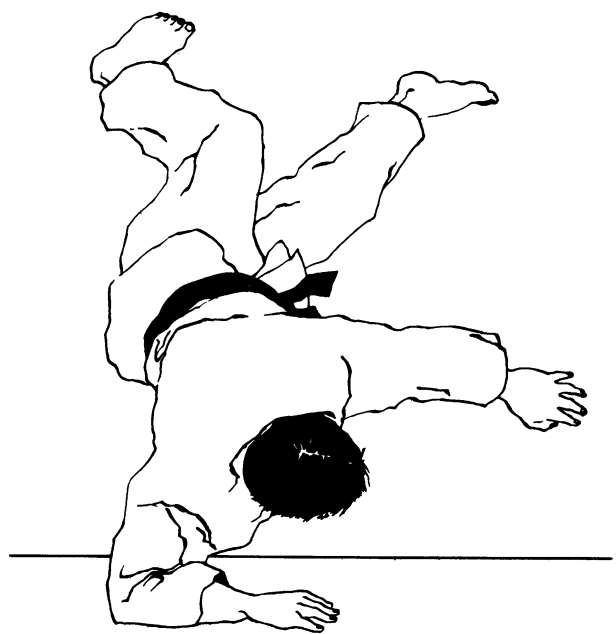


Figure 5: Under the force of his body weight the elbow flexes and the olecranon impacts directly with the ground.

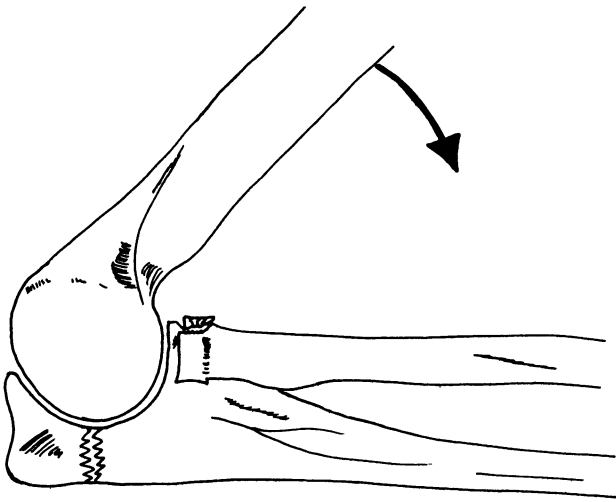


Figure 6: The fall having caused flexion of the elbow joint produces direct trauma to the olecranon process and fracture results.

COMMENT

This injury was treated in a similar manner to the eighteen combined force injuries which we have treated since 1960, i.e. fixation of the olecranon fracture with manipulation or excision of the radial head when indicated. This depends on its degree of displacement and comminution.

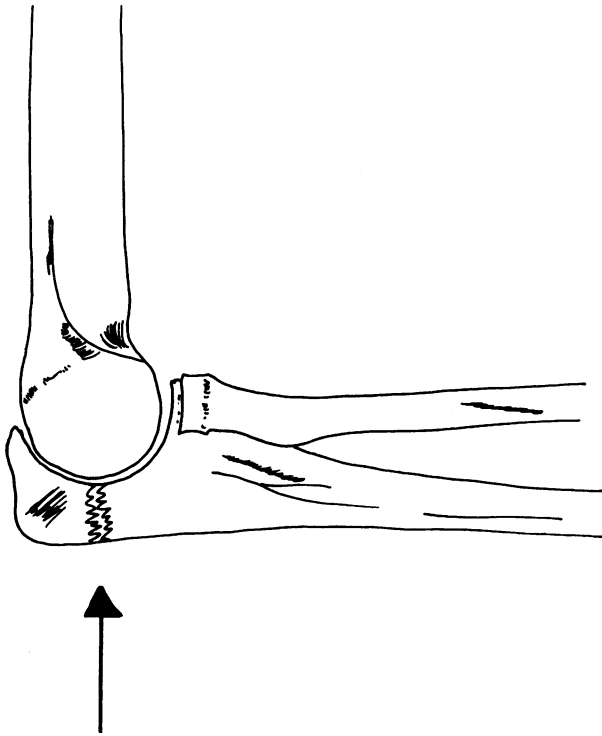


Figure 7: A fall on to the outstretched hand produces flexion of the elbow joint. Direct trauma then leads to fracture of the olecranon.

The prognosis of such an injury is poor in adults (Morris et al, 1978) with osteoarthritis as the main sequel. Pain is a common late finding and the limitation of motion described, especially of supination, is characteristic.

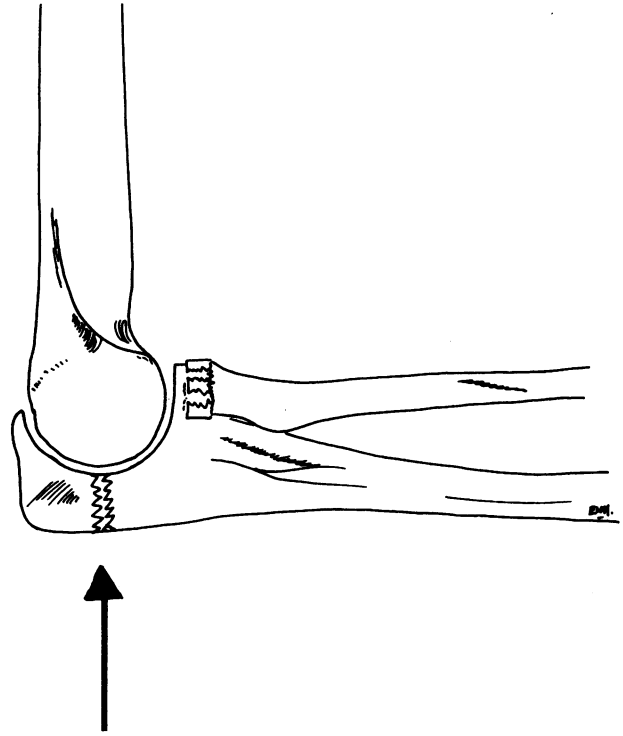


Figure 8: Flexion continues and the radial head is crushed between the radial fossa and the ground like a nut in a nut cracker.

ACKNOWLEDGEMENTS

We wish to thank Mr. Douglas Bryce, artist, who prepared the illustrations. We also wish to thank the secretarial staff for preparing the manuscript.

REFERENCES

- Kopp, P. 1975. "The problem in the choice of operative treatment of Fractures of the radial head and olecranon". *Beitr.Orthop.Traumatol.* Vol. 22 (9): 483-494.
- Monteggia, G. B. *Instituzione Chirurgiche*, 2nd ed. Milan, G. Masper: 1813-1815.
- Morris, E. W., Miller, J. H., McLatchie, G. R., Amis, A. "Combined force injuries of the elbow joint". Presented to the British Orthopaedic Association, April 1978.
- Morris, E. W., Miller, J. H., McLatchie, G. R., Amis, A. 1978. "Combined force injuries of the elbow joint." *British Journal of Bone and Joint Surgery*, Vol. 60B (3).
- Radin, E. L. and Riseborough, E. J. 1966. "Fractures of the radial head". *Journal of Bone and Joint Surgery*, 48a (6): 1055, 1966.
- Thomas, T. T. 1929. "A contribution to the mechanism of fractures and dislocations in the elbow region". *Annal Surgery*, Vol. 89: 108-121.