

R. Cetti

CONSERVATIVE TREATMENT OF INJURY TO THE FIBULAR LIGAMENTS OF THE ANKLE

René CETTI, MD

Hospital of Orthopaedic Surgery, Sorø, Denmark

ABSTRACT

Fifty-one patients with fibular ligamentous injury of the ankle are presented. The treatment consisted of complete non-weight-bearing of the affected foot by use of elbow crutches for three weeks. All patients were seen at follow-up eighteen months after the accident. The results are discussed in the light of previous literature on conservative and operative treatment of lateral ligament injuries.

Residual symptoms were present in 15.7 per cent, but none needed further treatment.

It is emphasised that the treatment described in the present study diminishes the risk of subjective functional instability and gives a quick return to normal gait and sport.

INTRODUCTION

Among problems in traumatology only few have been subjected to such a great interest and such diverging opinions as the treatment of fibular ligamentous injuries of the ankle.

Many authors employ conservative treatment, and only resort to operation in those cases where conservative treatment results in unacceptable ankle malfunction or where the trauma has resulted in severe damage to the ligaments (Adler, H., 1976), (Anderson, K. J. and Lecocq, J. F., 1954), (Duquennoy, A. et al, 1975), (Dziob, J. H., 1956).

Problems in the treatment of ligamentous ankle injuries deal not only with the advantages and disadvantages of conservative versus operative treatment, but also with the length and kind of immobilisation. Freeman (1965) stressed that early mobilisation after ligamentous injury to the ankle enhances muscular stimulation and proprioception and thereby adds to the stability of the ankle.

Address for Correspondence:

Dr. René Cetti, MD,
Betty Nansens Alle 31,
2500 Valby,
Copenhagen,
Denmark

The aim of this study is to elucidate to what extent non-weight-bearing without plaster is a sufficient treatment of injured fibular ankle ligaments.

PATIENTS AND METHODS

During the period February, 1978 to November, 1979, 702 patients with acute ankle sprains were treated in the Hospital of Orthopaedic Surgery in Sorø. Fifty-seven had rupture of the lateral ligaments.

The diagnosis was based on the presence of tenderness, oedema and/or haematoma in front of and distal to the lateral malleolus, corresponding to the lateral ligaments. The anterior drawer test and talar tilt test were included in the clinical examination.* To exclude fractures standard radiograms of the ankle were taken. Verification of the ruptured fibular ankle ligaments was based on talar tilt seen on X-Ray. A difference of six degrees or more between the injured (I) and the uninjured (U) ankle was considered diagnostic of ligamentous rupture (Fig. 1).

All patients with ligament injuries were requested to return for clinical and radiological re-examination. Four could not be traced and two failed to attend. Fifty-one were thus fully re-examined eighteen months after the

**See preceding paper by Kristiansen for definition of these tests.*

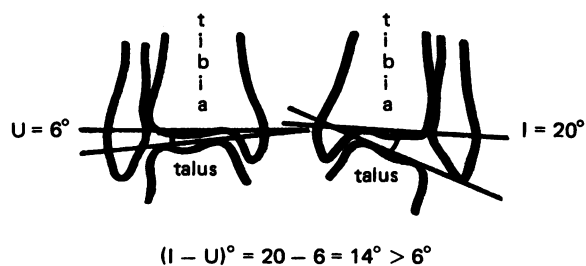


Fig. 1: Roentgenological talar tilt. The difference between the injured (I) and uninjured (U) ankle is more than five degrees. This is considered diagnostic of ligamentous rupture.

injury. Twenty-five were men and twenty-six women, the mean age at the time of accident was twenty-two years (range 11-53). The left ankle was injured in twenty-nine patients, the right in twenty-two. The relations between age, sex and side of injury are shown in Table I.

TABLE I

Age, sex and side of injury in fifty-one patients with injured fibular ankle ligaments

Age group	Males		Females	
	Right	Left	Right	Left
	no.	no.	no.	no.
10 - 15	1	1	4	3
16 - 20	3	4	6	7
21 - 25	3	3	0	2
26 - 30	3	4	1	1
31 - 35	0	0	1	0
36 - 40	0	0	0	1
41 - 45	0	2	0	0
46 - 50	0	0	0	0
51 - 55	0	1	0	0
Total	10	15	12	14
Average	22.4	26.4	18.2	19.3
age	24.4		18.8	

Most patients sustained their sprains while engaged in sport (61%). The cause of injury is shown in Table II, and the sports involved in Table III.

Treatment consisted of complete non-weight-bearing of the affected foot by the use of elbow crutches for three weeks. Active exercises were started immediately.

Treatment was initiated within thirty-six hours from the time of accident. Forty-two patients (82%) reached hospital within six hours. The mean time from accident to arrival at the emergency room was four hours (Table IV).

TABLE II

Distribution of fifty-one patients with injured fibular ankle ligaments according to the circumstances of the accident.

Cause of injury	No.	Per cent
Sport	31	60.8
Work	9	17.6
Home	6	11.8
Traffic	3	5.9
Others	2	3.9
Total	51	100.0

TABLE III

Sport situations in thirty-one patients with fibular ligamentous ankle injuries.

Sport	Competitive Sport		Exercising Sport	
	No.	Per cent	No.	Per cent
Soccer	13	41.9	2	6.5
Running	0	0	6	19.4
Handball	6	19.4	0	0
Badminton	2	6.5	0	0
Trampoline	1	3.2	0	0
Gymnastics	1	3.2	0	0
Total	23	74.2	8	25.9

TABLE IV

Time between accident and arrival at emergency room in fifty-one patients with ruptured fibular ankle ligaments and in 645 patients with ankle sprains but without ligamentous damage.

Hours	With ligamentous injury				Without ligamentous injury	
	Males	Females	Males & Females		Males & Females	Per cent
			No.	Per cent		
0 - 3	14	10	24	47.1	291	45.1
4 - 6	10	8	18	35.3	270	41.9
7 - 9	0	3	3	5.9	64	9.9
10 - 12	0	5	5	9.8	7	1.1
13 - 36	1	0	1	2.0	13	2.0
Total	25	26	51	100.1	645	100.0

At clinical examination three weeks after injury weight-bearing of the injured foot was allowed, if the ankle movements were normal and without pain. Otherwise further non-weight-bearing was indicated followed by weekly clinical examination. Forty-two patients were treated for three weeks and nine for four weeks (mean twenty-two days).

All patients were advised not to participate in sport for five weeks.

RESULTS

On arrival at hospital all patients were asked whether weight-bearing on the injured foot was still possible after the accident. The answers are seen in Table V, where the term "possible" means that the injured foot could be used as in normal gait, but with slight pain, "limited" means that limping is marked on account of pain.

TABLE V

Possibility of using the injured foot from the time of accident to arrival at hospital in fifty-one patients with injured fibular ankle ligaments, and in 645 patients with ankle sprains but without ligamentous damage.

Use of foot	Injured				Uninjured	
	Males	Females	Males & Females	Per cent	Males & Females	Per cent
Possible	7	5	12	23.5	297	46.0
Limited	12	14	26	51.0	321	49.8
Impossible	6	7	13	25.5	27	4.2
Total	25	26	51	100.0	645	100.0

At the primary examination all patients had painful movements of the ankle, tenderness located around the lateral malleolus and swelling. Twelve patients (24%) had haematomatous discolouration of the skin at the fibular side of the foot beneath the malleolus.

Before X-Ray examination all patients had a provisional diagnosis of injury to the fibular ligaments of the ankle made on clinical grounds. At the primary clinical examination a positive anterior drawer test was present in fourteen patients (Table VI). Clinical positive talar tilt test was present in two females who also had a positive anterior drawer test (Table VII). The results of the primary radiological talar tilt examination are shown in Table VIII. The mean talar tilt difference (I-U) was eight degrees (range 6°-15°).

At follow-up eighteen months after the accident, all patients were questioned about residual symptoms, examined clinically, and X-Rays for anterior drawer sign and talar tilt were repeated (Table IX and X). The

TABLE VI

Clinical anterior drawer test at the time of accident in fifty-one patients with injured fibular ankle ligaments.

Clinical anterior drawer sign	Males	Females	Males & Females	Per cent
Absent	14	9	23	45.1
Doubtful	5	9	14	27.5
Present	6	8	14	27.5
Total	25	26	51	100.0

TABLE VII

Clinical talar tilt test at the time of accident in fifty-one patients with injured fibular ankle ligaments.

Clinical talar tilt	Males	Females	Males & Females	Per cent
Absent	21	21	42	82.4
Doubtful	4	3	7	13.7
Present	0	2	2	4.0
Total	25	26	51	100.0

TABLE VIII

Primary radiological talar tilt in fifty-one patients with injured fibular ankle ligaments. I = talar tilt of the injured foot. U = talar tilt of the uninjured foot.

(I - U)°	Males	Females	Males & Females	Per cent
6 - 7	15	19	34	66.7
8 - 10	8	6	14	27.5
> 10	2	1	3	5.9
Total	25	26	51	100.0

TABLE IX

Radiological talar tilt at follow-up in fifty-one patients with previous injured fibular ankle ligaments.

(I - U)°	Males	Females	Males & Females	Per cent
6	20	20	40	78.4
6 - 7	4	4	8	15.7
8 - 10	0	1	1	2.0
> 10	1	1	2	3.9
Total	25	26	51	100.0

mean radiological talar tilt difference (I-U) was three degrees (range 0°-17°); one boy, sixteen years old, had primarily a talar tilt difference (I-U) of fifteen degrees, but at follow-up his talar tilt difference (I-U) was seven-

TABLE X

Radiological drawer test (millimetre) at follow-up in fifty-one patients with previous injured fibular ankle ligaments.

Anterior drawer test mm	Males	Females	Males & Females	Per cent
0	14	17	31	60.8
1 - 3	7	5	12	23.5
> 3	4	4	8	15.7
Total	25	26	51	100.0

teen degrees, the drawer test five millimetres and the patient suffered from subjective instability in the ankle joint.

Eight out of fifty-one patients (16%) had residual symptoms (Table XI), the most serious being functional instability (FI) of the ankle joint. FI was defined as a feeling of insecurity in the ankle joint and tendency for the foot to "give way". The relations between primary talar tilt, secondary talar tilt, anterior drawer test and residual symptoms are shown in Table XII. The relations between arrival time at hospital, ability to use the injured foot before treatment and residual symptoms are seen in Table XIII.

TABLE XI

Residual symptoms in fifty-one patients with previously injured fibular ankle ligaments at follow-up 18 months after injury.

Residual symptoms	Males	Females	Males & Females	Per cent
None	22	21	43	84.3
Recurrent pain and swelling in the ankle	1	2	3	5.9
Functional instability	2	3	5	9.8
Total	25	26	51	100.0

None of the patients with residual symptoms consulted a doctor about further treatment. All patients went back to work without having inconvenient ankle problems. Among the eight patients with residual symptoms, four (numbers 1, 3, 7 and 8 in Table XII) sustained the ligamentous rupture during sport. Two of these were still active sportsmen at the same level as before the accident, while the remaining two gave up sport because of subjective FI. All of the patients without residual symptoms, who had the injury during sport, were still active. Two patients who had returned to competitive sport had a new sprain in the interval between treatment and follow-up. Both had no residual symptoms and were not correlating the new sprain with the

TABLE XII

Radiological primary talar tilt (I - U)°, secondary talar tilt (I - U)° and anterior drawer test in eight patients with residual symptoms after injury to the fibular ankle ligaments. FI = subjective functional instability. PS = recurrent pain and swelling in the ankle.

Patients	Age	Sex	Radiological talar tilt (I - U)°		Anterior drawer test mm.	Residual Symptoms
			Primary	Secondary		
1	43	Male	8	7	5	PS
2	15	Female	6	10	5	FI
3	18	Female	8	7	5	FI
4	20	Female	6	11	5	PS
5	29	Female	6	4	0	FI
6	32	Female	10	2	3	PS
7	16	Male	15	17	5	FI
8	19	Male	6	6	3	FI

TABLE XIII

Time of arrival at hospital and possibility of using the injured foot after the trauma but before treatment in eight patients with residual symptoms after injury to the fibular ankle ligaments.

Patients	Time from accident to arrival at hospital hours	Possibility of using the injured foot after accident to arrival at hospital	Residual Symptoms
2	8	Limited	FI
3	4	Impossible	FI
4	4	Limited	PS
5	11	Possible	FI
6	6	Possible	PS
7	1	Impossible	FI
8	1	Impossible	FI

previous injured fibular ankle ligaments. Both needed no treatment after the new sprain. At follow-up all patients were asked whether they were satisfied with the treatment. Eighty-nine per cent stated that the treatment was excellent, eleven per cent that it was good, thus none was dissatisfied.

DISCUSSION

Broström (1966) in a study of surgical versus conservative treatment of rupture to the fibular ankle ligaments, stressed that although surgical treatment gave the best long-term results, it could not be recommended for routine treatment. Three reasons were behind this statement: (1) The risk of post-operative infection and osteoarthritis, (2) discomfort from the scar such as altered sensibility and traumatic neuroma and (3) because secondary surgical repair, if necessary, can be

performed with good results even several years after the injury. He also pointed out that residual symptoms after non-surgical treatment are usually mild and not disabling, and that the duration of sick leave after operation is considerably longer than after conservative treatment.

Conservative treatment usually consists of immobilisation in plaster. Ruth (1961) found that fifty-eight per cent of the patients treated with plaster immobilisation for six weeks had persistent minor or major complaints two years later. Wiles (1959) stated that immobilised ankles remained stiff for long periods after exercises were started. Freeman (1965) and Niethard (1974) also found poor results after conservative treatment; as forty-four and fifty-five per cent respectively of the patients treated with plaster immobilisation had residual symptoms. Freeman (1965) concluded that early mobilisation could be recommended as the treatment of choice for most, perhaps all, ruptures of the fibular ligaments of the ankle.

Freeman (1965) in a study of physiotherapy versus immobilisation of injured lateral ligaments found that ligamentous injuries frequently produce a proprioceptive deficit affecting the muscles of the injured leg. He stressed that such a deficit could be responsible for the symptom of the foot "giving way". He also emphasised that the incidence of both the proprioceptive deficit and the symptom of "giving way" could be reduced substantially by early mobilisation and coordinating exercises.

Hansen et al (1979) in a follow-up of 144 patients treated with plaster for six weeks found that twenty-one per cent of the patients had residual symptoms. FI was present in eighteen per cent. Four patients reported major complaints having weekly episodes of "sprains", and one developed reflex dystrophy.

Clark et al (1965) found no difference between conservative and operative treatment, but concluded that, in young patients with severe damage of the fibular ankle ligaments (unilateral talar tilt exceeding fifteen degrees), surgery is to be preferred to plaster immobilisation.

Termansen et al (1979) emphasised that there was no correlation between roentgenological instability and residual symptoms. He found that nineteen per cent of the patients treated with plaster immobilisation had secondary radiological instability in the ankle joint. Residual symptoms, in 144 patients with previous fibular ligamentous injury, were present in twenty-one per cent.

Niedermann et al (1981) in a prospective study on operative as compared with conservative treatment, emphasised that there was no difference between the

two groups. Seventy-six per cent of the patients treated by plaster immobilisation for five weeks obtained good results.

In the present study 15.7 per cent had residual symptoms. Five patients had subjective functional instability in the ankle joint. None needed further treatment and all went back to work without ankle problems. These results are better than those seen in previous publications on conservative treatment of injury to the fibular ankle ligaments (Adler, 1976; Broström, 1966; Deplace et al, 1975; Freeman et al, 1965; Gross and McIntosh, 1973; Russe, 1967; Staples, 1972; Tonino, 1973).

It might be assumed that patients with less serious ankle sprains would wait longer before seeking medical care than those with severe damage. This point of view could not be verified in the present study. Consequently a severe ligamentous lesion is still a possibility in patients arriving "late" to the emergency room, and so lateness does not justify omission of adequate examination and treatment.

One of the aspects in ankle sprains that might suggest a severe injury is the post traumatic dysfunction of the joint, which is reflected in the inability to use the injured foot fully after the accident. Seventy-seven per cent of the patients with ligamentous injury had marked difficulties in walking after the accident, while fifty-four per cent of the patients with ankle sprains but without ligamentous injury had the same difficulties. Among all the patients – with and without ligamentous injury – who had marked problems in using the injured foot after injury, the statistical probability of having a ligamentous rupture could be estimated at 0.1. So the ability to use the injured foot after a sprain is a poor diagnostic criterion, which is not applicable in the diagnosis of ligamentous injury.

The treatment described in this study was based on the presumption that a partial nerve de-afferentation is caused by the ligamentous injury. The consequent proprioceptive nerve deficit might be compensated by a central process, but only if movements are taking place in the talo-tibial joint. By these movements the proprioceptive deficit might be momentary, and accordingly the risk of subjective functional instability should diminish.

The results support the suggestion that early mobilisation does have a positive influence on the risk of subjective functional instability in the ankle joint. Because FI is far the most serious residual symptom, there is in my opinion no doubt that early mobilisation following ligamentous ankle injury deserves a much higher priority than is usually observed.

Among sportsmen sustaining a ligamentous ankle

injury, it is of the utmost importance to have treatment which leads to a quick return to sport at the same level as before the accident. Plaster immobilisation and especially operative treatment both make a very large

break in the training programme. The treatment carried out in this series gives a very quick return to sport and furthermore diminishes the risk of subjective functional instability in the ankle joint.

REFERENCES

- Adler, H., 1976 "Therapie und Prognose der frischen Aussenknöchelbandläsion". *Unfallheilkunde* 79: 101-104.
- Anderson, K. J. and Lecocq, J. F., 1954 "Operative treatment of injury to the fibular collateral ligament of the ankle". *J.Bone Jt.Surg.(Am.)* 36: 825-832.
- Broström, L., 1966 "Sprained ankles. Treatment and prognosis in recent ligament ruptures". *Acta Chir.Scand.* 132: 537-550.
- Clark, B. L., Derby, A. C. and Power, G. R. J., 1965 "Injuries of the lateral ligament of the ankle. Conservative vs. operative repair". *Can.J.Surg.* 8: 358-363.
- Delplace, J., Flocoud, D. and Castaing, J., 1975 "Résultat a propos de 83 cas observés la service des Urgences du CHR de tours". 61 (suppl. 2): 146-153.
- Duquenois, A., Lisélé, D. and Torabi, D. J., 1975 "Résultat du traitement chirurgical de la rupture du ligament latéral externe de la cheville". *Rev.Chir.Orthop.* 61: 159-162.
- Dziob, J. H., 1956 "Ligamentous injuries about the ankle joint". *Am.J.Surg.* 91: 692-698.
- Freeman, M. A. R., Dean, M. R. E. and Hanham, I. W. D., 1965 "The etiology and prevention of functional instability of the foot". *J.Bone Jt.Surg.* 47 B: 678-685.
- Freeman, M. A. R., 1965 "Treatment of ruptures of the lateral ligament of the ankle". *J.Bone Jt.Surg.(Br.)* 47 B: 661-668.
- Gross, A. E. and McIntosh, D. L., 1973 "Injury to the lateral ligament of the ankle: A clinical study". *Can.J.Surg.* 16: 115-117.
- Hansen, H., Damholt, V. and Termansen, N. B., 1979 "Clinical and social status following injury to the lateral ligaments of the ankle". *Acta Orthop.Scand.* 50: 699-704.
- Niedermann, B., Andersen, A., Bryde-Andersen, S., Funder, V., Jørgensen, J. P., Lindholmer, E. and Vuust, M., 1981 "Rupture of the lateral ligaments of the ankle: Operation or plaster cast?" *Acta Orthop.Scand.* 52: 579-587.
- Niethard, F. V., 1974 "Die stabilität des sprunggelenkes nach ruptur des lateralen bandapparates". *Arch orthop.Unfall-Chir.* 80: 53-61.
- Russe, O., 1967 "Subluxatio tali supinatoria". *Z.Unfallheilk* 92: 104-107.
- Ruth, C. J., 1961 "The surgical treatment of injuries of the fibular collateral ligaments of the ankle". *J.Bone Jt.Surg.(Am.)* 43 A: 229-240.
- Staples, O. S., 1972 "Result study of ruptures of the lateral ligaments of the ankle". *Clin.Orthop.* 85: 50-58.
- Termansen, N. B., Hansen, H. and Damholt, V., 1979 "Radiological and muscular status following injury to the lateral ligaments of the ankle". *Acta Orthop.Scand.* 50: 705-708.
- Tonino, A. J., 1973 "Treatment of partial ruptures of the lateral ligament of the ankle in acute ankle sprains". *Arch. Chir.Neerl.* 25: 119-129.
- Wiles, P., 1959 "Essentials of orthopaedics". Third edition, J. and A. Churchill Ltd., 303.