

## PNEUMOTHORAX IN AN ATHLETE

V. B. E. CHESTER, MB\* and M. MURPHY, MB\*\*

\*Medical House Officer, Bantry County Hospital, Bantry, Co. Cork

\*\*Medical Practitioner, Gurteenroe, Bantry, Co. Cork

### INTRODUCTION

We would like to report an interesting case of pneumothorax in a twenty-four year old man, presenting to a casualty department diagnosed as strained inter-costal muscles.

### CASE REPORT

This man exercised vigorously every day bar one in the last year and a half, often running fifteen miles at a time, and capable of ninety-four press-ups in one minute. While representing his firm in a Superstars competition, he was required to perform a maximum number of chin-ups while hanging from an overhead bar. After completing the twentieth, and final repetition he experienced left anterior chest pain. Initially present only while jogging, the pain then began to manifest itself during rest, and deteriorated into a nagging dull pain in his left side and arm that was now associated with tachypnoea. He reported to the casualty department of a nearby hospital, and was told he had "pulled"

an inter-costal muscle.

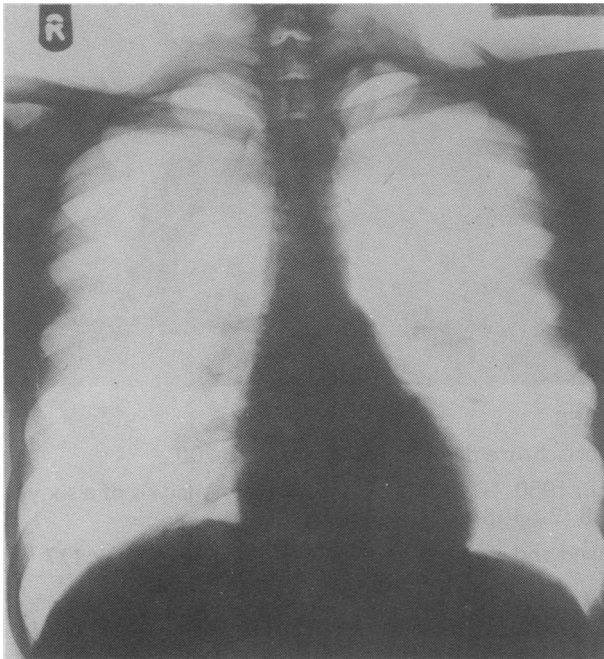
Although he now complained only of mild unilateral chest discomfort, two days later he went to his own general practitioner, who diagnosed left-sided pneumothorax. Complete left sided pneumothorax was seen on X-ray.

### COMMENT

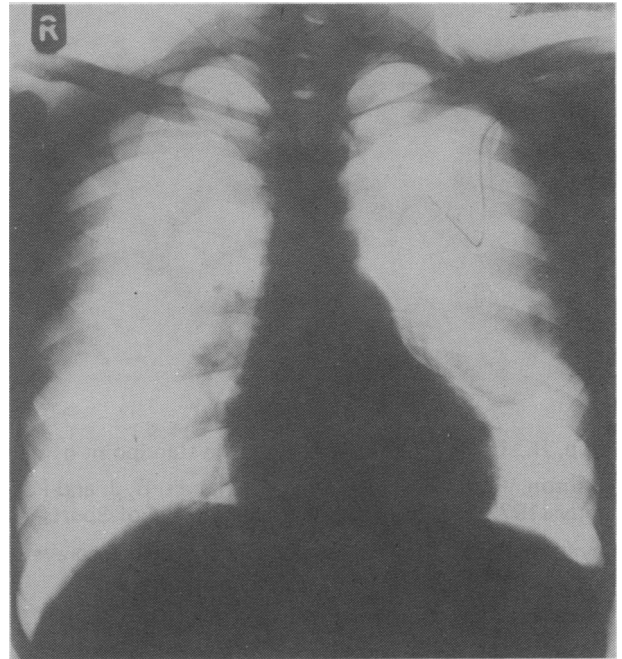
It is of interest that the patient although capable of ninety-four press-ups in one minute, had never attempted a maximum number of repetitions of this exercise. Hence, the intensity of the Valsalva manoeuvre performed during the twentieth chin-up had never been required before, even for his ninety-fourth press-up.

It is also of interest that complete left pneumothorax may persist causing few symptoms.

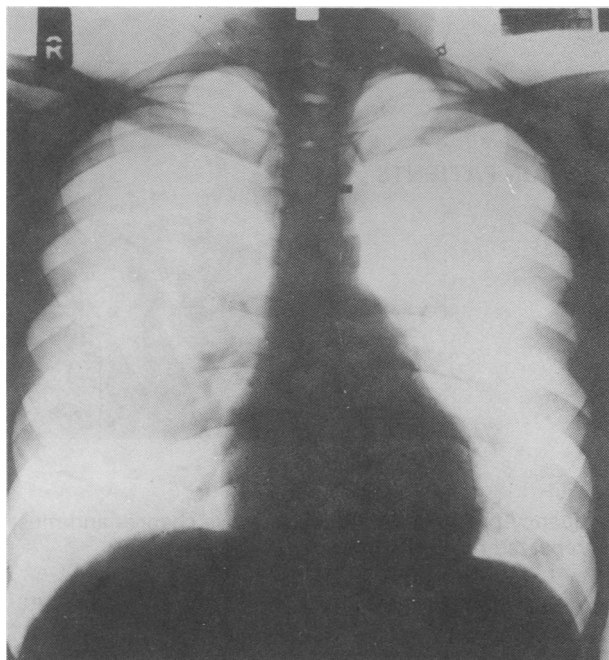
An underwater seal was inserted, and the patient made an uneventful recovery.



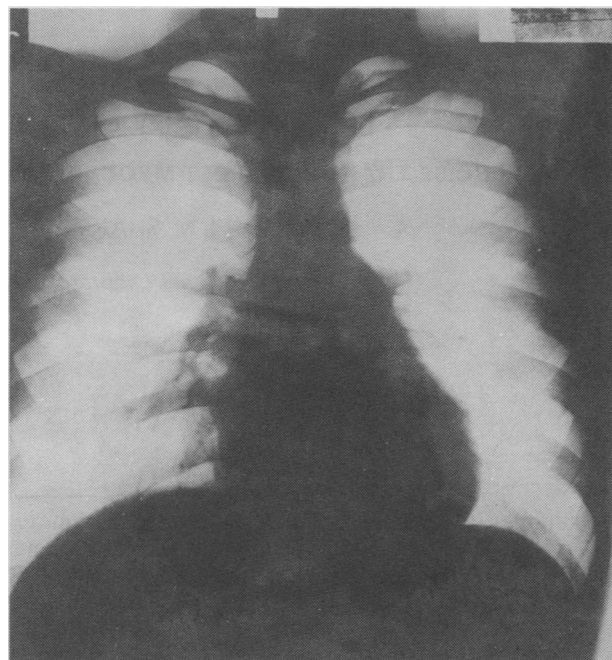
*Chest X-ray on admission — complete left pneumothorax.*



*Chest X-ray when underwater seal has been in position for 2 days.*



*Chest X-ray on discharge from hospital.*



*Chest X-ray at outpatients showing complete resolution of pneumothorax.*

---

#### CORRESPONDENCE

University of Essex,  
Wivenhoe Park,  
Colchester CO4 3SQ

*To the Editor:*

*Dear Sir,*

#### SAFETY IN EXERCISE

As the Chairman of the working party responsible for drawing up a manual on "Safety in Sport" for use in British Universities may I add my support to the comments expressed in the September 1982 issue by D. H. Williams.

What we have been endeavouring to inculcate in British Universities is positive guidance through structured teaching and instruction.

Students at Universities — as at other establishments of Higher Education — are involved in many high-risk activities such as trampolining, mountaineering, hang-gliding, canoeing, etc. They are encouraged to participate, but the basic safety elements are always paramount, without wishing to eliminate the small risk factor which is an important facet to the learner and advanced performer alike.

If the dangerous elements are totally removed, the activity may become sterile, boring and lacking in appeal.

Let us, therefore, retain a risk factor but prepare — safely and thoroughly — the sportsmen and women before they embark on any potentially hazardous activity.

Yours sincerely,

A. F. Rustage, BA, DPE  
Chairman of the British Universities  
Physical Education Association