Electrocardiographic changes in 1000 highly trained junior elite athletes

Sanjay Sharma, Greg Whyte, Perry Elliott, Mina Padula, Rashmi Kaushal, Niall Mahon, William J McKenna

Abstract

***Objectives*—To evaluate the spectrum of electrocardiographic (ECG) changes in 1000 junior (18 or under) elite athletes.**

***Methods*—A total of 1000 (73% male) junior elite athletes (mean (SD) age 15.7 (1.4) years (range 14–18); mean (SD) body surface area 1.73 (0.17) m^2 (range 1.09–2.25)) and 300 non-athletic controls matched for gender, age, and body surface area had a 12 lead ECG examination.**

***Results*—Athletes had a significantly higher prevalence of sinus bradycardia (80% *v* 19%; p<0.0001) and sinus arrhythmia (52% *v* 9%; p<0.0001) than non-athletes. The PR interval, QRS, and QT duration were more prolonged in athletes than non-athletes (153 (20) *v* 140 (18) milliseconds (p<0.0001), 92 (12) *v* 89 (7) milliseconds (p<0.0001), and 391 (27) *v* 379 (29) milliseconds (p = 0.002) respectively). The Sokolow voltage criterion for left ventricular hypertrophy (LVH) and the Romhilt-Estes points score for LVH was more common in athletes (45% *v* 23% (p<0.0001) and 10% *v* 0% (p<0.0001) respectively), as were criteria for left and right atrial enlargement (14% *v* 1.2% and 16% *v* 2% respectively). None of the athletes with voltage criteria for LVH had left axis deviation, ST segment depression, deep T wave inversion, or pathological Q waves. ST segment elevation was more common in athletes than non-athletes (43% *v* 24%; p<0.0001). Minor T wave inversion (less than −0.2 mV) in V2 and V3 was present in 4% of athletes and non-athletes. Minor T wave inversion elsewhere was absent in non-athletes and present in 0.4% of athletes.**

***Conclusions*—ECG changes in junior elite athletes are not dissimilar to those in senior athletes. Isolated Sokolow voltage criterion for LVH is common; however, associated abnormalities that indicate pathological hypertrophy are absent. Minor T wave inversions in leads other than V2 and V3 may be present in athletes and non-athletes less than 16 but should be an indication for further investigation in older athletes.**

(*Br J Sports Med* 1999;**33**:319–324)

Keywords: junior; elite; athlete; ECG; heart

St George's Hospital Medical School, Cranmer Terrace, London SW17 ORE, United Kingdom
S Sharma
P Elliott
R Kaushal
N Mahon
W J McKenna

University of Wolverhampton, Division of Sports Studies, Walsall Campus, Gorway Road, Walsall, United Kingdom
G Whyte

University Gabriele D' Annunzio, Chieti, Italy
M Padula

Correspondence to:
S Sharma.

Accepted for publication
15 April 1999

Regular intensive exercise training is associated with structural and functional changes in the heart which are reflected on the surface 12 lead electrocardiogram (ECG).[1–3] Such changes may simulate cardiac disease causing concern to attending physicians and sporting bodies because most non-traumatic sudden deaths in young athletes are due to inherited cardiovascular disorders.[4 5] Although the incidence of sudden death in athletes from these disorders is rare, the steady trickle of reports of such events has led many sporting organisations to implement mandatory cardiovascular screening in all junior participants (18 and under) before acceptance for competition.[6] Cost issues may limit screening programmes to the medical history, cardiovascular examination, and 12 lead ECG, with more expensive yet definitive tests such as echocardiography being reserved for those with symptoms suggestive of cardiovascular disease, a positive family history of premature sudden cardiac death, and ECG changes thought to be abnormal. Whereas there is a significant amount of information on ECG changes in senior athletes, there is a conspicuous lack of data on ECG changes in junior athletes in whom sudden death is more prevalent.[6] The aim of this study was to characterise ECG changes in junior athletes.

Methods

ATHLETES

Between April 1995 and November 1998, 1000 postpubertal junior elite athletes aged 15.7 (1.4) years (range 14–18) had a 12 lead ECG examination as part of a screening programme to identify unsuspected cardiovascular disease in young athletes. Written consent was obtained from subjects aged 16 or over and from a parent/guardian of those under 16. Criteria for puberty were breast development, growth of pubic hair, or onset of menstruation in girls, and growth of pubic hair or voice changes in boys. In total, 730 (73%) of the athletes were male. The mean (SD) body surface area was 1.73 (0.17) m^2 (range 1.09–2.25). The vast majority of athletes (988) were white, eight were of Afrocarribean origin, and four were of Asian origin. Athletes from nine sporting disciplines were assessed: soccer, tennis, rugby, cycling, swimming, athletics, boxing, rowing, and modern triathlon. Soccer players were recruited from youth teams in the British Premier Soccer League, tennis players from the British Lawn Tennis Association, rugby players from county youth teams, swimmers and rowers from the junior national squad, cyclists from two large county cycling squads, boxers from elite amateur boxing clubs, athletes participating in athletics from elite county squads, and triathletes from the top ten positions at the National UK champi-

Br J Sports Med: first published as 10.1136/bjsm.33.5.319 on 1 October 1999. Downloaded from http://bjsm.bmj.com/ on October 26, 2021 by guest. Protected by copyright.

Table 1 Data on the sporting disciplines of the athletes

Sport	*Total*	*%*	*Age (years)*	*Body surface area (m^2)*
Tennis	233	23.3	15.4 (1.1)	1.70 (1.1)
Football	310	31	16.0 (1.2)	1.76 (1.2)
Rugby	102	10.2	15.7 (0.6)	1.80 (0.2)
Cycling	100	10	15.6 (1.2)	1.73 (0.17)
Swimming	72	7.2	15.5 (0.9)	1.71 (0.14)
Athletics	60	6	16.6 (1.1)	1.71 (0.8)
Boxing	50	5	15.8 (1.1)	1.72 (0.6)
Rowing	43	4.3	16.6 (0.6)	1.88 (0.18)
Triathlon	30	3	16.6 (1.1)	1.70 (1.29)

Results are mean (SD).

onships in 1997 (table 1). All athletes had competed at county level or equivalent for 4.2 (1.7) years (range 1–10) and 44% had competed at national level less than six months before cardiovascular evaluation. The number of hours of intensive training including competitive participation was determined by a questionnaire and ranged from five to 23 hours a week (mean (SD) 9.7 (3.3) hours a week). None of the athletes had symptoms of underlying cardiovascular disease or a family history of premature death from cardiovascular disease, and no athlete was taking any form of medication.

CONTROLS

The control group comprised 300 healthy postpubertal asymptomatic volunteers who were students at a large secondary education boarding school. All subjects had a relatively sedentary life style, arbitrarily defined as less than two hours of physical exercise a week. The control group was matched for age (15.6 (1.3) years; range 14–18), gender (70% boys, 30% girls) and body surface area (1.71 (0.2) m^2; range 1.17–2.24). The vast majority (293) were white, four were of Afrocarribean origin, and three were of Asian origin. Like the athletes, none of the non-athletic group had symptoms of underlying cardiovascular disease or a family history of premature death from cardiovascular disease, and none were taking any form of medication.

Table 2 Electrocardiographic results

	Athletes (n=1000)	*Non-athletes (n=300)*	*p Value*
Sinus bradycardia (heart rate <60 bpm) (%)	80	19	<0.0001
Sinus arrhythmia (%)	52	9	<0.0001
Nodal rhythm (%)	0.4	0	NS
Wandering pacemaker (%)	0.2	0	NS
First degree AV block (%)	5	0	<0.001
Second degree AV block (%)			
Mobitz type 1	0.2	0	NS
PR interval (milliseconds)	153 (20) (100–240)	140 (18) (100–187)	<0.0001
QRS duration (milliseconds)	92 (12) (54–129)	89 (7) (70–114)	<0.0001
Incomplete RBBB (%)	29	11	<0.0001
Complete RBBB (%)	0.6	0	NS
QRS axis (degrees)	77 (18) (−21 to +123)	72 (19) (−1 to +100)	NS
QT_c (milliseconds)	391 (27) (346–478)	379 (29) (314–440)	0.002
LA enlargement (%)	14	1.2	<0.0001
RA enlargement (%)	16	2.0	<0.0001
Sokolow criterion for LVH (%)	45	23	<0.0001
Romhilt-Estes criterion for LVH (%)	10	0	<0.0001
Sokolow criterion for RVH (%)	12	10	NS
ST elevation (%)	43	24	<0.0001
Tall T waves (%)	22	6	<0.0001
Pathological Q waves	0	0	NS

Where applicable, results are mean (SD) with the range in parentheses. AV, atrioventricular; LA, left atrial; LVH, left ventricular hypertrophy; RVH, right ventricular hypertrophy; RA, right atrial; RBBB, right bundle branch block.

PHYSICAL EXAMINATION

Examination of the cardiovascular system was performed by an experienced cardiologist (SS) in a quiet room with the subject lying recumbent at 45°. The heart rate was measured using the radial pulse. The blood pressure was measured at the brachial artery using a correctly fitting blood pressure cuff. Auscultation of the heart was performed with the subject lying and standing upright.

ECG

A standard 12 lead ECG examination was performed during quiet respiration in a supine position and analysed using a Marquette Hellige (Milwaukee, Wisconsin, USA) ECG recorder. The electrodes were placed carefully to ensure consistency of the precordial lead locations, and ECGs were recorded at a paper speed of 25 mm/s. PR interval, QRS duration, QT interval, QRS axis, Q, R, S, and T wave voltage, and ST segments were measured in each lead using calipers and a millimetre ruler as described elsewhere.[7] P wave voltage was measured in lead V1 alone. Left axis deviation was defined as a QRS axis more negative than −30°, and right axis deviation was defined as a QRS axis more positive than +120°. The QT intervals were corrected for the heart rate (QT_c) using Bazett's formula.[8] A QT_c interval was considered abnormally prolonged if longer than 460 milliseconds in all subjects aged 15 and below, and longer than 450 milliseconds in boys and longer than 460 milliseconds in girls aged over 15.[9] Right atrial enlargement was defined as a P wave voltage of 0.25 mV or above.[10] Left atrial enlargement was defined as a biphasic P wave in V1 where the terminal portion was more negative than −0.1 mV and 0.04 seconds or more in duration.[10] Left and right ventricular hypertrophy (LVH and RVH) were defined by the Sokolow-Lyon voltage criterion.[11 12] LVH was defined by the sum of the S waves in V1 and the R waves in V5 exceeding 3.5 mV.[11] RVH was defined by the sum of the R waves in V1 and the S waves in V6 exceeding 1.05 mV.[12] The presence of LVH was also assessed by the Romhilt-Estes points score system,[13] with a score of 5 or more being used to define LVH. A Q wave was considered abnormal or pathological if it exceeded 0.04 seconds in duration and/or if the depth of the Q wave exceeded 25% of the height of the R wave.

STATISTICAL ANALYSIS

Data are expressed as mean (SD). Statistical analysis was performed using unpaired Student's *t* test and analysis of variance where appropriate. A probability value (p) of less than 0.05 was considered significant.

Results

PHYSICAL EXAMINATION

A proportion of athletes and non-athletes had a systolic murmur, which was present when they lay flat but absent when they were standing upright. However, no subject was thought to have a murmur indicating valvular or structural heart disease. None of the subjects in the study had a systolic blood pressure exceeding 140 mm Hg or a diastolic blood pressure exceeding 90 mm Hg.

Br J Sports Med: first published as 10.1136/bjsm.33.5.319 on 1 October 1999. Downloaded from http://bjsm.bmj.com/ on October 26, 2021 by guest. Protected by copyright.

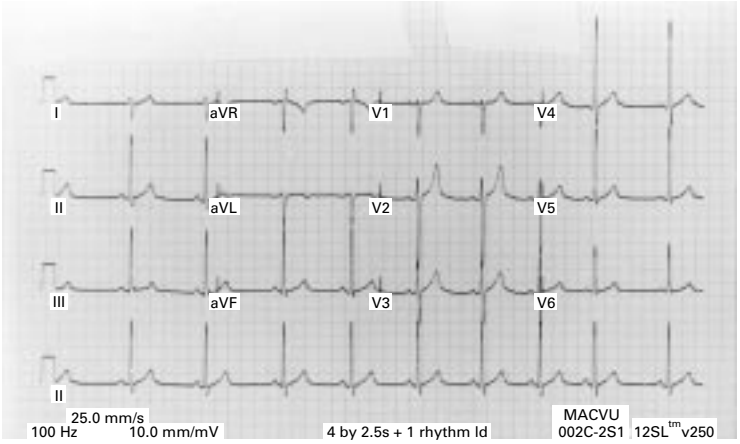

Figure 1 Electrocardiograph changes in an elite soccer player from a British Premier League club showing sinus bradycardia, sinus arrhythmia, and Sokolow voltage criterion for left ventricular hypertrophy typical of that seen in most of the athletes in this study. In addition, there is right axis deviation and tall T waves.

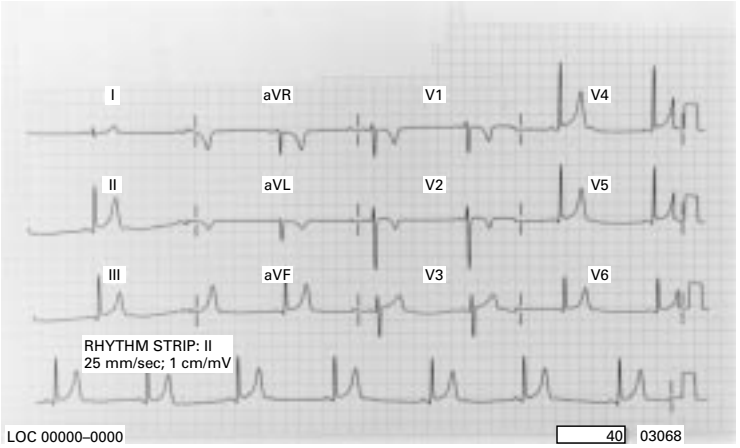

Figure 2 Electrocardiogram showing sinus bradycardia, ST segment elevation, and T wave inversions in leads V2 and V3 in an elite junior male cyclist aged 15. The frequency of T wave inversions in leads V2 and V3 was 4% in both athletes and non-athletes aged less than 16 but no subject aged over 16 had similar T wave inversions.

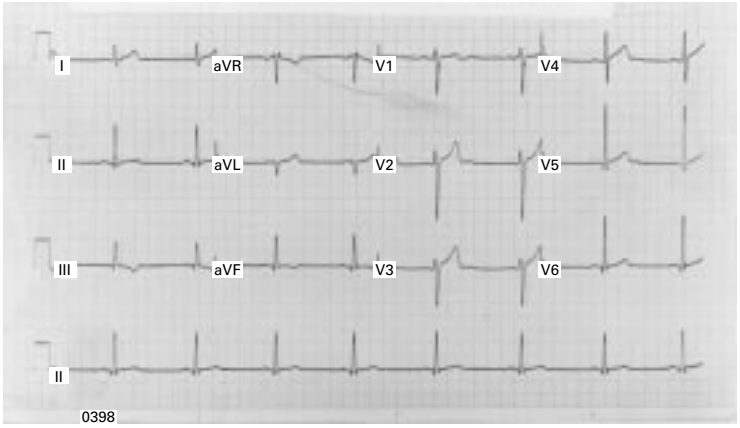

Figure 3 Electrocardiogram showing sinus bradycardia and minor T wave inversions (less negative than −0.2 mV) in the inferior leads in a 17 year old junior national rower who subsequently had a normal echocardiogram. Only 0.4% of all junior athletes had T wave inversions other than in V2 and V3.

ECG RESULTS (TABLE 2)

All non-athletes were in sinus rhythm and none had any form of atrioventricular block. Compared with non-athletes, the athletes had a higher prevalence of sinus bradycardia and sinus arrhythmia (fig 1). Fifty three athletes (5.3%) had first degree atrioventricular block, two had nodal bradycardia, one had a wandering atrial pacemaker, and one had Mobitz type 1 second degree atrioventricular block. None of the athletes had a higher degree of atrioventricular block than Mobitz type 1 second degree. In athletes without first degree atrioventricular block, the PR interval was more prolonged than in the non-athletic group.

The mean QRS axis was similar in athletes and non-athletes, but right axis deviation was more common in athletes than non-athletes (16% *v* 6%; $p<0.001$) (fig 1). No subject in the study had left axis deviation. Athletes had a more prolonged QRS duration and QT_c than non-athletes. The QT_c was normal (<450 milliseconds) in all subjects in this study except for three athletes (one boy and two girls aged 15 or older) in whom QT_c prolongation of 452, 458, and 460 milliseconds respectively was an isolated finding—that is, none of these athletes had cardiovascular symptoms or a family history of cardiovascular disease, unexplained syncope, and sudden death—and therefore were not considered to have a long QT syndrome.

No subject in the study had evidence of ST segment depression. Repolarisation changes comprising minor ST segment elevation (<0.2 mV) and peaked T waves (>1.0 mV) were more common in athletes than non-athletes. Minor T wave inversion (<−0.2 mV) in leads V2 and V3 was present in 4% of athletes and controls younger than 16 (fig 2). No subject in the control group had T wave inversion in the inferior or lateral leads. Four athletes had minor T wave inversion (<−0.2 mV) in leads III and aVF but none had inverted T waves in leads I, II, aVL and V4–V6 (fig 3).

Partial right bundle branch block (RBBB) (RBBB pattern with a QRS duration of less than 120 milliseconds), voltage criteria for left and right atrial enlargement, and Sokolow-Lyon and Romhilt-Estes criteria voltage criteria for LVH were more common in athletes than in the non-athlete group and more common in male athletes than female athletes. Only 1.2% of athletes had complete RBBB (RBBB with a QRS duration of more than 120 milliseconds). The frequency with which this was present in athletes and non-athletes was not significantly different. No subject in this study had either partial or complete left bundle branch block (LBBB). None of the girls had a Romhilt-Estes criterion for LVH. Only 5% of female athletes had a Sokolow-Lyon criterion for LVH. There was no difference in the prevalence of voltage criteria for RVH between the athletes and non-athletes. No subject in this study had pathological Q waves.

Discussion

Bradycardia, sinus arrhythmia, and voltage criteria for cardiac chamber enlargement were common (fig 1) and present with the same frequency as previously shown in senior athletes.[14–16] Experience from studies on senior athletes indicates that these changes reflect increased vagal tone and increased cardiac size. Although the Sokolow voltage criterion was

Br J Sports Med: first published as 10.1136/bjsm.33.5.319 on 1 October 1999. Downloaded from http://bjsm.bmj.com/ on October 26, 2021 by guest. Protected by copyright.

significantly more common in athletes, it was also present in 23% of non-athletes, indicating that it is probably a poor indicator of LVH in the young. Factors such as chest wall shape and size are also important determinants of the magnitude of voltage complexes on the surface ECG and were probably responsible for the high prevalence of the Sokolow voltage criterion for LVH in non-athletes, because most subjects in this study were slim and had a relatively thin chest wall. Many more athletes than non-athletes had the Sokolow-Lyon ECG voltage criterion for LVH. Although the two groups had similar body surface area, there may have been differences in chest wall morphology between the two groups, with the increased magnitude of QRS complexes in athletes being secondary to reduced chest wall fat rather than an increase in left ventricular wall thickness or left ventricular mass. However, it is also possible that the effects of the reduced chest wall fat in athletes may have been negated by a relative increase in chest wall bulk major muscle. Few studies have correlated ECG and echocardiographic criteria for LVH, but they have generally shown that the Sokolow voltage criterion for LVH correlates poorly with echocardiographic LVH[17 18]; however, more stringent criteria such as the Romhilt-Estes points score give a better correlation with echo parameters.[18] In this study, 10% of all athletes fulfilled the Romhilt-Estes points score for LVH, in contrast with the non-athletes, none of whom had a points score of over 5, and therefore one could speculate that the greater magnitude of precordial QRS complexes between athletes and non-athletes may be partly explained by a relative increase in left ventricular wall thickness, cavity size, or mass, at least in some athletes.

A pre-participating screening programme should not have resulted in many such athletes being unnecessarily referred for further cardiac assessment to exclude pathological LVH, for example, hypertrophic cardiomyopathy (HCM). The ECG changes had distinctive features to differentiate them from those commonly seen in patients with HCM. Although the Sokolow-Lyon voltage criterion for LVH is common in HCM, it is rare for it to occur in isolation—that is, without associated ST segment depression, deep T wave inversion, left axis deviation, or pathological Q waves. No athlete with Sokolow-Lyon voltage criterion for LVH in this study had any of the other associated abnormalities mentioned above to indicate pathological hypertrophy.[19 20] Although a few male athletes fulfilled the Romhilt-Estes points score for LVH, no female athlete in this group had a Romhilt-Estes points score of 5 or more, indicating that such ECG changes in female athletes are rare and may warrant further evaluation to exclude an underlying HCM.

Incomplete RBBB was more common in athletes than non-athletes, but there was no difference in the prevalence of the Sokolow voltage criterion for RVH. The most likely explanation for the latter is that a significant proportion of athletes and non-athletes were younger than 16, and in such subjects a voltage criterion for RVH is common. However, the increased prevalence of an rSr complex in V1, commonly termed partial RBBB, in athletes is probably representative of a genuine increase in right ventricular cavity size compared with non-athletes.[21] This hypothesis is supported by an increased frequency of right axis deviation in athletes compared with non-athletes.

Summary box 1: common ECG patterns in junior elite athletes

- Sinus bradycardia (heart rate < 60 beats/min) and sinus arrhythmia are common (80% and 52% respectively).
- First degree atrioventricular block is present in 5% but higher degrees of atrioventricular block are rare.
- Partial RBBB is present in almost one third of athletes.
- Isolated Sokolow voltage criterion for LVH is present in almost half of all athletes.
- ST segment elevation and tall T waves are present in 45% and 22% respectively.
- Voltage criteria for left and right atrial enlargement are present in 14 and 16% respectively.

Repolarisation changes including ST elevation and tall T waves which may occur in HCM were also present in many athletes. However, unlike the ECG in HCM, such changes were seen in isolation, and, in particular, no athlete had deep T wave inversion (exceeding −0.2 mV) in any lead, suggesting that subjects with such abnormalities require further investigation to exclude underlying cardiac pathology. Four athletes had minor T wave inversion (<−0.2 mV), which was confined to the inferior limb leads and reverted to an upright position after slight exercise (fig 3). The significance of these minor T wave changes is unclear, particularly as all four were subsequently investigated further with echocardiography and cardiopulmonary exercise testing, which was normal. Similar T wave changes (inversion in limb leads) which revert to normal with exercise have been documented in a small number of elite senior athletes, who were subsequently extensively investigated and found to show no evidence of cardiac disease. These changes were therefore attributed to a benign ECG phenomenon resulting from increased vagal tone.[22] However, it could be argued that the fact that they were present in only 0.4% of all elite athletes and are a common finding in patients with cardiomyopathy indicates that they may have a pathological basis and should always be investigated before they are attributed to increased vagal tone. Some 4% of athletes and non-athletes, all of whom were less than 16, had minor T wave inversion (<−0.2 mV) in leads V2 and V3 (fig 2). Such abnormalities are common in the ECGs of children younger than 16, but, if such a pattern persists, this may be an ECG manifestation of arrhythmogenic right ventricular cardiomyopathy, a condition characterised by fibrofatty replacement of myocardial tissue and a predisposition to ventricular arrhythmias and

Br J Sports Med: first published as 10.1136/bjsm.33.5.319 on 1 October 1999. Downloaded from http://bjsm.bmj.com/ on October 26, 2021 by guest. Protected by copyright.

sudden death.[23] In Northern Italy, arrhythmogenic right ventricular cardiomyopathy has been shown to cause more sudden cardiac death in young athletes than any other cardiovascular condition.[24] However, none of the athletes with T wave inversion in V2 and V3 had other ECG manifestations of arrhythmogenic right ventricular cardiomyopathy, such as frequent ventricular ectopics with LBBB morphology and epsilon waves.[25] ST segment depression has been documented in a few ECG studies in senior athletes, but was absent in all subjects in this study.[26–28] The reason for this remains unclear, but its absence in 1000 athletes means it cannot be accepted as part of the normal spectrum of ECG changes in junior athletes until cardiac pathology has been excluded by further investigation.

CLINICAL APPLICATIONS

Regular physical training in junior athletes is associated with a high prevalence of bradycardia, repolarisation, and voltage criteria for atrial enlargement and ventricular hypertrophy. The prevalence of these changes are not dissimilar to those seen in senior athletes. This study provides a comprehensive account of the spectrum of ECG patterns in predominantly white junior athletes and should prove useful to the physician in distinguishing athlete's heart from the pathological state. Findings from this study suggest that isolated Sokolow voltage criterion for LVH, ST segment elevation, and peaked T waves are common and do not require further investigation in an asymptomatic athlete without a family history of premature cardiovascular disease. Pathological Q waves, LBBB, depression of the ST segment, T wave inversion exceeding −0.2 mV in leads V2 and V3 in subjects under 16 years of age, any T wave inversion in leads V2 and V3 in athletes older than 16, any T wave inversion in leads V4–V6 and lateral leads in athletes older than 14, left axis deviation, and female athletes with a Romhilt-Estes points score of 5 or more (even in the absence of ST segment depession or T wave inversion) were absent in this cohort of elite athletes. One can speculate that the presence of these abnormalities may represent ECG markers of underlying cardiac pathology, particularly cardiomyopathy, which should be investigated before further competition is allowed. Minor T wave inversions in the inferior leads were present in 0.4% of all athletes. These may represent part of the spectrum resulting from cardiovascular adaptation to intensive training; however, they are common, and cardiovascular pathology should be excluded before competitive sport is continued. It should be emphasised that the vast majority of athletes studied were white, and therefore the findings from this study should be used with caution when athletes of Afrocarribean, Oriental, or Asian origin are evaluated.

The aim of this study was purely to characterise the spectrum of ECG changes in highly trained junior athletes. Although the ECGs were performed as part of a screening programme for cardiovascular disease in young athletes, the study was not designed to validate the role of the ECG as a screening tool for cardiovascular disorders in young athletes. Had we used the ECG solely as a screening tool, then only four athletes (those with T wave inversions in the inferior leads) had ECG changes commonly observed in patients with cardiomyopathy. None of the four athletes with T wave inversions had an abnormal echocardiogram to indicate cardiomyopathy, therefore the false positive rate of the ECG as a screening tool to identify subjects with underlying cardiomyopathy would have been 0.4%. Without echocardiography in every subject it is impossible to comment on the false negative rate; however, our experience from the large database of patients with cardiomyopathy at our clinic suggests that a normal 12 lead ECG recording or an ECG showing tall T waves, ST segment elevation, or Sokolow voltage criterion in isolation is unusual in such patients and we would not recommend further investigation in these cases unless the subject was symptomatic or had a family history of premature cardiovascular disease or sudden cardiac death. The high overall negative pick up rate for cardiovascular abnormalities in this study of 1000 athletes is not surprising when one considers that the prevalence of conditions predisposing to sudden death in young athletes is low. For example, HCM, which is the commonest cause of sudden cardiac death in athletes, has a prevalence of 1 in 500 in the general asymptomatic population, whereas arrhythmogenic right ventricular cardiomyopathy is 20 times less common. The prevalence of these conditions is probably still lower in a self selected population of elite athletes, and therefore several thousand athletes would have to be studied to validate the role of the ECG as a screening tool. This does not preclude ECG screening in a symptomatic athlete or athletes with a family history of premature sudden cardiac death where the pick up rate may be higher. The test is relatively cheap, quick, simple, and would certainly be more effective than physical examination alone in identifying subjects with cardiac pathology.

Summary box 2: ECG abnormalities that may be indicative of underlying cardiovascular pathology in the highly trained junior athlete

- ST segment depression or deep (more negative than −0.2 mV) T wave inversions in any lead
- Minor T wave inversions in any lead (except aVR and V1 or aVL when the QRS axis more than + 60°) in junior athletes older than 16
- Minor T wave inversions in any lead except V2 and V3 in athletes less than 16
- Romhilt-Estes voltage criterion for LVH in female athletes
- Pathological Q wave patterns
- Left axis deviation
- Complete bundle branch block

Br J Sports Med: first published as 10.1136/bjsm.33.5.319 on 1 October 1999. Downloaded from http://bjsm.bmj.com/ on October 26, 2021 by guest. Protected by copyright.

1 Oakley CM. The electrocardiogram in the highly trained athlete. *Cardiol Clin* 1992;**10**:295–302.
2 Smith WG, Cullen KJ, Thornburn IO. Electrocardiograms of marathon runners in the 1962 Commonwealth games. *Br Heart J* 1964;**26**:469–76.
3 Oakley DG, Oakley CM. Significance of abnormal electrocardiograms in highly trained athletes. *Am J Cardiol* 1982; **50**:985–9.
4 Maron BJ, Roberts WC, McAllister HA, *et al*. Sudden death in young athletes. *Circulation* 1980;**62**:218–22.
5 Corrado D, Thiene G, Nava A, *et al*. Sudden death in young competitive athletes. Clinicopathological correlations in 22 cases. *Am J Med* 1990;**89**:588.
6 Maron BJ, Shirani J, Poliac LC, *et al*. Sudden death in young competitive athletes. Clinical, demographic, and pathological profiles. *JAMA* 1996;**276**:199–204.
7 Friedmann HH. *Diagnostic electrocardiography and vecterocardiography*. New York: McGraw-Hill, 1971.
8 Bazett HC. An analysis of the time relations of electrocardiograms. *Heart* 1920;**7**:353–67.
9 Benhorin J, Merri M, Alberti M, *et al*. The long QT syndrome. New electrocardiographic characteristics. *Circulation* 1990;**82**:1539–41.
10 Morris JJ, Estes EH, Whalen RE, *et al*. P-wave analysis in valvular heart disease. *Circulation* 1964;**29**:242.
11 Sokolow M, Lyon TP. The ventricular complex in left ventricular hypertrophy obtained by unipolar precordial and limb leads. *Am Heart J* 1949;**37**:161–86.
12 Sokolow M, Lyon TP. The ventricular complex in right ventricular hypertrophy as obtained by unipolar precordial and limb leads. *Am Heart J* 1949;**38**:273.
13 Romhilt DW, Estes EH, Durham NC. A point-score system for the ECG diagnosis of left ventricular hypertrophy. *Am Heart J* 1968;**6**:752–8.
14 Huston TP, Puffer JC, Rodney WM. The athletic heart syndrome. *N Engl J Med* 1985;**313**:24–31.
15 Roeske WR, O'Rourke RA, Klein A, *et al*. Noninvasive evaluation of ventricular hypertrophy in professional athletes. *Circulation* 1976;**53**:286–92.
16 Ikaheimo M, Palatsi I, Takkunen J. Noninvasive evaluation of the athletic heart: sprinters versus endurance runners. *Am J Cardiol* 1979;**44**:24–30.
17 Raskoff WJ, Goldman S, Cohn K. "The athletic heart". Prevalence and physiological significance of left ventricular enlargement in distance runners. *JAMA* 1976;**236**:158.
18 Kansal S, Roitman DI, Sheffield LT. A quantitative relationship of electrocardiographic criteria of left ventricular hypertrophy with echocardiographic left ventricular mass. A multivariate approach. *Clin Cardiol* 1983;**6**:456.
19 Maron BJ, Wolfson JK, Ciro E, *et al*. Relation of electrocardiographic abnormalities and patterns of hypertrophy identified by 2-dimensional echocardiography in patients with hypertrophic cardiomyopathy. *Am J Cardiol* 1983;**51**: 189.
20 Savage DD, Seides SF, Clarke CE, *et al*. Electrocardiographic findings in patients with obstructive and non obstructive hypertrophic cardiomyopathy. *Circulation* 1986; **58**:402–8.
21 Moore NE, Boineau JP, Patterson DG. Incomplete right bundle-branch block: an electrocardiographic enigma and possible misnomer. *Circulation* 1971;**45**:678–87.
22 Hanne-Paparo N, Wendkos MH, Brunner D. T wave abnormalities in the electrocardiograms of top-ranking athletes without demonstrable organic heart disease. *Am Heart J* 1971;**81**:743–7.
23 Furnanello F, Belfini R, Bertoldi A, *et al*. Arrhythmia patterns in athletes with arrhythmogenic right ventricular dysplasia. *Eur Heart J* 1989;**10**:16–19
24 Thiene G, Nava A, Corrado D, *et al*. Right ventricular cardiomyopathy and sudden death in young people. *N Engl J Med* 1988;**138**:129–33.
25 Peters S, Weber B, Reil GH. Conventional electrocardiogram in arrhythmogenic right ventricular dysplasia-cardiomyopathy and idiopathic right ventricular outflow tachycardia. *Annals of Non Invasive Cardiology* 1996;**1**:400–4.
26 Zeppilli P, Sandric S, Caselli G, *et al*. Comparative electrovectorcardiogaphic: echocardiographic study in athletes with ST-T wave abnormalities (pseudoischemic patterns). In: Lubich T, Venerando A, eds. *Sports cardiology*. Bologna: Aulo Gaggi, 1980:735–48.
27 Taggart P, Carruthers M, Joseph S, *et al*. Electrocardiographic changes resembling myocardial ischaemia in asymptomatic men with normal coronary arteriograms. *Br Heart J* 1979;**41**:214–25.
28 Caselli G, Pivoni G, Venerando A. A follow-up study of abnormalities of repolarisation in athletes. In: Lubich T, Venerando A, eds. *Sports cardiology*. Bologna: Aulo Gaggi, 1980;477–99.

Take home message

A spectrum of ECG patterns in the junior athlete should be useful in distinguishing a normal athlete's heart from the pathological state. Isolated Sokolow voltage criterion for LVH, ST segment elevation, and peaked T waves are common. ST segment depression, T wave inversions exceeding –0.2 mV in V2 and V3 in subjects under 16, any T wave inversion in V2 and V3 in athletes over 16, any T wave inversions in leads V4–V6 and lateral leads in athletes over 14, left axis deviation, pathological Q waves, LBBB, and female athletes with a Romhilt-Estes points score of 5 or more are not found and are probably indications for further investigation. Minor T wave inversion in the inferior leads is rare in athletes. Whereas this may be a normal variant in athletes, it is common in patients with cardiomyopathy, and this condition should be excluded before further competition is allowed.

Commentary

Cardiac adaptations to exercise have received substantial attention in the medical literature over many years. Most of the literature concerns the effect of short and long term exercise in senior or even veteran athletes (references 1 and 2 in the paper). This study examines the ECG changes in junior athletes. The authors have been privileged to have access to 1000 junior athletes participating in their individual sports at an elite level. They have compared the ECG findings with a control group. As expected, bradycardia and sinus arrhythmia are more common in athletes, with small changes occurring in the conduction intervals. Although these reached statistical significance, are they of any clinical or pathological significance? ECG criteria are very often poor indicators of the presence of left ventricular hypertrophy but nevertheless this was found to be more common in the athletic population. It is rather surprising that more T wave changes were not detected, and high grades of heart block were also extremely rare. The reader may feel that the study highlights the shortcomings of a simple resting ECG in the evaluation of junior athletes, but it also, in view of its size, is an important contribution to our understanding of resting ECG changes in these young people. I hope that, in time, the authors will consider a follow up study to examine temporal changes in ECG in those who continue exercising and also perhaps extend their study to ambulatory electrocardiography.

ROBIN J NORTHCOTE
Consultant Cardiologist, Glasgow

Br J Sports Med: first published as 10.1136/bjsm.33.5.319 on 1 October 1999. Downloaded from http://bjsm.bmj.com/ on October 26, 2021 by guest. Protected by copyright.