

## CASE REPORT

# Hip fracture-dislocation in football: a report of two cases and review of the literature

E Giza, K Mithöfer, H Matthews, M Vrahas

*Br J Sports Med* 2004;38:e17 (<http://www.bjsportmed.com/cgi/content/full/38/4/e17>). doi: 10.1136/bjism.2003.005736

Soccer is the world's most popular sport, with over 200 million participants world wide. Fractures account for only 4–9% of acute injuries, and hip fracture-dislocation is extremely uncommon. The potentially serious long term sequelae require that team physicians have an awareness of this injury. Two cases of traumatic hip fracture-dislocation are here reported in recreational soccer players sustained by low energy mechanisms. Prompt reduction and fixation are important to produce a stable and congruent joint.

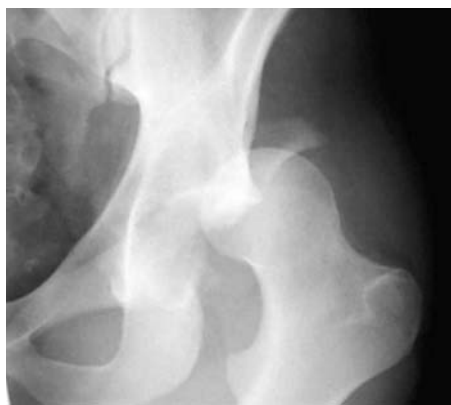Football is the world's most popular sport. The Fédération Internationale de Football Association (FIFA), the world governing body of football, has nearly 200 million active members.<sup>1</sup> In the United States, football has increased considerably in popularity during the past decade. Currently 12.5–18.2 million Americans play football, and participation in the sport is increasing annually at a rate of 11.4–21.8%.<sup>2</sup>

Numerous epidemiological studies have shown the incidence of football injuries to be 10–35 per 1000 game hours,<sup>3</sup> and it is therefore estimated that every player will have one performance limiting injury a year.<sup>1–6</sup> The most common injuries are contusions, sprains, and/or strains in the thigh, knee, and ankle.<sup>7</sup> Fractures are relatively uncommon, accounting for 4–9% of acute injuries,<sup>4–9</sup> and only three cases of hip dislocation have been reported.<sup>10–11</sup> Posterior hip fracture-dislocations usually result from high energy trauma;<sup>12</sup> however, we report two cases of traumatic hip fracture-dislocation in recreational footballers sustained by low energy mechanisms.

### CASE REPORT 1

A 28 year old man with no medical history suffered a traumatic left hip fracture-dislocation while playing recreational indoor football. He was struck from behind on the left buttock by an opposing player, causing acute flexion and internal rotation of the hip. The fracture was reduced within six hours, and the patient suffered no neurological injury. Plain radiographs (fig 1) and a computed tomography scan (fig 2) of the pelvis revealed a left posterior wall fracture which involved 30–40% of the weight bearing portion of the posterosuperior portion of the acetabulum.

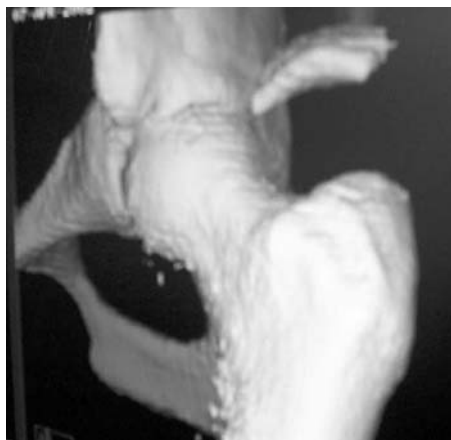
An open reduction and internal fixation of the posterior acetabulum with a 3.5 mm reconstruction plate (fig 3) was performed using a Kocher-Langenbeck approach. The patient had an uneventful postoperative course, and was only allowed touch down weight bearing for 12 weeks. At the one year follow up, the injury was clinically and radiographically healed with a passive hip flexion of 110° and abduction of 35°. The patient was pain free and had a short musculoskeletal function assessment (SMFA) score of 5.43 (best score = 0, worst score = 100).



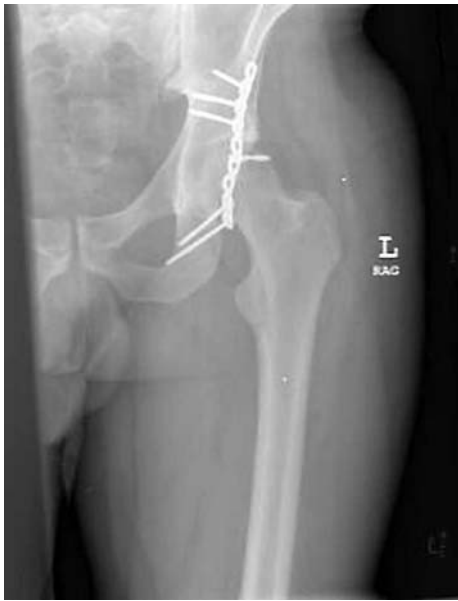**Figure 1** Left hip obturator oblique radiograph before surgery showing a posterior wall fracture of the left acetabulum.

### CASE REPORT 2

A 41 year old woman with no medical history suffered a traumatic left hip fracture-dislocation while playing recreational football. While dribbling the ball, she fell forward with her hip internally rotated. She then felt a “pop”, and collapsed with an immediate inability to bear weight. There was no contact with an opposing player. A closed reduction was performed within four hours of the event, and the patient suffered no neurological injury. Plain radiographs and a computed tomography scan of the pelvis revealed a left posterior wall fracture which involved 20% of the weight bearing portion of the posterosuperior portion of the acetabulum.



**Figure 2** Three dimensional computed tomography scan of the hip before surgery.



**Figure 3** Anteroposterior pelvis radiograph after surgery showing fixation of the posterior wall fragment.

The patient subsequently underwent operative fixation identical with case 1. She had an uneventful postoperative course, and was only allowed touch down weight bearing for 12 weeks. At the one year follow up, the injury was clinically and radiographically healed. The patient was pain free with an SMFA score of 9.78. Examination of the hip revealed only a 5° deficit passive internal rotation compared with the uninvolved side. The patient elected not to return to play. Because of her age and sex, bone densitometry was performed to assess bone quality; the results showed normal Z and T scores.

## DISCUSSION

Hip fracture-dislocations usually occur with high energy trauma<sup>12</sup> and are uncommon in sports.<sup>13</sup> Hip dislocations (with and without associated acetabular fractures) have been reported in basketball, biking, American football, gymnastics, jogging, rugby, and skiing.<sup>13–14</sup> Only three cases have been reported in football.<sup>10–11</sup> In 1970, Lamke<sup>11</sup> investigated 110 traumatic dislocations of the hip and found that only six (5.5%) occurred during sporting activities. In a recent review, Chudik *et al*<sup>13</sup> estimated that hip dislocations during sporting activities represent only 2–5% of all hip dislocations.

The mechanisms of hip fracture-dislocations are dependent on the position of the hip at the time of injury and the force vector applied.<sup>12</sup> The flexed, adducted hip is at risk, and indeed the most commonly reported mechanisms for posterior dislocations in sport are (a) a forward fall on the knee with a flexed hip and (b) a blow from behind when the athlete is down on all four limbs.<sup>13</sup> Interestingly, the second patient reported here did not have any forceful contact and was internally rotated at the time of the injury, and the mechanism for the first patient was a posterior to anterior blow to a flexed and internally rotated hip.

Most hip dislocations in sports can be categorised as “less complicated traumatic hip dislocations” by the Stewart-Milford classification<sup>15</sup> due to the fact that minimal force is involved; however, the same prognostic factors that determine the functional outcome in more severe hip injuries apply to the injuries reported here. The incidence of avascular

necrosis of the femoral head greatly increases if the time to reduction is more than six hours.<sup>12</sup> The published percentage of avascular necrosis after “less complicated hip dislocations” is 0–22%.<sup>13</sup> Post-traumatic osteoarthritis occurs after 3–48% of dislocations and increases if appropriate fixation with articular surface restoration is not performed.<sup>12</sup> Stiris<sup>10</sup> reported one case of recurrent hip subluxation in a footballer after closed treatment without operative fixation. Neither patient reported here had clinical or radiographic evidence of avascular necrosis at the one year follow up.

The accepted classification scheme of football injuries<sup>16–17</sup> defines a severe injury as one that results in more than four weeks of absence from practice and game play. A study of 398 Czech footballers revealed that 16.5% of injuries during one year of play were severe; however, joint sprains and muscle strains were most common, and no hip dislocations were reported.<sup>17</sup> Hip fracture-dislocation is extremely uncommon in football; however, the potentially serious long term sequelae and associated loss of playing time mean that the team doctor should be aware of this injury. Furthermore, the two cases reported in this paper illustrate the importance of prompt reduction and operative fixation to produce a stable and congruent joint.

## Authors' affiliations

**E Giza, K Mithöfer, H Matthews, M Vrahas**, Harvard Orthopaedic Residency Program, Massachusetts General Hospital, Boston, MA 02114, USA

Correspondence to: Dr Giza, Harvard Orthopaedic Program, Massachusetts General Hospital, 25 Fruit Street, GRB 624, Boston, MA 02114, USA; egiza@partners.org

Accepted 20 May 2003

## REFERENCES

- 1 Dvorak J, Junge A. Football injuries and physical symptoms. *Am J Sports Med* 2000;**28**:53–9.
- 2 Anderson S. Injuries in youth football: a subject review. *Pediatrics* 2000;**105**:659–61.
- 3 Dahar R. Rehabilitation of muscle-tendon injuries to the hip, pelvis, and groin areas. *Sports Med Arthrosc Rev* 1997;**5**:326–33.
- 4 Nielsen A, Yde J. Epidemiology and traumatology of injuries in football. *Am J Sports Med* 1989;**17**:803–7.
- 5 Inklaar H, Bol E, Schmikli S. Injuries in male football players: team risk analysis. *J Sports Med* 1996;**17**:229–34.
- 6 Hawkins R, Fuller C. An examination of the frequency and severity of injuries and incidents at three levels of professional football. *Br J Sports Med* 1998;**32**:326–32.
- 7 Hawkins R, Hulse M, Wilkinson C, *et al*. The association football medical research programme: an audit of injuries in professional football. *Br J Sports Med* 2001;**35**:43–7.
- 8 Sullivan J, Gross R, Grana W, *et al*. Evaluation of injuries in youth football. *Am J Sports Med* 1980;**8**:325–7.
- 9 Soderman K, Adolphson J, Lorentzon R, *et al*. Injuries in adolescent female players in European football: a prospective study over one outdoor football season. *Scand J Med Sports Sci* 2001;**11**:299–304.
- 10 Stiris MG. MR imaging after sports-induced hip dislocations. Report of three cases. *Acta Radiol* 2000;**41**:300–2.
- 11 Lamke L. Traumatic dislocations of the hip. *Acta Orthop Scand* 1970;**41**:188–98.
- 12 Tornetta P, Mostafavi H. Hip dislocation: current treatment regimens. *J Am Acad Orthop Surg* 1997;**5**:27–36.
- 13 Chudik S, Answorth A, Lopez V, *et al*. Hip dislocations in athletes. *Sports Med Arthrosc Rev* 2002;**10**:123–33.
- 14 Mitchell JC, Giannoudis PV, Millner PA, *et al*. A rare fracture-dislocation of the hip in a gymnast and review of the literature. *Br J Sports Med* 1999;**33**:283–4.
- 15 Stewart M, Milford L. Fracture-dislocation of the hip: an end-result study. *J Bone Joint Surg [Am]* 1954;**36**:315–42.
- 16 Engstrom B, Forssblad M, Johansson C, *et al*. Does a major knee injury definitely sideline an elite football player? *Am J Sports Med* 1990;**18**:101–5.
- 17 Chomiak J, Junge A, Peterson L, *et al*. Severe injuries in football players. *Am J Sports Med* 2000;**28**:S58–68.