


Resurgence of sport in the wake of COVID-19: cardiac considerations in competitive athletes

Aaron Baggish,¹ Jonathan A Drezner ,² Jonathan Kim,³ Matthew Martinez,⁴ Jordan M Prutkin⁵

The COVID-19 pandemic brought the global world of sports to a staggering halt. In unprecedented fashion and with

¹Cardiovascular Performance Program, Massachusetts General Hospital, Boston, Massachusetts, USA

²Stadium Sports Medicine Center, University of Washington, Seattle, Washington, USA

³Division of Cardiology, Emory University, Atlanta, Georgia, USA

⁴Atlantic Health, Morristown Medical Center, Morristown, New Jersey, USA

⁵Department of Internal Medicine, Division of Cardiology, University of Washington, Seattle, Washington, USA

Correspondence to Dr Aaron Baggish, Cardiovascular Performance Program, Massachusetts General Hospital, Boston, MA 02114, USA; abaggish@mgh.harvard.edu

few exceptions, professional leagues, mass participation endurance events, and youth sport around the globe went silent. In the face of a rapidly evolving health crisis, the decision to cancel or postpone sporting events was a logical and necessary step. COVID-19 is a highly contagious, potentially fatal virus that is transmitted primarily through contact with aerosolised or surface-dwelling respiratory secretions, a process that requires close human contact.¹ Competitive sport as we know it, from athletes ‘elbowing’ one another for position on the pitch to arenas packed with fans, may be the

quintessential antithesis of social distancing. There is concern that the Champions League match between Atalanta and Valencia in Milan may have influenced the trajectory of COVID-19 cases in Europe.² In the absence of a vaccination or curative intervention, physical distancing emerged as the key step to slow or stop the spread of COVID-19. Thus, the decision to turn off the lights and to silence competitive athletics represented a logical, essential and highly visible component in the global fight against COVID-19.

This has been an unusually quiet time for the sports medicine community. Athletic training rooms have gone dark, and many clinicians have been repurposed to meet the needs of patients with COVID-19. Fortunately, this will not last forever. The great American poet Robert Frost once said, ‘In three words I can sum up everything I’ve learnt about life. It goes on’, and indeed, there are early signs of progress in the fight against COVID-19. As rates of new infection begin to plateau and even decline in some countries, there

is mounting enthusiasm for a resurrection of sport. When it finally comes, the first serve, the first kickoff and the first starter's gun will aid in global recovery and the redefining of normal life. We eagerly await this day, but proceeding too soon and without a unified and purposeful approach by the sports medicine community to ensure the health and wellness of our athletes may prove disastrous.

CARDIOVASCULAR COMPLICATIONS AND COVID-19

COVID-19 is a systemic illness that affects most major organs, including the cardiovascular system.³ Clinical experience, largely the care of critically ill patients with COVID-19, has taught us that COVID-19 may affect the heart in at least two fundamental ways. First, the intense 'cytokine storm' that develops during severe COVID-19 illness may lead to decrements in cardiac function, similar to those seen in other forms of sepsis, with features that overlap with classic forms of 'stress' or catecholamine-induced cardiomyopathy.⁴ To date, this appears to be a self-limiting phenomenon confined to the severe phases of

the illness. Alternatively, COVID-19 may directly infect myocardial cells, leading to myocarditis with lymphocyte-rich inflammatory histology, acute impairment of cardiac muscle function and potentially residual chronic scar with increased vulnerability to malignant ventricular arrhythmias. While COVID-19 myocardial injury, as defined by increases in circulating cardiac troponin levels, has been described in up to 28% of the sickest of patients,⁵ its prevalence and clinical implications among infected people who experience mild illness or who remain asymptomatic remains completely unknown. Further, the incidence of silent myocardial inflammation that lingers long after the resolution of typical COVID-19 symptoms, a form of disease that may uniquely affect athletes during resumption of training and competition, is also completely unknown.

CARDIAC TESTING IN ATHLETES WITH COVID-19

Numerous medical and sporting organisations are developing comprehensive strategies to ensure a safe return to training and competition. This is

a complex process that will require a multidisciplinary, team-based approach that balances priorities surrounding athlete health with strategies to protect the general public from further spread of the infection. Ensuring the health of athletes will involve continued strategic use of physical distancing, widespread dissemination of COVID-19 antigen and antibody testing, the use of electrocardiography or blood biomarker testing to screen for occult myocardial injury and inflammation, and definitive diagnostic and therapeutic strategies for those deemed at highest risk. Evidence is limited, and conclusive recommendations regarding these issues will require ongoing research and monitoring of athletes afflicted with COVID-19. However, we take this opportunity to provide some initial guidance for the cardiac evaluation of athletes with prior COVID-19 infection (table 1).

TRADING ONE PREPARTICIPATION EVALUATION (PPE) FOR ANOTHER

In lieu of these complexities, we also want to address a simple and well-known strategy that may prove more important than ever before. Oversight

Table 1 Cardiac evaluation in athletes with prior COVID-19 infection

Clinical scenario	Recommended assessment	Comments
Athletes with <i>prior asymptomatic infection</i> as confirmed antibody to severe acute respiratory syndrome coronavirus 2	<i>Focused medical history and physical examination</i> to screen for findings newly emergent in the COVID-19 era Consider 12-lead ECG* ▶ If ECG is abnormal or shows new repolarisation changes compared with a prior ECG, then additional evaluation with minimum echocardiogram and exercise test is warranted in conjunction with a sports cardiologist.	▶ Myopericarditis related to COVID-19 should be considered in patients with a history of new-onset chest pain/pressure (even in the absence of fever and respiratory symptoms), palpitations or exercise intolerance. ▶ Comprehensive clinical evaluation, regardless of ECG findings, is indicated in athletes with new-onset cardiovascular symptoms or exercise intolerance.
Athletes with a <i>history of mild illness (non-hospitalised)</i> related to confirmed or suspected COVID-19	<i>Focused medical history and physical examination</i> to screen for persistent or new postinfectious findings following COVID-19 infection Perform 12-lead ECG* ▶ <i>If ECG is abnormal or shows new repolarisation changes compared with a prior ECG</i> , then additional individualised evaluation is warranted, including at minimum echocardiography and exercise testing, in conjunction with a sports cardiologist.	▶ <i>ECG findings</i> that may indicate viral-induced myocardial injury include pathological Q waves, ST segment depression, (new) diffuse ST segment elevation and T-wave inversion. ▶ Comprehensive clinical evaluation, regardless of ECG findings, is indicated in athletes with new-onset cardiovascular symptoms or exercise intolerance.
Athletes with a <i>history of moderate to severe illness (hospitalised)</i> related to confirmed or suspected COVID-19	<i>Comprehensive evaluation</i> prior to return to sport, in conjunction with a sports cardiologist, to include blood biomarker assessment (ie, hs-Tn and NP), 12-lead ECG, echocardiography, exercise testing and ambulatory rhythm monitoring	▶ <i>Myocardial injury is more likely in patients with a more severe disease course</i> , and normal cardiac function and exercise tolerance should be established prior to a return to exercise. ▶ Cardiac MRI may be considered based on clinical suspicion of myocardial injury.†
Athletes with a <i>history of COVID-19 infection (regardless of severity) and documented myocardial injury</i> as indicated by one or more of the following: in-hospital ECG changes, hs-Tn or NP elevation, arrhythmia or impaired cardiac function	<i>Comprehensive evaluation</i> prior to return to sport, in conjunction with a sports cardiologist, to include blood biomarker assessment (ie, hs-Tn and NP), 12-lead ECG, echocardiography, exercise testing, ambulatory rhythm monitoring and cardiac MRI.†	▶ Return to training should be gradual and under the supervision of a cardiologist. ▶ Longitudinal follow-up, including serial cardiac imaging, may be required in athletes with initially abnormal cardiac function.

*ECG as a screening test to exclude myocarditis is limited. ECG in patients with myocarditis may be normal or may show non-specific abnormalities. Additional evaluation may be warranted based on clinical suspicion.

†Cardiac MRI should be performed with gadolinium to assess for myocardial scar and LGE. The presence of LGE is associated with a higher risk of major adverse cardiovascular events.

hs-Tn, high-sensitivity cardiac troponin; LGE, late gadolinium enhancement; NP, natriuretic peptide.

of the PPE (not in this case personal protective equipment) is a fundamental responsibility of sport medicine providers.⁶ From the perspective of heart health, the PPE is traditionally viewed as a tool to screen for occult cardiovascular diseases that predispose the athlete to sudden death. In the wake of COVID-19, it will be prudent to adopt a broader view of the cardiovascular PPE. In addition to using the PPE to search for rare genetic and congenital conditions, we will be best positioned to facilitate safe return to sport if we also use the PPE to screen for cardiovascular sequelae of COVID-19. Though imperfect, medical history and physical examination may prove to be valuable tools for identifying athletes with underlying myocardial inflammation and/or overt myocarditis. In addition, practitioners and organisations that are experienced and resourced in the use of 12-lead electrocardiography will optimise this screening adjunct by keeping a keen eye out for patterns reflective of myocardial inflammation, such as T-wave inversions and new ST segment changes.⁷ This can and will help to identify those athletes that may require additional testing and medical care prior to return to play.

The resumption of competitive athletics will bring great joy but will come with considerable challenge and additional efforts to ensure cardiac

safety. There are fundamental questions about how COVID-19 will leave its mark on the millions of athletes worldwide and what steps should be taken to prevent further unnecessary loss of life. While these questions will be asked by the men and women on the front lines of athlete care, they will only be answered by the sharing of experiences and the pooling of rigorously collected data. If done effectively, the connotation of the acronym PPE will once again relate solely to the PPE rather than to the use of surgical masks and face shields that have defined this pandemic.

Twitter Jonathan A Drezner @DreznerJon

Collaborators N/A.

Contributors All authors contributed to the design, writing, content and review of the editorial.

Funding The authors have not declared a specific grant for this research from any funding agency in the public, commercial or not-for-profit sectors.

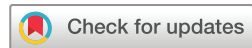Competing interests None declared.

Patient consent for publication Not required.

Provenance and peer review Not commissioned; internally peer reviewed.

This article is made freely available for use in accordance with BMJ's website terms and conditions for the duration of the covid-19 pandemic or until otherwise determined by BMJ. You may use, download and print the article for any lawful, non-commercial purpose (including text and data mining) provided that all copyright notices and trade marks are retained.

© Author(s) (or their employer(s)) 2020. No commercial re-use. See rights and permissions. Published by BMJ.



To cite Baggish A, Drezner JA, Kim J, *et al.* *Br J Sports Med* 2020;**54**:1125–1135.

Accepted 3 June 2020

Published Online First 19 June 2020

Br J Sports Med 2020;**54**:1125–1135.
doi:10.1136/bjsports-2020-102516

ORCID iD

Jonathan A Drezner <http://orcid.org/0000-0003-3519-9120>

REFERENCES

- SWX O, Tan YK, Chia PY, *et al.* Air, surface environmental, and personal protective equipment contamination by severe acute respiratory syndrome coronavirus 2 (SARS-CoV-2) from a symptomatic patient. *JAMA* 2020.
- . Available: <https://www.wsj.com/articles/the-soccer-match-that-kicked-off-italys-coronavirus-disaster-11585752012>
- Wang T, Du Z, Zhu F, *et al.* Comorbidities and multi-organ injuries in the treatment of COVID-19. *Lancet* 2020;395:e52.
- Clerkin KJ, Fried JA, Raikhelkar J, *et al.* Coronavirus disease 2019 (COVID-19) and cardiovascular disease. *Circulation* 2020.
- Shi S, Qin M, Shen B, *et al.* Association of cardiac injury with mortality in hospitalized patients with COVID-19 in Wuhan, China. *JAMA Cardiol* 2020. doi:10.1001/jamacardio.2020.0950
- Drezner JA, O'Connor FG, Harmon KG, *et al.* AMSSM position statement on cardiovascular Preparticipation screening in athletes: current evidence, knowledge gaps, recommendations and future directions. *Br J Sports Med* 2017;51:153–67.
- Drezner JA, Sharma S, Baggish A, *et al.* International criteria for electrocardiographic interpretation in athletes: consensus statement. *Br J Sports Med* 2017;51:704–31.