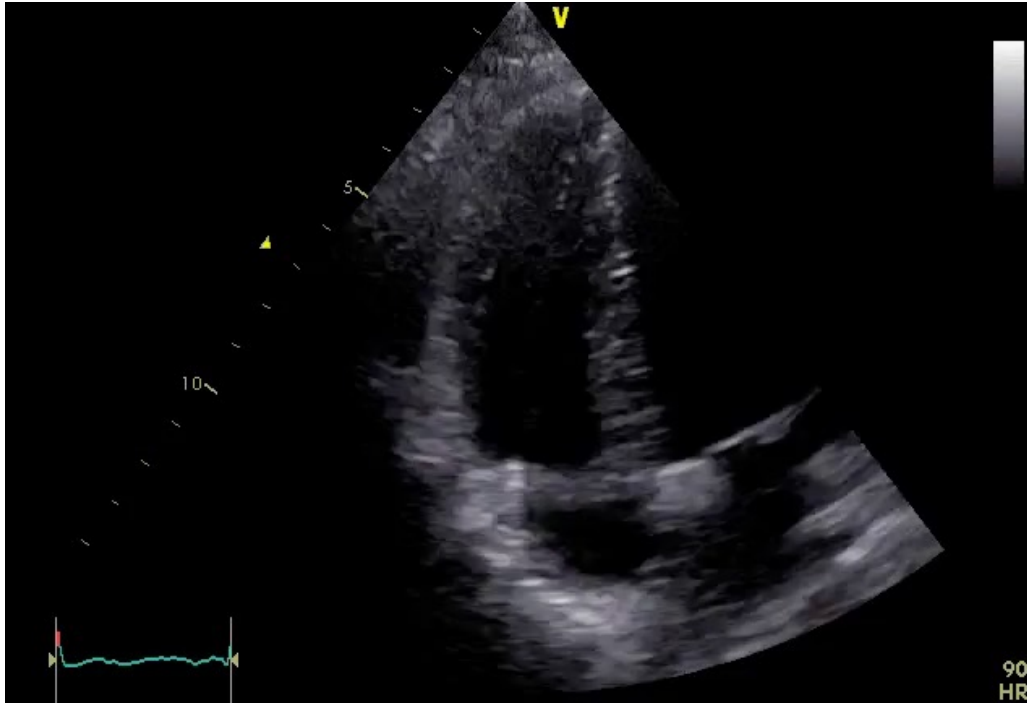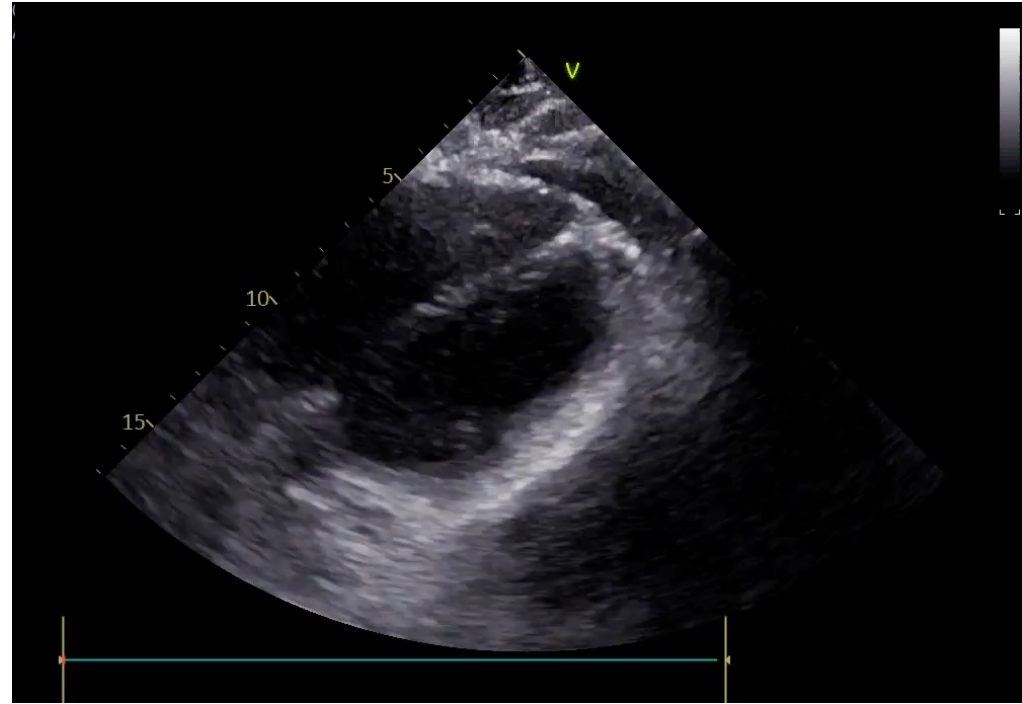




Clinical case #1: female athlete with pericardial effusion in absence of pericarditis. The athlete was evaluated 5 days after the first negative swab for SARS-CoV-2.



Clinical case #2: female athlete with pericardial effusion, chest pain and abnormal CRP levels, suggestive for pericarditis. The athlete was evaluated 15 days after the first negative swab for SARS-CoV-2.