

# Appendix A

Appendix for:

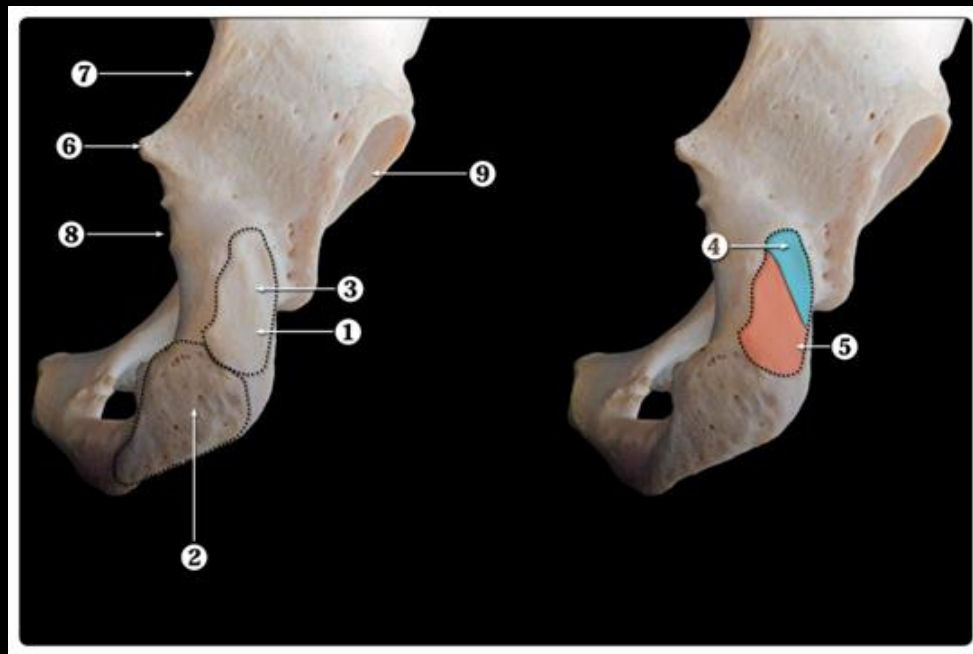
**Proximal hamstring tendon avulsions: comparable clinical outcomes of operative and non-operative treatment at one-year follow-up in a shared decision-making model.**

Anne D van der Made, Rolf W Peters, Claire Verheul, Frank Smithuis, Gustaaf Reurink, Maarten H Moen, Johannes L Tol, Gino MMJ Kerkhoffs.

# Shared decision-making

- Proximal hamstring anatomy + location of injury
- Expected advantages & disadvantages of treatment options
- Expected short-term outcome of operative & non-operative treatment
- Expected long-term outcome of operative & non-operative treatment

# Anatomy + location of injury



Ischial tuberosity

3. Vertical ridge

Divides upper region into:

4. Lateral facet

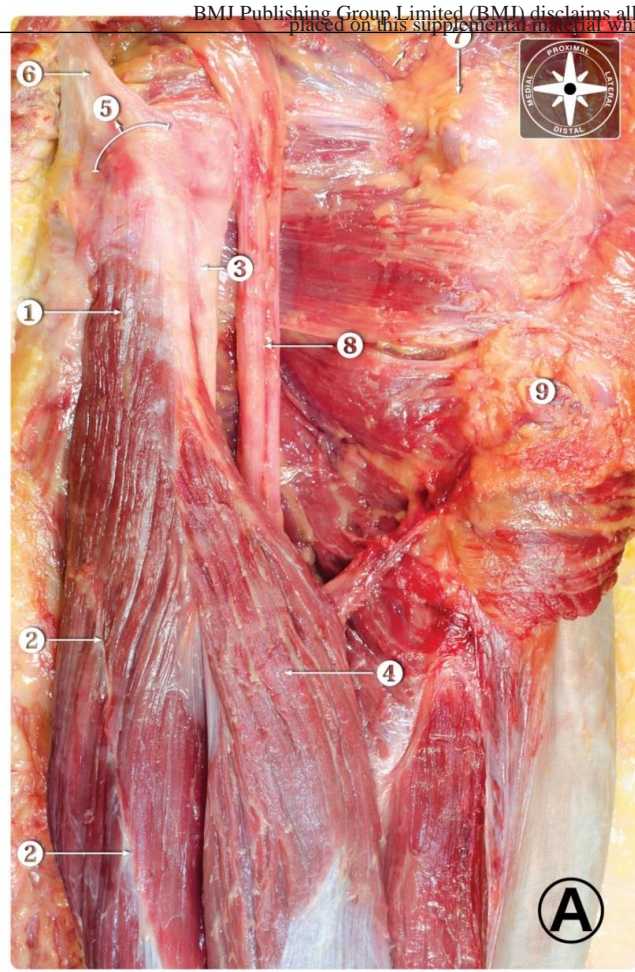
→ Semimembranosus

5. Medial facet

→ Biceps Femoris

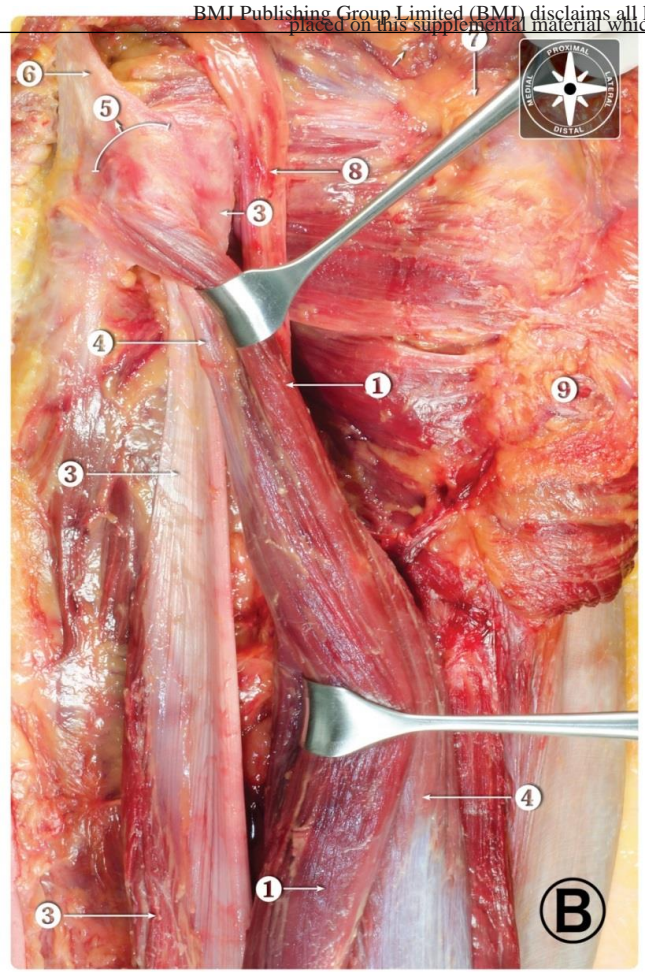
→ Semitendinosus

Image from: van der Made et al. The hamstring muscle complex. *Knee Surg Sports Traumatol Arthrosc.* 2015 Jul;23(7):2115-22.



1. Semitendinosus
3. Semimembranosus
4. Biceps Femoris (Long head)
5. Ischial tuberosity
6. Sacrotuberous ligament
8. Sciatic nerve

Image from: van der Made et al. The hamstring muscle complex. *Knee Surg Sports Traumatol Arthrosc.* 2015 Jul;23(7):2115-22.



- 1. Semitendinosus
- 3. Semimembranosus
- 4. Biceps Femoris (Long head)
- 5. Ischial tuberosity
- 6. Sacrotuberous ligament
- 8. Sciatic nerve

Image from: van der Made et al. The hamstring muscle complex. Knee Surg Sports Traumatol Arthrosc. 2015 Jul;23(7):2115-22.

# Operative & non-operative treatment

- Operative treatment
  - Surgical refixation of hamstrings
  - Post-operative protection (cast/brace)
  - Start of (phased) rehabilitation programme with experienced physiotherapist
- Non-operative treatment
  - Direct start of (phased) rehabilitation programme with experienced physiotherapist

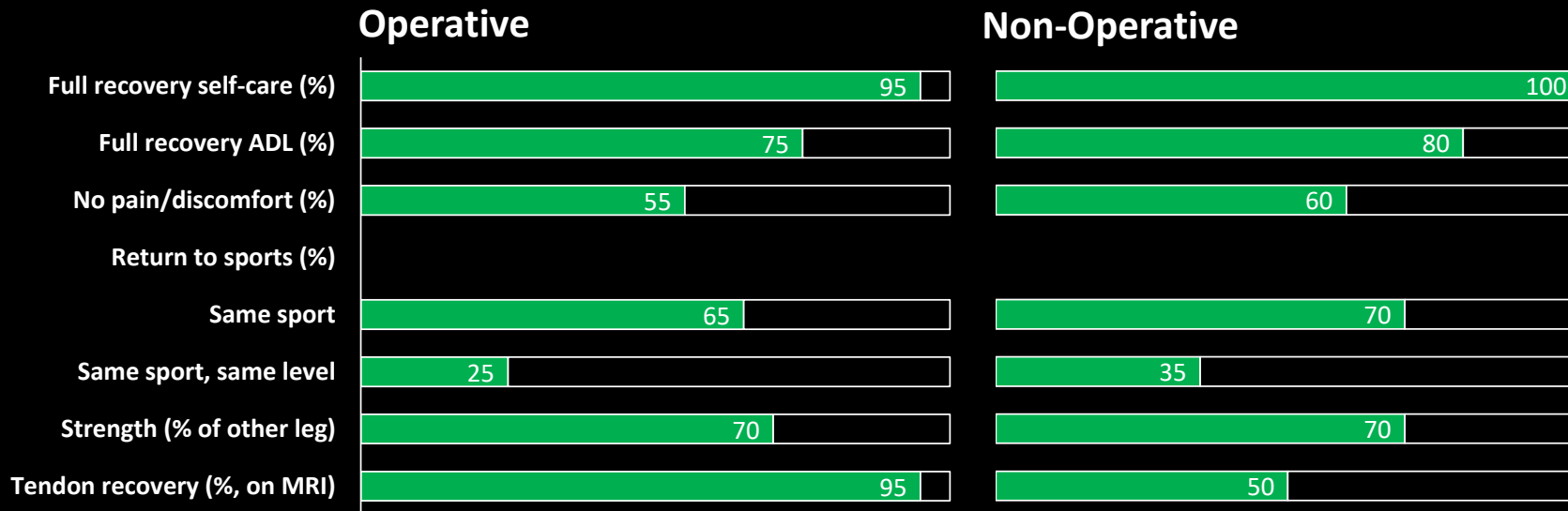
# Operative & non-operative treatment

## Expected advantages & disadvantages

<b>Operative</b>	<b>Non-operative</b>
+ Refixation of tendon(s)	+ Direct start of rehabilitation
+ Improved long-term recovery of strength/function	+ Quicker resumption of self-care/daily activities
+ Improved recovery of sciatic symptoms	
- Post-operative casting/bracing	- Outcome less predictable (tendon recovery ≈50%)
- Complication risk (e.g. re-operation, nerve damage, infection, DVT, hematoma)	- Higher chance of long-term strength deficit & decreased function

# Operative & non-operative treatment

Expected short-term outcome (current study, at 1 year)





# Operative & non-operative treatment

Expected long-term outcome (at 3-4 years, summary of scientific literature)

