SUPPLEMENTARY FILE 7
Primary cam morphology Delphi study – Dissent analysis Delphi domains 1 to 4

Although the main aim of the Delphi method is to structure a group communication process that might lead to consensus, we were also interested in panel dissent. To explore possible dissent, we applied *dissent analyses* including outlier analysis, bipolarity analysis, and stakeholder group analysis. In addition we performed a thematic analysis of panellists' comments, including tension and dissent, as described. [1,2]

Table of Contents

Outlier analysis

Outliers can have a substantial effect on variables (e.g., Interquartile range), and statistical consensus. The existence of outliers is therefore an important potential explanation for dissent. We identified low outliers as data points that fall more than 1.5 times the Interquartile range below the first quartile, and high outliers as data points that fall more than 1.5 times the Interquartile range above the third quartile. In addition, we visually inspected histograms of Round 2 stakeholder group scoring for outliers. We re-analysed consensus after eliminating outliers for all statements with marginal non-consensus to test if these had an impact on the group's consensus.

Definitions – Delphi domain 1

Outliers for ten of twelve definition statements in round 2, had no statistical effect on group consensus or non-consensus. (Figure 1) None of the outliers provided qualitative comments. One physical therapist chose "Unable to score" for most of the definition statements in round 1 and 2 as they *'did not agree that the concept of primary and secondary CAM is commonly agreed and established'*.

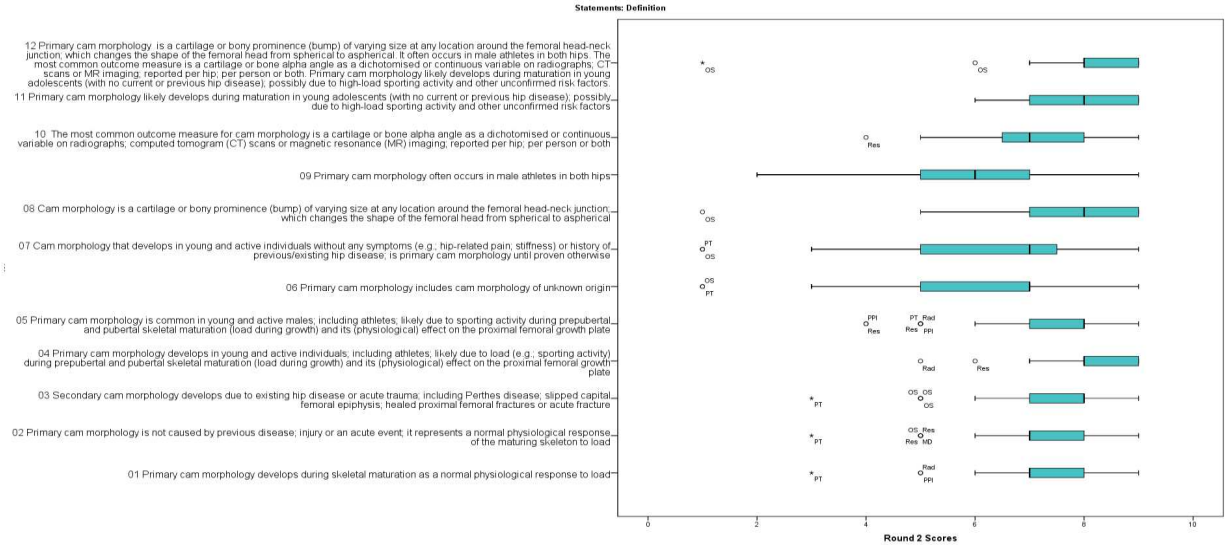

Figure SF7-1 Outliers for statements 1 to 12 (OS: Orthopaedic Surgeon; PPI: Patient & Public Involvement group member; MD: Physian; PT: Physical Therapist; Rad: Radiologist; Res: Researcher)

Terminology – Delphi domain 2

Outliers for 16 of the 19 terminology statements in round 2, had no statistical effect on group consensus or non-consensus. (Figure 2) The orthopaedic surgeon outlier for statements 13 and 26 did not agree that primary cam morphology refers to a bump "at any location" around the femoral head-neck junction. One physician chose "Unable to score" for most of the terminology statements in round 1 as they misinterpreted the statement wording. Feedback after round 1 clarified the misunderstanding.

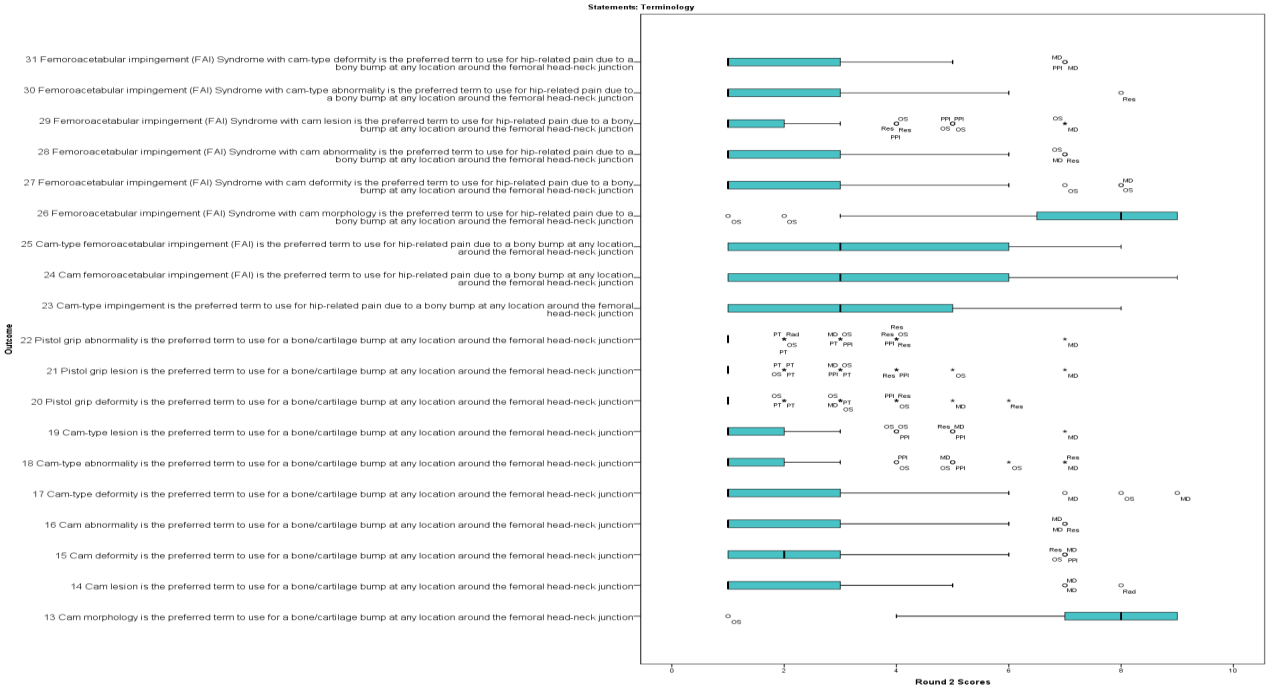

Figure SF7-2 Outliers for statements 13 to 31 (OS: Orthopaedic Surgeon; PPI: Patient & Public Involvement group member; MD: Physian; PT: Physical Therapist; Rad: Radiologist; Res: Researcher)

Taxonomy – Delphi domain 3

Although strong consensus was achieved for statements 32, 33 and 35, few outliers (mainly orthopaedic surgeons and a physical therapist) were not convinced (Figure 3). After removing two outliers for statement 34, the Delphi panel reached consensus on the importance of distinguishing between primary and secondary cam morphology in patients with femoroacetabular impingement syndrome.

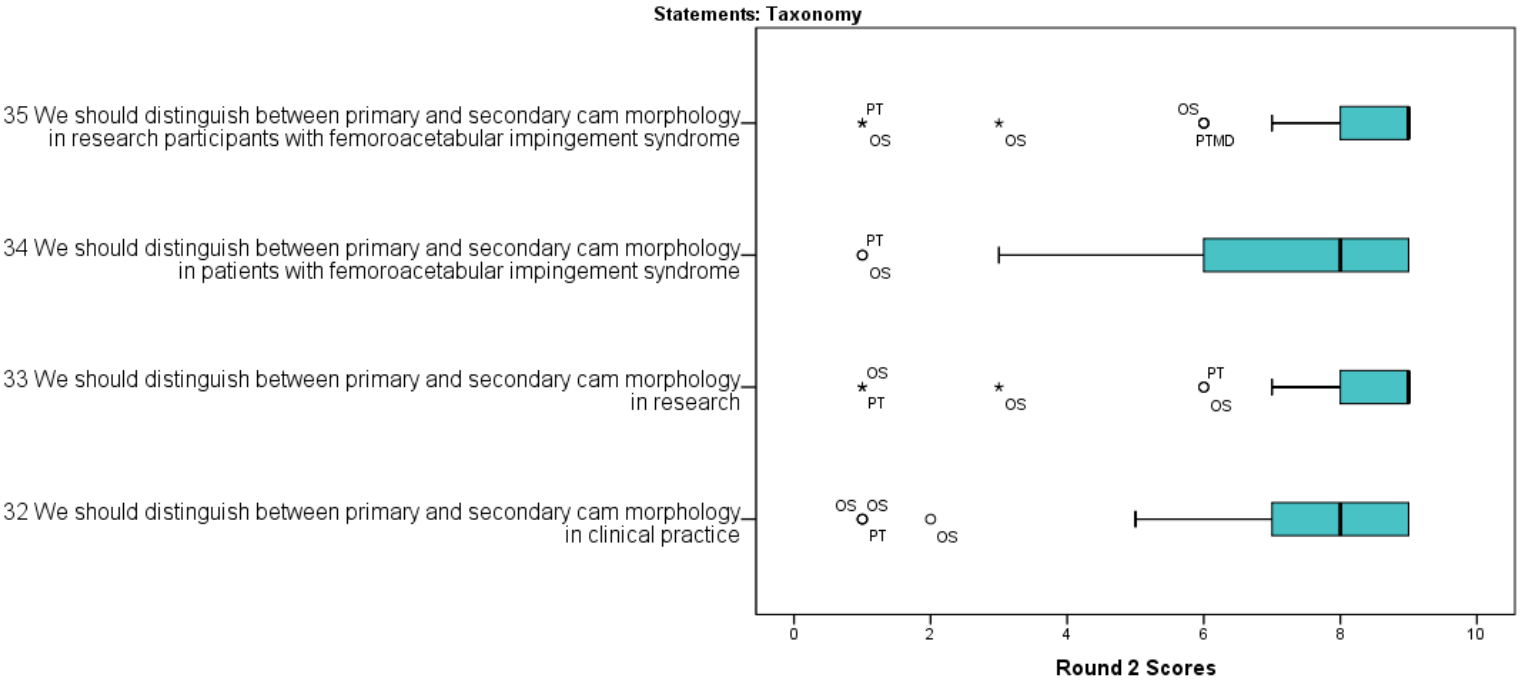

Figure SF7-3 Outliers for statements 32 to 35 (OS: Orthopaedic Surgeon; PPI: Patient & Public Involvement group member; MD: Physian; PT: Physical Therapist; Rad: Radiologist; Res: Researcher)

Imaging outcomes – Delphi domain 4

Six of 12 imaging outcomes statements (Statements 36, 39, 42, 44, 45, and 46) had outliers. (Figure 4). After eliminating the two orthopaedic surgeon outliers for marginally non-consensus statement 46, the Delphi panel reached consensus that the alpha angle as a continuous variable, reported for anteroposterior (AP) pelvis and Dunn 45° view radiographs, should be the radiographic imaging outcome measure for research on primary cam morphology prognosis.

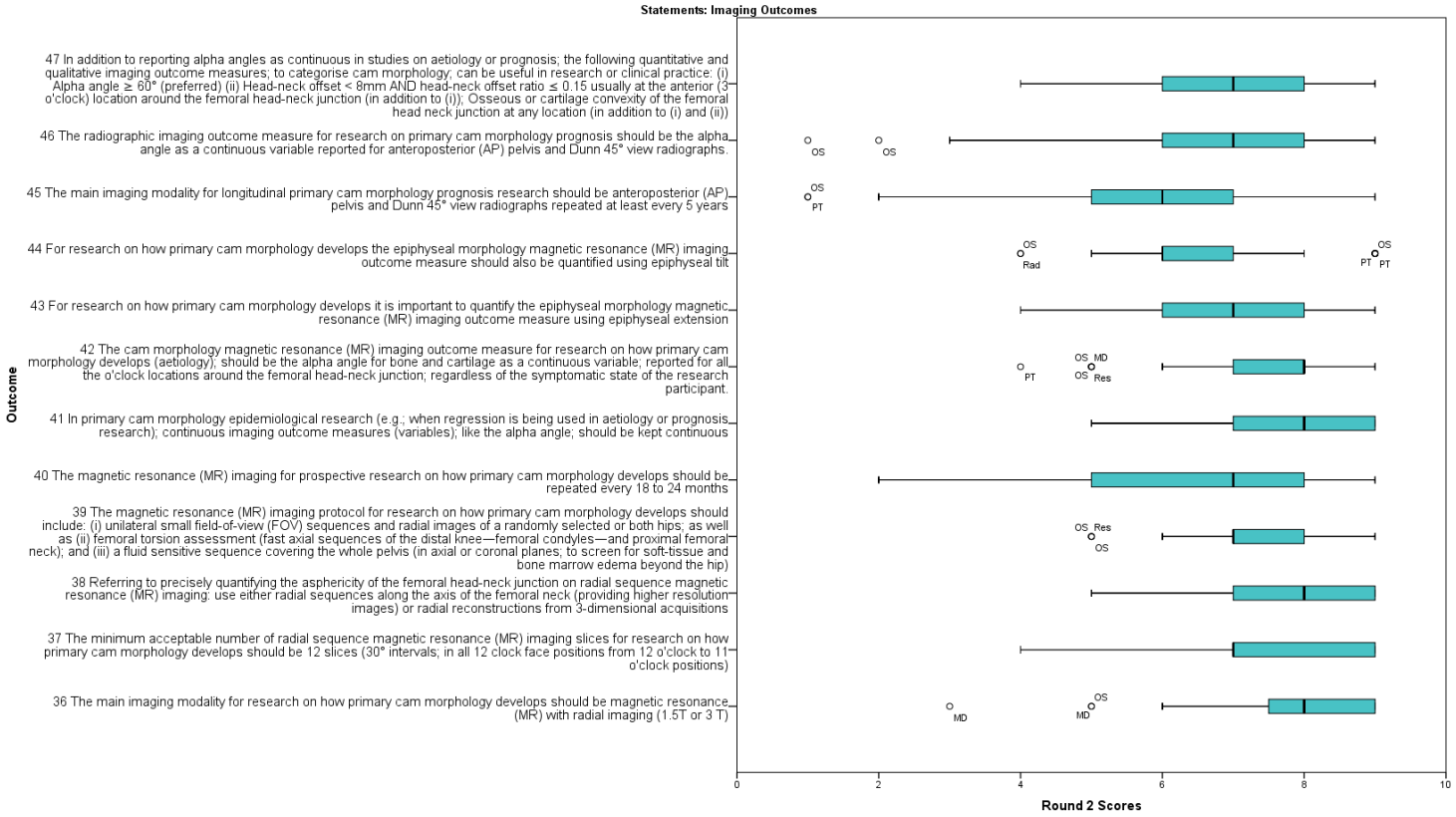

Figure SF7-4 Outliers for statements 32 to 35 (OS: Orthopaedic Surgeon; PPI: Patient & Public Involvement group member; MD: Physian; PT: Physical Therapist; Rad: Radiologist; Res: Researcher)

Bipolarity analysis

Opposing groups of experts with an important and insoluble cleft of opinion, might result in non-consensus. Bipolar data distribution is therefore a possible explanation for dissent. To test for bipolarity, we investigated potential bimodal distribution (two or more answer options had the same mode frequency) and visually inspected histograms for round 2 scores of each statement. [1]

Definitions – Delphi domain 1

There were no bimodal distribution in the overall scoring of definition statements in round 2. (Figure 5)

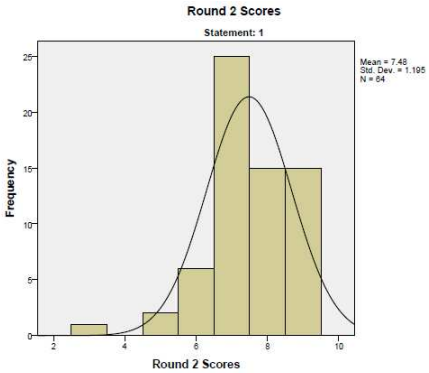

Figure 5a Statement 1

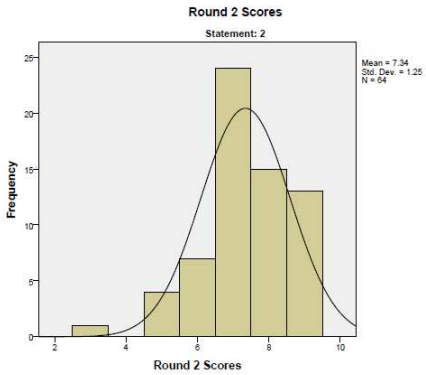

Figure 5b Statement 2

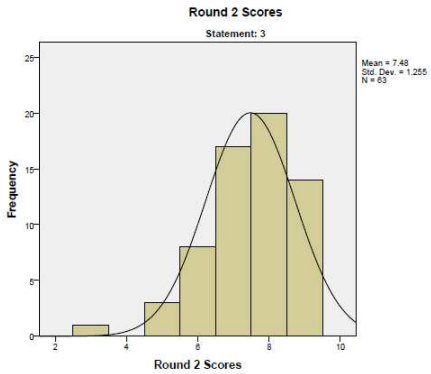

Figure 5c Statement 3

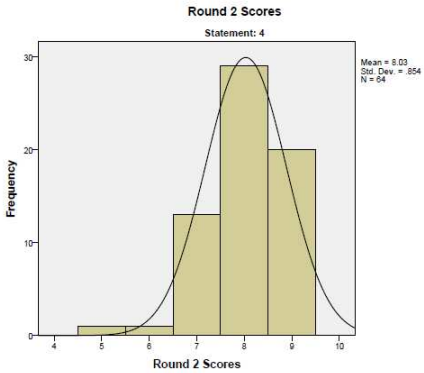

Figure 5d Statement 4

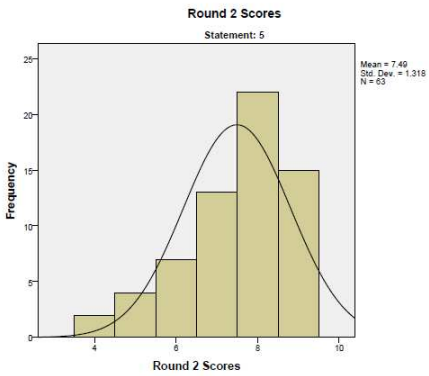

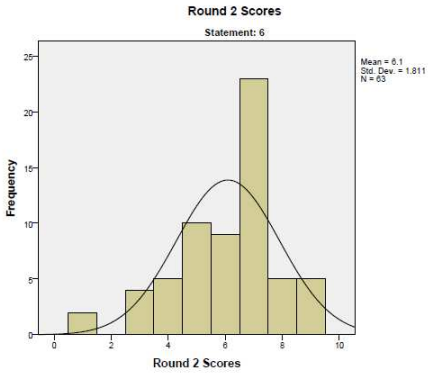

Figure 5e Statement 5

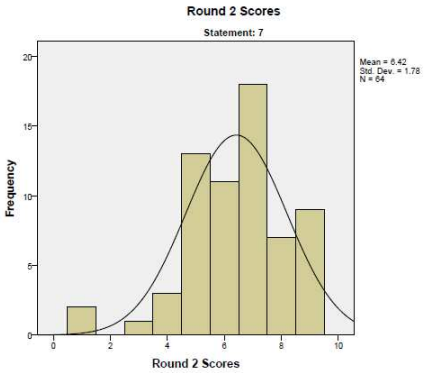

Figure 5f Statement 6

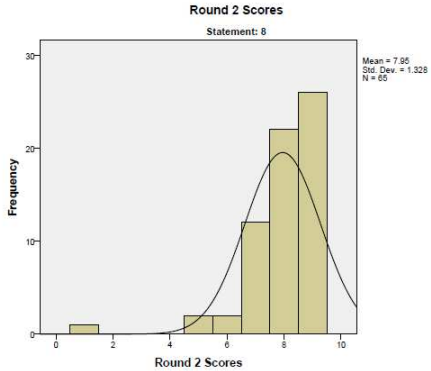

Figure 5g Statement 7

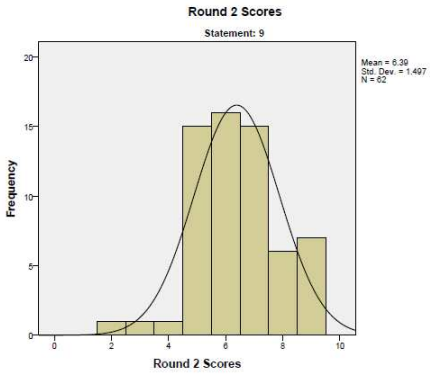

Figure 5h Statement 8

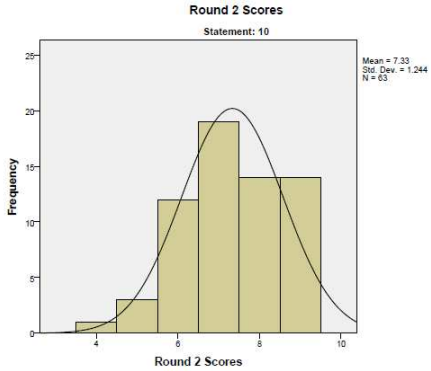

Figure 5i Statement 9

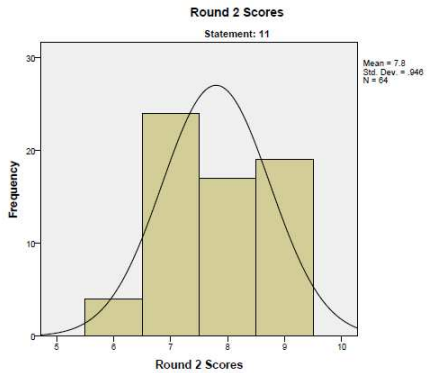

Figure 5j Statement 10

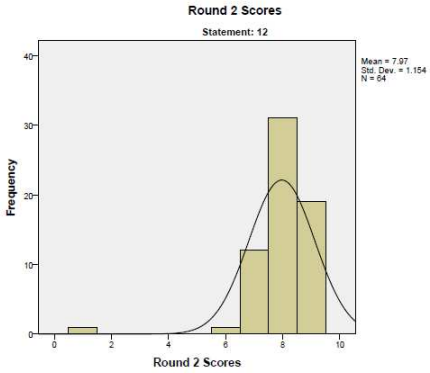

Figure 5k Statement 11

Figure 5l Statement 12

Figure SF7-5 Histograms of Likert Scale score frequencies for statements 1 to 12

Terminology – Delphi domain 2

There were no bimodal distribution in the overall scoring of terminology statements in round 2. (Figure 6)

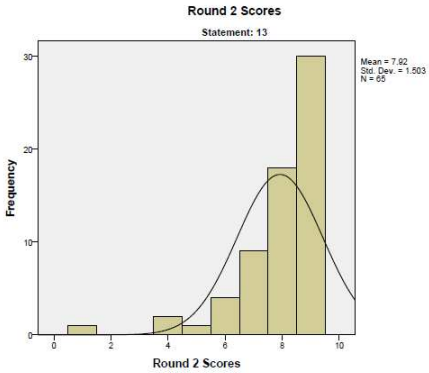

Figure 6a Statement 13

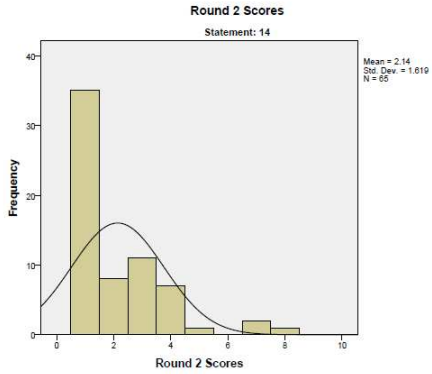

Figure 6b Statement 14

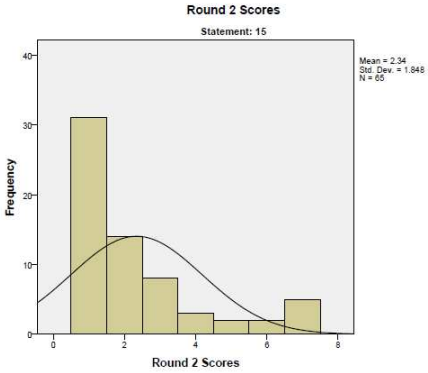

Figure 6c Statement 15

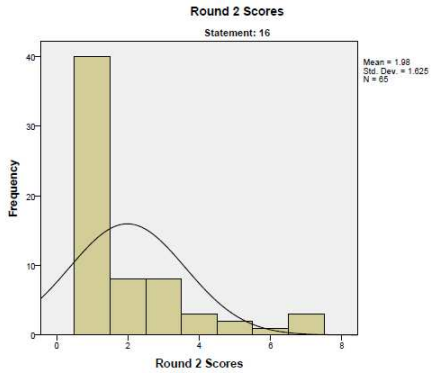

Figure 6d Statement 16

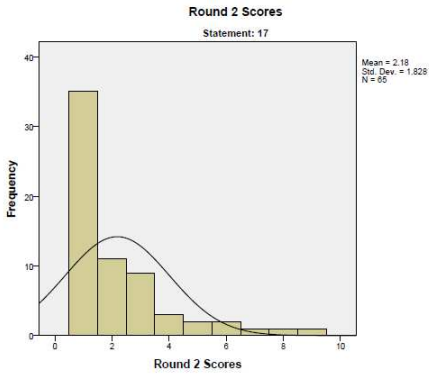

Figure 6e Statement 17

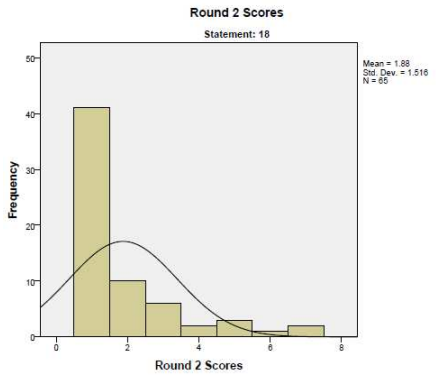

Figure 6f Statement 18

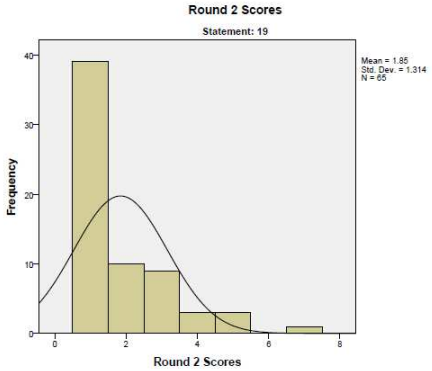

Figure 6g Statement 19

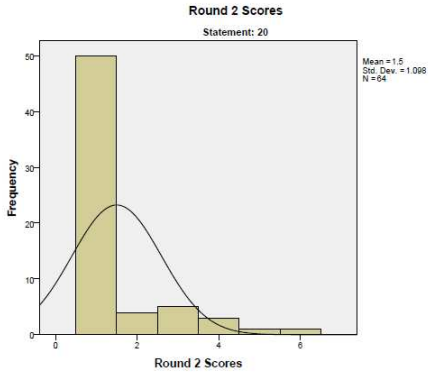

Figure 6h Statement 20

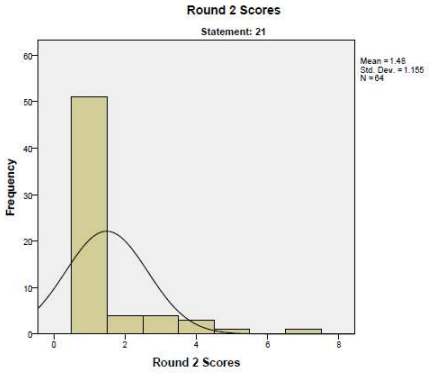

Figure 6i Statement 21

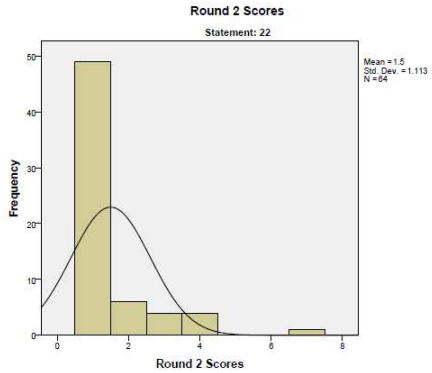

Figure 6j Statement 22

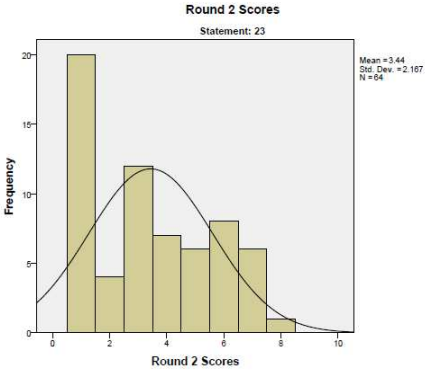

Figure 6k Statement 23

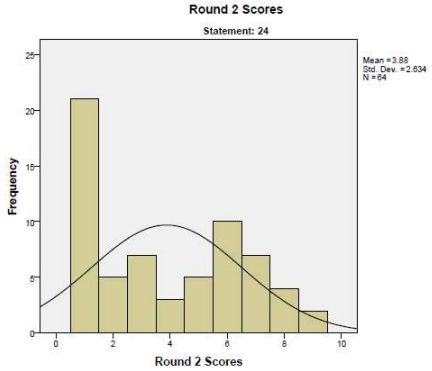

Figure 6l Statement 24

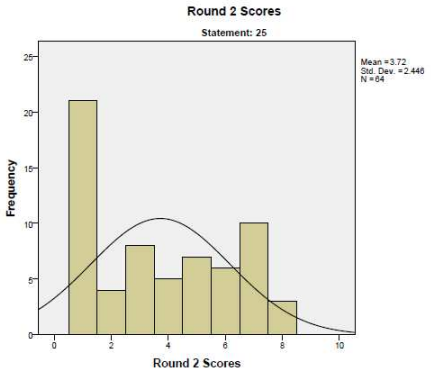

Figure 6m Statement 25

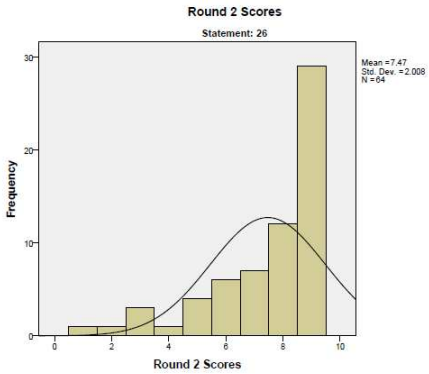

Figure 6n Statement 26

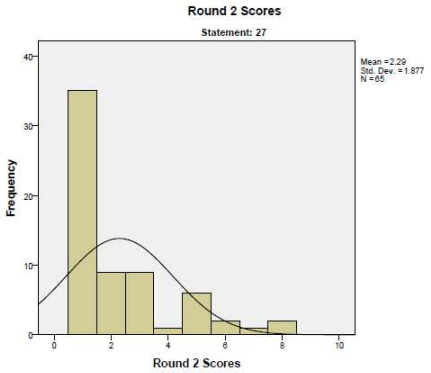

Figure 6o Statement 27

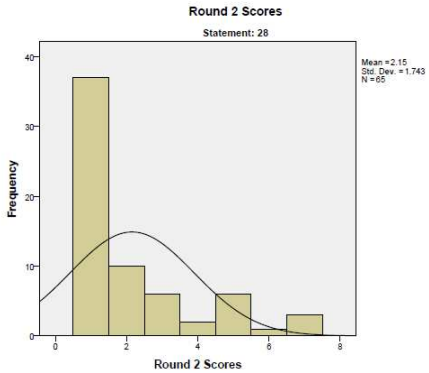

Figure 6p Statement 28

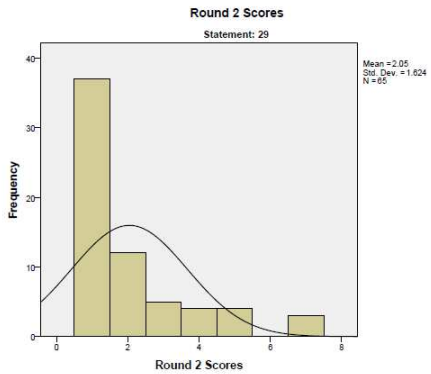

Figure 6q Statement 29

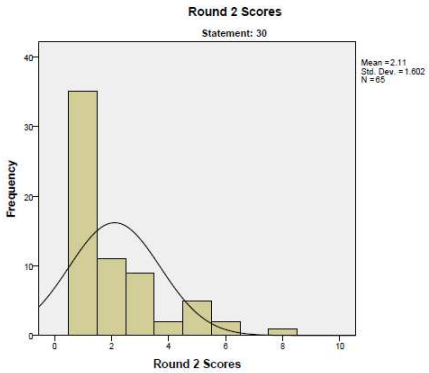

Figure 6r Statement 30

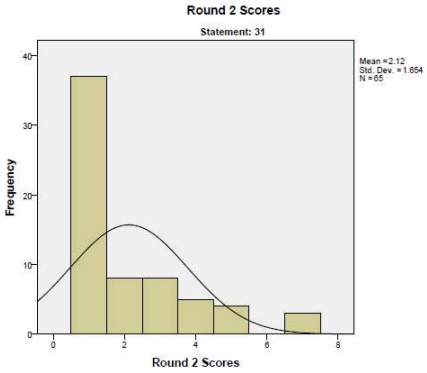

Figure 6s Statement 31

Figure SF7-6 Histograms of Likert Scale score frequencies for statements 13 to 31

Taxonomy – Delphi domain 3

There were no bimodal distribution in the overall scoring of taxonomy statements in round 2. (Figure 7)

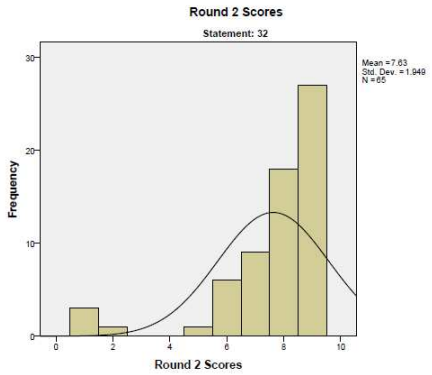

Figure 7a Statement 32

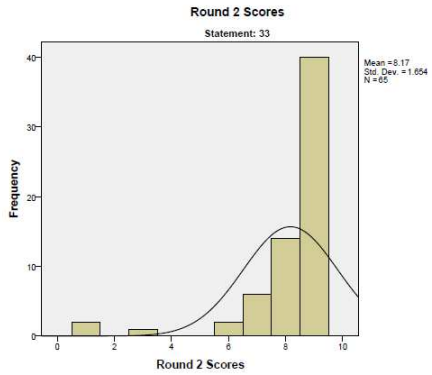

Figure 7b Statement 33

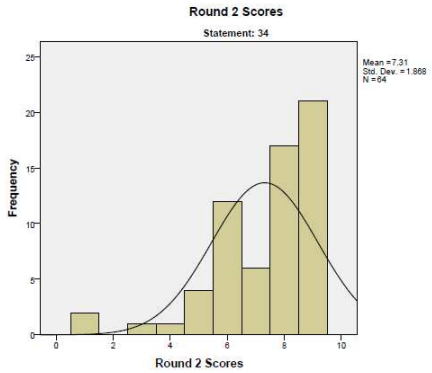

Figure 7c Statement 34

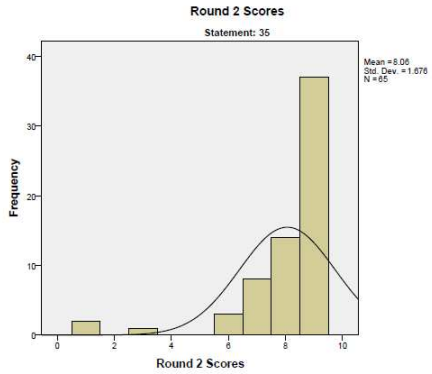

Figure 7d Statement 35

Figure SF7-7 Histograms of Likert Scale score frequencies for statements 32 to 35

Imaging outcomes – Delphi domain 4

There were no bimodal distribution in the overall scoring of imaging outcomes statements in round 2. (Figure 8)

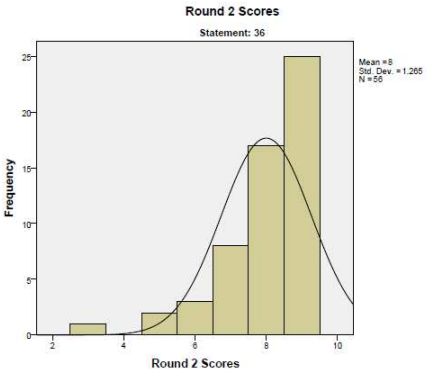

Figure 8a Statement 36

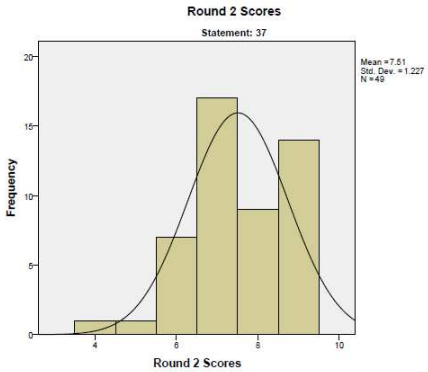

Figure 8b Statement 37

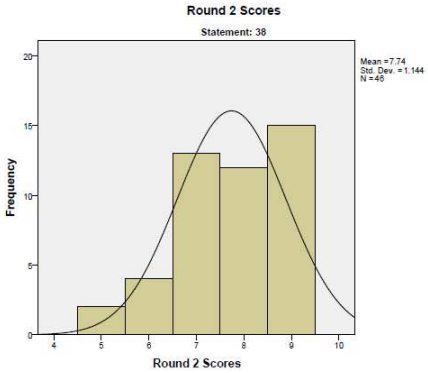

Figure 8c Statement 38

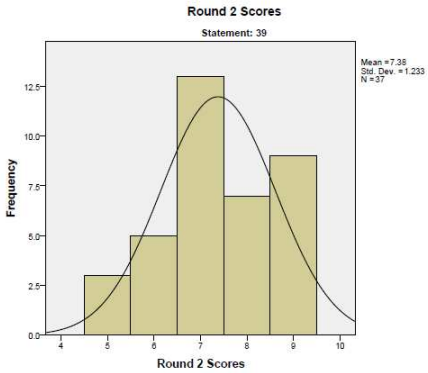

Figure 8d Statement 39

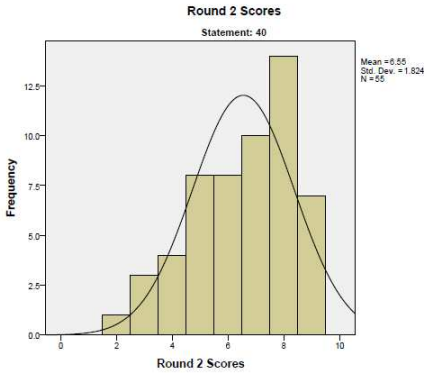

Figure 8e Statement 40

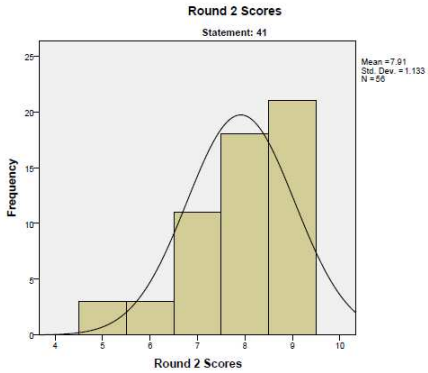

Figure 8f Statement 41

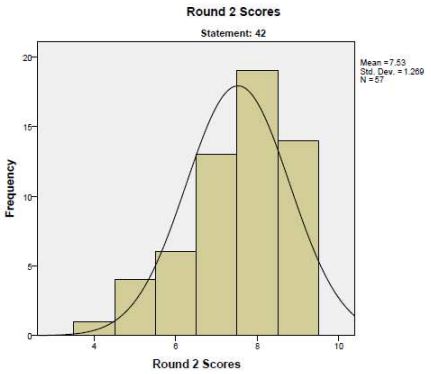

Figure 8g Statement 42

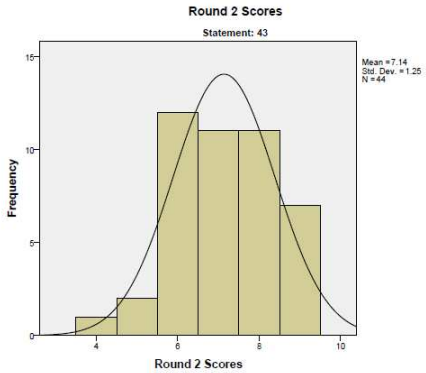

Figure 8h Statement 43

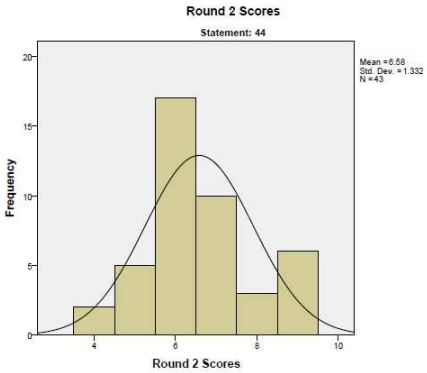

Figure 8i Statement 44

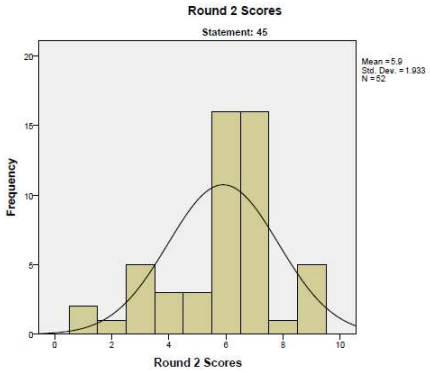

Figure 8j Statement 45

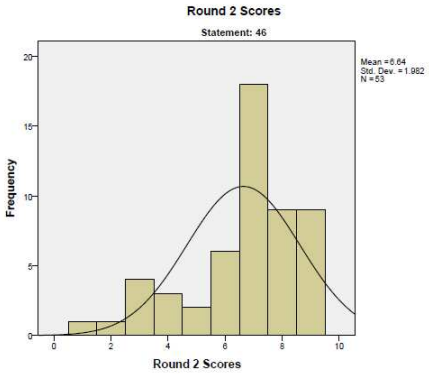

Figure 8k Statement 46

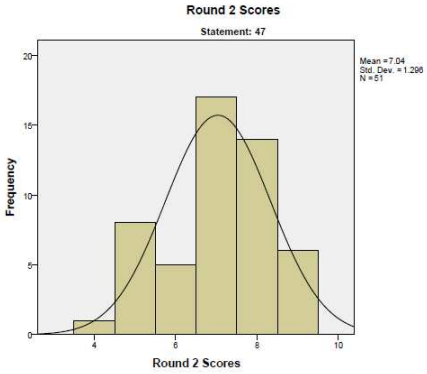

Figure 8l Statement 47

Figure SF7-8 Histograms of Likert Scale score frequencies for statements 36 to 47

Stakeholder Group analysis

Stakeholder group analysis: Stakeholder group analysis, a classical dissent analysis, is important to identify opposing views. To compare the scores from Round 2 between the six stakeholder groups, we performed non-parametric Kruskal-Wallis test (not assuming a normal distribution of the underlying data). To account for multiple post hoc comparisons, we adjusted the statistical significance threshold p-value to 0.003 according to Bonferroni method. However, agreeing with the general view that "a declaration of 'statistical significance' has today become meaningless", [3] substantial stakeholder group differences ($p<0.0033$) prompted us to further scrutinise individual- and group opinions for the specific statement.

Definitions – Delphi domain 1

There was no statistically significant difference in how stakeholder groups scored the definition statements in round 1 and 2.

Table SF7-1 Kruskal-Wallis test to compare Orthopaedic Surgeons vs other stakeholder groups (p-values)

	Orthopaedic surgeons vs PPI		Orthopaedic surgeons vs physical therapists		Orthopaedic surgeons vs physicians		Orthopaedic surgeons vs radiologists		Orthopaedic surgeons vs researchers	
Statement	Round 1	Round 2	Round 1	Round 2	Round 1	Round 2	Round 1	Round 2	Round 1	Round 2
01_Primary cam morphology develops during skeletal maturation as a normal physiological response to load	.694	.310	.837	.857	.629	.807	.379	.155	.103	.094
02_ Primary cam morphology is not caused by previous disease, injury or an acute event; it represents a normal physiological response of the maturing skeleton to load	.666	.611	.400	.108	.678	.511	.953	.296	.285	.380
03_Secondary cam morphology develops due to existing hip disease or acute trauma; including Perthes disease; slipped capital femoral epiphysis, healed proximal femoral fractures or acute fracture	.528	.128	.396	.048	.767	.085	.708	.189	.331	.508
04_ Primary cam morphology develops in young and active individuals, including athletes, likely due to load (e.g., sporting activity) during prepubertal and pubertal skeletal maturation (load during growth) and its (physiological) effect on the proximal femoral growth plate	.572	.258	.453	.746	.265	.691	.522	.219	.016	.021

05_ Primary cam morphology is common in young and active males, including athletes, likely due to sporting activity during prepubertal and pubertal skeletal maturation (load during growth) and its (physiological) effect on the proximal femoral growth plate	.364	.134	.624	.622	.254	.513	.019	.011	.045	.024
06_Primary cam morphology includes cam morphology of unknown origin	.072	.290	.024	.766	.170	.158	.763	.782	.112	1.000
07_Cam morphology that develops in young and active individuals without any symptoms (e.g., hip-related pain; stiffness) or history of previous/existing hip disease, is primary cam morphology until proven otherwise	.527	.121	.212	.110	.229	.012	.471	.825	.901	.578
08_ Cam morphology is a cartilage or bony prominence (bump) of varying size at any location around the femoral head-neck junction, which changes the shape of the femoral head from spherical to aspherical	.131	.028	.409	.015	.652	.028	.293	.042	.741	.832
09_Primary cam morphology often occurs in male athletes in both hips	.891	.900	.936	.807	.899	.700	.437	.398	.162	.047
10_The most common outcome measure for cam morphology is a cartilage or bone alpha angle as a dichotomised or continuous variable on radiographs, computed tomogram (CT) scans or magnetic resonance (MR) imaging, reported per hip, per person or both	.719	.913	.593	.981	.882	.719	.435	.155	.167	.059
11_ Primary cam morphology likely develops during maturation in young adolescents (with no current or previous hip disease), possibly due to high-load sporting activity and other unconfirmed risk factors	.631	.329	.514	.636	.505	.830	.231	.832	.109	.163

12_A comprehensive definition for primary cam morphology would be: Primary cam morphology is a cartilage or bony prominence (bump) of varying size at any location around the femoral head-neck junction, which changes the shape of the femoral head from spherical to aspherical. It often occurs in male athletes in both hips. The most common outcome measure is a cartilage or bone alpha angle as a dichotomised or continuous variable on radiographs, CT scans or MR imaging, reported per hip, per person or both. Primary cam morphology likely develops during maturation in young adolescents (with no current or previous hip disease), possibly due to high-load sporting activity and other unconfirmed risk factors.	.221	.205	.409	.117	.481	.308	.268	.154	.671	.926

Table SF7-2 Kruskal-Wallis test to compare Patient & Public Involvement Group (PPI) vs other stakeholder groups (p-values)

	PPI vs Orthopaedic surgeons		PPI vs physical therapists		PPI vs physicians		PPI vs radiologists		PPI vs researchers	
Statement	Round 1	Round 2	Round 1	Round 2	Round 1	Round 2	Round 1	Round 2	Round 1	Round 2
01_Primary cam morphology develops during skeletal maturation as a normal physiological response to load	.694	.310	.767	.385	.387	.288	.193	.868	.128	.925
02_ Primary cam morphology is not caused by previous disease, injury or an acute event; it represents a normal physiological response of the maturing skeleton to load	.666	.611	.677	.284	.561	.898	.533	.574	.353	.215
03_Secondary cam morphology develops due to existing hip disease or acute trauma; including Perthes disease; slipped	.528	.128	.952	.680	.368	.869	.756	1.000	.165	.314

capital femoral epiphysis, healed proximal femoral fractures or acute fracture										
04_ Primary cam morphology develops in young and active individuals, including athletes, likely due to load (e.g., sporting activity) during prepubertal and pubertal skeletal maturation (load during growth) and its (physiological) effect on the proximal femoral growth plate	.572	.258	.234	.112	.615	.211	.759	.725	.098	.087
05_ Primary cam morphology is common in young and active males, including athletes, likely due to sporting activity during prepubertal and pubertal skeletal maturation (load during growth) and its (physiological) effect on the proximal femoral growth plate	.364	.134	.502	.243	.655	.161	.646	.435	.722	.494
06_Primary cam morphology includes cam morphology of unknown origin	.072	.290	.931	.328	.563	.653	.245	.134	.583	.262
07_Cam morphology that develops in young and active individuals without any symptoms (e.g., hip-related pain; stiffness) or history of previous/existing hip disease, is primary cam morphology until proven otherwise	.527	.121	.419	.918	.540	.254	.231	.122	.468	.291
08_ Cam morphology is a cartilage or bony prominence (bump) of varying size at any location around the femoral head-neck junction, which changes the shape of the femoral head from spherical to aspherical	.131	.028	.363	.955	.175	.679	.687	.855	.037	.022
09_Primary cam morphology often occurs in male athletes in both hips	.891	.900	.877	.885	.912	.835	.738	.498	.185	.062
10_The most common outcome measure for cam morphology is a cartilage or bone alpha angle as a dichotomised or continuous variable on radiographs,	.719	.913	.353	.755	.769	.389	.305	.039	.266	.016

computed tomogram (CT) scans or magnetic resonance (MR) imaging, reported per hip, per person or both										
11_ Primary cam morphology likely develops during maturation in young adolescents (with no current or previous hip disease), possibly due to high-load sporting activity and other unconfirmed risk factors	.631	.329	.836	.606	.944	.184	.431	.242	.226	.326
12_A comprehensive definition for primary cam morphology would be: Primary cam morphology is a cartilage or bony prominence (bump) of varying size at any location around the femoral head-neck junction, which changes the shape of the femoral head from spherical to aspherical. It often occurs in male athletes in both hips. The most common outcome measure is a cartilage or bone alpha angle as a dichotomised or continuous variable on radiographs, CT scans or MR imaging, reported per hip, per person or both. Primary cam morphology likely develops during maturation in young adolescents (with no current or previous hip disease), possibly due to high-load sporting activity and other unconfirmed risk factors.	.221	.205	.592	.865	.465	.689	.953	.811	.123	.167

Table SF7-3 Kruskal-Wallis test to compare Physical Therapists vs other stakeholder groups (p-values)

	Physical Therapists vs Orthopaedic surgeons		Physical therapists vs PPI		Physical Therapists vs physicians		Physical Therapists vs radiologists		Physical Therapists vs researchers	
Statement	Round 1	Round 2	Round 1	Round 2	Round 1	Round 2	Round 1	Round 2	Round 1	Round 2
01_Primary cam morphology develops during skeletal maturation as a normal physiological response to load	.837	.857	.767	.385	.487	.982	.343	.234	.087	.152
02_ Primary cam morphology is not caused by previous disease, injury or an acute event; it represents a normal physiological response of the maturing skeleton to load	.400	.108	.677	.284	.186	.225	.550	.485	.050	.008
03_Secondary cam morphology develops due to existing hip disease or acute trauma; including Perthes disease; slipped capital femoral epiphysis, healed proximal femoral fractures or acute fracture	.396	.048	.952	.680	.371	.663	.787	.490	.097	.213
04_ Primary cam morphology develops in young and active individuals, including athletes, likely due to load (e.g., sporting activity) during prepubertal and pubertal skeletal maturation (load during growth) and its (physiological) effect on the proximal femoral growth plate	.453	.746	.234	.112	.055	.371	.231	.112	.006	.007
05_ Primary cam morphology is common in young and active males, including athletes, likely due to sporting activity during prepubertal and pubertal skeletal maturation (load during growth) and its (physiological) effect on the proximal femoral growth plate	.624	.622	.502	.243	.855	.926	.101	.031	.142	.048
06_Primary cam morphology includes cam morphology of unknown origin	.024	.766	.931	.328	.583	.192	.293	.366	.545	.800
07_Cam morphology that develops in young and active individuals without any	.212	.110	.419	.918	.804	.324	.093	.080	.198	.280

symptoms (e.g., hip-related pain; stiffness) or history of previous/existing hip disease, is primary cam morphology until proven otherwise										
08_ Cam morphology is a cartilage or bony prominence (bump) of varying size at any location around the femoral head-neck junction, which changes the shape of the femoral head from spherical to aspherical	.409	.015	.363	.955	.690	.647	.647	.906	.243	.021
09_Primary cam morphology often occurs in male athletes in both hips	.936	.807	.877	.885	.964	.680	.475	.404	.214	.038
10_The most common outcome measure for cam morphology is a cartilage or bone alpha angle as a dichotomised or continuous variable on radiographs, computed tomogram (CT) scans or magnetic resonance (MR) imaging, reported per hip, per person or both	.593	.981	.353	.755	.400	.863	.562	.120	.041	.032
11_ Primary cam morphology likely develops during maturation in young adolescents (with no current or previous hip disease), possibly due to high-load sporting activity and other unconfirmed risk factors	.514	.636	.836	.606	.928	.595	.568	.669	.386	.211
12_A comprehensive definition for primary cam morphology would be: Primary cam morphology is a cartilage or bony prominence (bump) of varying size at any location around the femoral head-neck junction, which changes the shape of the femoral head from spherical to aspherical. It often occurs in male athletes in both hips. The most common outcome measure is a cartilage or bone alpha angle as a dichotomised or continuous variable	.409	.117	.592	.865	.889	.525	.609	.936	.249	.095

on radiographs, CT scans or MR imaging, reported per hip, per person or both. Primary cam morphology likely develops during maturation in young adolescents (with no current or previous hip disease), possibly due to high-load sporting activity and other unconfirmed risk factors.

Table SF7-4 Kruskal-Wallis test to compare Physicians vs other stakeholder groups (p-values)

	Physicians vs Orthopaedic surgeons		Physicians vs PPI		Physicians vs Physical Therapists		Physicians vs radiologists		Physicians vs researchers	
Statement	Round 1	Round 2	Round 1	Round 2	Round 1	Round 2	Round 1	Round 2	Round 1	Round 2
01_Primary cam morphology develops during skeletal maturation as a normal physiological response to load	.629	.807	.387	.288	.487	.982	.716	.186	.196	.069
02_ Primary cam morphology is not caused by previous disease, injury or an acute event; it represents a normal physiological response of the maturing skeleton to load	.678	.511	.561	.898	.186	.225	.412	.574	.318	.059
03_Secondary cam morphology develops due to existing hip disease or acute trauma; including Perthes disease; slipped capital femoral epiphysis, healed proximal femoral fractures or acute fracture	.767	.085	.368	.869	.371	.663	.340	.924	.251	.216
04_ Primary cam morphology develops in young and active individuals, including athletes, likely due to load (e.g., sporting activity) during prepubertal and pubertal skeletal maturation (load during growth) and its (physiological) effect on the proximal femoral growth plate	.265	.691	.615	.211	.055	.371	.775	.181	.174	.005
05_ Primary cam morphology is common in young and active males, including	.254	.513	.655	.161	.855	.926	.039	.004	.064	.015

athletes, likely due to sporting activity during prepubertal and pubertal skeletal maturation (load during growth) and its (physiological) effect on the proximal femoral growth plate										
06_Primary cam morphology includes cam morphology of unknown origin	.170	.158	.563	.653	.583	.192	.740	.140	.869	.151
07_Cam morphology that develops in young and active individuals without any symptoms (e.g., hip-related pain; stiffness) or history of previous/existing hip disease, is primary cam morphology until proven otherwise	.229	.012	.540	.254	.804	.324	.074	.031	.175	.049
08_ Cam morphology is a cartilage or bony prominence (bump) of varying size at any location around the femoral head-neck junction, which changes the shape of the femoral head from spherical to aspherical	.652	.028	.175	.679	.690	.647	.378	.552	.194	.019
09_Primary cam morphology often occurs in male athletes in both hips	.899	.700	.912	.835	.964	.680	.422	.311	.149	.016
10_The most common outcome measure for cam morphology is a cartilage or bone alpha angle as a dichotomised or continuous variable on radiographs, computed tomogram (CT) scans or magnetic resonance (MR) imaging, reported per hip, per person or both	.882	.719	.769	.389	.400	.863	.235	.079	.101	.006
11_ Primary cam morphology likely develops during maturation in young adolescents (with no current or previous hip disease), possibly due to high-load sporting activity and other unconfirmed risk factors	.505	.830	.944	.184	.928	.595	.465	1.000	.174	.081
12_A comprehensive definition for primary cam morphology would be:	.481	.308	.465	.689	.889	.525	.480	.498	.254	.291

Primary cam morphology is a cartilage or bony prominence (bump) of varying size at any location around the femoral head-neck junction, which changes the shape of the femoral head from spherical to aspherical. It often occurs in male athletes in both hips. The most common outcome measure is a cartilage or bone alpha angle as a dichotomised or continuous variable on radiographs, CT scans or MR imaging, reported per hip, per person or both. Primary cam morphology likely develops during maturation in young adolescents (with no current or previous hip disease), possibly due to high-load sporting activity and other unconfirmed risk factors.	

Table SF7-5 Kruskal-Wallis test to compare Radiologists vs other stakeholder groups (p-values)

	Radiologists vs Orthopaedic surgeons		Radiologists vs PPI		Radiologists vs Physical Therapists		Radiologists vs Physicians		Radiologists vs Researchers	
Statement	Round 1	Round 2	Round 1	Round 2	Round 1	Round 2	Round 1	Round 2	Round 1	Round 2
01_Primary cam morphology develops during skeletal maturation as a normal physiological response to load	.379	.155	.193	.868	.343	.234	.716	.186	.499	.763
02_ Primary cam morphology is not caused by previous disease, injury or an acute event; it represents a normal physiological response of the maturing skeleton to load	.953	.296	.533	.574	.550	.485	.412	.574	.071	.009
03_Secondary cam morphology develops due to existing hip disease or acute trauma; including Perthes disease; slipped capital femoral epiphysis, healed proximal femoral fractures or acute fracture	.708	.189	.756	1.000	.787	.490	.340	.924	.101	.361

04_ Primary cam morphology develops in young and active individuals, including athletes, likely due to load (e.g., sporting activity) during prepubertal and pubertal skeletal maturation (load during growth) and its (physiological) effect on the proximal femoral growth plate	.522	.219	.759	.725	.231	.112	.775	.181	.463	.376
05_ Primary cam morphology is common in young and active males, including athletes, likely due to sporting activity during prepubertal and pubertal skeletal maturation (load during growth) and its (physiological) effect on the proximal femoral growth plate	.019	.011	.646	.435	.101	.031	.039	.004	.881	1.000
06_Primary cam morphology includes cam morphology of unknown origin	.763	.782	.245	.134	.293	.366	.740	.140	.709	.690
07_Cam morphology that develops in young and active individuals without any symptoms (e.g., hip-related pain; stiffness) or history of previous/existing hip disease, is primary cam morphology until proven otherwise	.471	.825	.231	.122	.093	.080	.074	.031	.458	.202
08_ Cam morphology is a cartilage or bony prominence (bump) of varying size at any location around the femoral head-neck junction, which changes the shape of the femoral head from spherical to aspherical	.293	.042	.687	.855	.647	.906	.378	.552	.065	.026
09_Primary cam morphology often occurs in male athletes in both hips	.437	.398	.738	.498	.475	.404	.422	.311	.683	.367
10_The most common outcome measure for cam morphology is a cartilage or bone alpha angle as a dichotomised or continuous variable on radiographs, computed tomogram (CT) scans or	.435	.155	.305	.039	.562	.120	.235	.079	.059	.006

magnetic resonance (MR) imaging, reported per hip, per person or both										
11_ Primary cam morphology likely develops during maturation in young adolescents (with no current or previous hip disease), possibly due to high-load sporting activity and other unconfirmed risk factors	.231	.832	.431	.242	.568	.669	.465	1.000	.715	.139
12_A comprehensive definition for primary cam morphology would be: Primary cam morphology is a cartilage or bony prominence (bump) of varying size at any location around the femoral head-neck junction, which changes the shape of the femoral head from spherical to aspherical. It often occurs in male athletes in both hips. The most common outcome measure is a cartilage or bone alpha angle as a dichotomised or continuous variable on radiographs, CT scans or MR imaging, reported per hip, per person or both. Primary cam morphology likely develops during maturation in young adolescents (with no current or previous hip disease), possibly due to high-load sporting activity and other unconfirmed risk factors.	.268	.154	.953	.811	.609	.936	.480	.498	.154	.052

Table SF7-6 Kruskal-Wallis test to compare Researchers vs other stakeholder groups (p-values)

	Researchers vs Orthopaedic surgeons		Researchers vs PPI		Researchers vs Physical Therapists		Researchers vs Physicians		Researchers vs Radiologists	
Statement	Round 1	Round 2	Round 1	Round 2	Round 1	Round 2	Round 1	Round 2	Round 1	Round 2
01_Primary cam morphology develops during skeletal maturation as a normal physiological response to load	.103	.094	.128	.925	.087	.152	.196	.069	.499	.763

02_ Primary cam morphology is not caused by previous disease, injury or an acute event; it represents a normal physiological response of the maturing skeleton to load	.285	.380	.353	.215	.050	.008	.318	.059	.071	.009
03_Secondary cam morphology develops due to existing hip disease or acute trauma; including Perthes disease; slipped capital femoral epiphysis, healed proximal femoral fractures or acute fracture	.331	.508	.165	.314	.097	.213	.251	.216	.101	.361
04_ Primary cam morphology develops in young and active individuals, including athletes, likely due to load (e.g., sporting activity) during prepubertal and pubertal skeletal maturation (load during growth) and its (physiological) effect on the proximal femoral growth plate	.016	.021	.098	.087	.006	.007	.174	.005	.463	.376
05_ Primary cam morphology is common in young and active males, including athletes, likely due to sporting activity during prepubertal and pubertal skeletal maturation (load during growth) and its (physiological) effect on the proximal femoral growth plate	.045	.024	.722	.494	.142	.048	.064	.015	.881	1.000
06_Primary cam morphology includes cam morphology of unknown origin	.112	1.000	.583	.262	.545	.800	.869	.151	.709	.690
07_Cam morphology that develops in young and active individuals without any symptoms (e.g., hip-related pain; stiffness) or history of previous/existing hip disease, is primary cam morphology until proven otherwise	.901	.578	.468	.291	.198	.280	.175	.049	.458	.202
08_ Cam morphology is a cartilage or bony prominence (bump) of varying size at any location around the femoral head-neck junction, which changes the shape of	.741	.832	.037	.022	.243	.021	.194	.019	.065	.026

the femoral head from spherical to aspherical										
09_Primary cam morphology often occurs in male athletes in both hips	.162	.047	.185	.062	.214	.038	.149	.016	.683	.367
10_The most common outcome measure for cam morphology is a cartilage or bone alpha angle as a dichotomised or continuous variable on radiographs, computed tomogram (CT) scans or magnetic resonance (MR) imaging, reported per hip, per person or both	.167	.059	.266	.016	.041	.032	.101	.006	.059	.006
11_ Primary cam morphology likely develops during maturation in young adolescents (with no current or previous hip disease), possibly due to high-load sporting activity and other unconfirmed risk factors	.109	.163	.226	.326	.386	.211	.174	.081	.715	.139
12_A comprehensive definition for primary cam morphology would be: Primary cam morphology is a cartilage or bony prominence (bump) of varying size at any location around the femoral head-neck junction, which changes the shape of the femoral head from spherical to aspherical. It often occurs in male athletes in both hips. The most common outcome measure is a cartilage or bone alpha angle as a dichotomised or continuous variable on radiographs, CT scans or MR imaging, reported per hip, per person or both. Primary cam morphology likely develops during maturation in young adolescents (with no current or previous hip disease), possibly due to high-load sporting activity and other unconfirmed risk factors.	.671	.926	.123	.167	.249	.095	.254	.291	.154	.052

Terminology – Delphi domain 2

The average scores for some of the terminology statements were statistically significant different for the physical therapist stakeholder group compared to the researcher stakeholder group (Statement 23, round 1, p<0.0033; Statement 24, round 1, p<0.001 and round 2, p<0.002), and for the radiologist stakeholder group compared to the researcher stakeholder group (Statement 24, round 2, p<0.0033).

Table SF7-7 Kruskal-Wallis test to compare Orthopaedic Surgeons vs other stakeholder groups (p-values)

	Orthopaedic surgeons vs PPI		Orthopaedic surgeons vs physical therapists		Orthopaedic surgeons vs physicians		Orthopaedic surgeons vs radiologists		Orthopaedic surgeons vs researchers	
Statement	Round 1	Round 2	Round 1	Round 2	Round 1	Round 2	Round 1	Round 2	Round 1	Round 2
13_Cam morphology is the preferred term to use for a bone/cartilage bump at any location around the femoral head-neck junction	.022	.004	.005	.001	.025	.004	.044	.014	.117	.065
14_Cam lesion is the preferred term to use for a bone/cartilage bump at any location around the femoral head-neck junction	.969	.797	.030	.014	.287	.291	.271	.190	.925	.637
15_Cam deformity is the preferred term to use for a bone/cartilage bump at any location around the femoral head-neck junction	.248	.350	.003	.028	.042	.119	.100	.009	.337	.967
16_Cam abnormality is the preferred term to use for a bone/cartilage bump at any location around the femoral head-neck junction	.401	.388	.110	.059	.327	.228	.064	.018	.853	.764
17_Cam-type deformity is the preferred term to use for a bone/cartilage bump at any location around the femoral head-neck junction	.576	.512	.216	.099	.464	.195	.301	.018	.781	.832
18_Cam-type abnormality is the preferred term to use for a bone/cartilage bump at any location	.515	.369	.434	.035	.695	.205	.383	.018	.814	.698

around the femoral head-neck junction										
19_Cam-type lesion is the preferred term to use for a bone/cartilage bump at any location around the femoral head-neck junction	.496	.399	.069	.007	.253	.119	.057	.008	.926	.437
20_Pistol grip deformity is the preferred term to use for a bone/cartilage bump at any location around the femoral head-neck junction	.858	.507	.957	.329	.913	.321	.533	.105	.156	.957
21_Pistol grip lesion is the preferred term to use for a bone/cartilage bump at any location around the femoral head-neck junction	.929	.741	.830	.687	.971	.568	.906	.174	.141	.863
22_Pistol grip abnormality is the preferred term to use for a bone/cartilage bump at any location around the femoral head-neck junction	.858	.536	.915	.239	.726	.341	.768	.348	.156	.641
23_Cam-type impingement is the preferred term to use for hip-related pain due to a bony bump at any location around the femoral head-neck junction	.106	.369	.006	.022	.247	.217	.058	.033	.713	.646
24_Cam femoroacetabular impingement (FAI) is the preferred term to use for hip-related pain due to a bony bump at any location around the femoral head-neck junction	.416	.353	.463	.611	.610	.953	.675	.081	.019	.081
25_Cam-type femoroacetabular impingement (FAI) is the preferred term to use for hip-related pain due to	.638	.665	.789	.628	.545	.658	.959	.276	.613	.890

a bony bump at any location around the femoral head-neck junction										
26_Femoroacetabular impingement (FAI) Syndrome with cam morphology is the preferred term to use for hip-related pain due to a bony bump at any location around the femoral head-neck junction	.276	.077	.250	.009	.028	.003	.063	.021	.271	.119
27_Femoroacetabular impingement (FAI) Syndrome with cam deformity is the preferred term to use for hip-related pain due	.183	.227	.018	.010	.255	.155	.174	.009	.270	.129
28_Femoroacetabular impingement (FAI) Syndrome with cam abnormality is the preferred term to use for hip-related pain due to a bony bump at any location around the femoral head-neck junction	.386	.268	.081	.030	.704	.275	.295	.009	.889	.522
29_Femoroacetabular impingement (FAI) Syndrome with cam lesion is the preferred term to use for hip-related pain due to a bony bump at any location around the femoral head-neck junction	.667	.512	.052	.006	.658	.159	.295	.009	.963	.445
30_Femoroacetabular impingement (FAI) Syndrome with cam-type abnormality is the preferred term to use for hip-related pain due to a bony bump at any location around the femoral head-neck junction	.756	.913	.129	.022	.705	.312	.296	.009	.963	.639
31_Femoroacetabular impingement (FAI) Syndrome with cam-type deformity is the preferred term to use	.507	.660	.041	.006	.468	.312	.210	.009	.614	.525

for hip-related pain due to a bony bump at any location around the femoral head-neck junction

Table SF7-8 Kruskal-Wallis test to compare Patient & Public Involvement Group (PPI) vs other stakeholder groups (p-values)

	PPI vs Orthopaedic surgeons		PPI vs physical therapists		PPI vs physicians		PPI vs radiologists		PPI vs researchers	
Statement	Round 1	Round 2	Round 1	Round 2	Round 1	Round 2	Round 1	Round 2	Round 1	Round 2
13_Cam morphology is the preferred term to use for a bone/cartilage bump at any location around the femoral head-neck junction	.022	.004	.507	.673	.835	.514	1.000	.853	.342	.037
14_Cam lesion is the preferred term to use for a bone/cartilage bump at any location around the femoral head-neck junction	.969	.797	.126	.022	.538	.347	.480	.230	.869	.539
15_Cam deformity is the preferred term to use for a bone/cartilage bump at any location around the femoral head-neck junction	.248	.350	.161	.093	.345	.246	.418	.011	.665	.290
16_Cam abnormality is the preferred term to use for a bone/cartilage bump at any location around the femoral head-neck junction	.401	.388	.616	.472	.937	.770	.231	.087	.372	.317
17_Cam-type deformity is the preferred term to use for a bone/cartilage bump at any location around the femoral head-neck junction	.576	.512	.449	.208	.787	.408	.561	.024	.224	.610
18_Cam-type abnormality is the preferred term to use for a bone/cartilage bump at any location	.515	.369	.837	.352	.817	.743	.738	.087	.537	.732

around the femoral head-neck junction										
19_Cam-type lesion is the preferred term to use for a bone/cartilage bump at any location around the femoral head-neck junction	.496	.399	.416	.170	.723	.503	.205	.048	.441	.962
20_Pistol grip deformity is the preferred term to use for a bone/cartilage bump at any location around the femoral head-neck junction	.858	.507	.829	.972	1.000	.814	.462	.258	.159	.555
21_Pistol grip lesion is the preferred term to use for a bone/cartilage bump at any location around the femoral head-neck junction	.929	.741	.829	.972	.966	.814	.833	.258	.158	.598
22_Pistol grip abnormality is the preferred term to use for a bone/cartilage bump at any location around the femoral head-neck junction	.858	.536	.781	.739	.597	.814	.888	.750	.158	.331
23_Cam-type impingement is the preferred term to use for hip-related pain due to a bony bump at any location around the femoral head-neck junction	.106	.369	.091	.171	.512	.706	.326	.104	.046	.459
24_Cam femoroacetabular impingement (FAI) is the preferred term to use for hip-related pain due to a bony bump at any location around the femoral head-neck junction	.416	.353	.029	.019	.242	.376	.206	.017	.052	.236
25_Cam-type femoroacetabular impingement (FAI) is the preferred term to use for hip-related pain due to	.638	.665	.302	.243	.185	.241	.507	.178	.667	.428

a bony bump at any location around the femoral head-neck junction										
26_Femoroacetabular impingement (FAI) Syndrome with cam morphology is the preferred term to use for hip-related pain due to a bony bump at any location around the femoral head-neck junction	.276	.077	.934	.592	.133	.168	.261	.382	.626	.879
27_Femoroacetabular impingement (FAI) Syndrome with cam deformity is the preferred term to use for hip-related pain due	.183	.227	.175	.192	.940	.762	.477	.047	.869	.674
28_Femoroacetabular impingement (FAI) Syndrome with cam abnormality is the preferred term to use for hip-related pain due to a bony bump at any location around the femoral head-neck junction	.386	.268	.509	.486	.623	.837	.739	.086	.542	.695
29_Femoroacetabular impingement (FAI) Syndrome with cam lesion is the preferred term to use for hip-related pain due to a bony bump at any location around the femoral head-neck junction	.667	.512	.125	.081	.882	.537	.480	.047	.829	.888
30_Femoroacetabular impingement (FAI) Syndrome with cam-type abnormality is the preferred term to use for hip-related pain due to a bony bump at any location around the femoral head-neck junction	.756	.913	.236	.040	.971	.373	.418	.012	.871	.712
31_Femoroacetabular impingement (FAI) Syndrome with cam-type deformity is the preferred term to use	.507	.660	.186	.092	.911	.655	.442	.048	.957	1.000

for hip-related pain due to a bony bump at any location around the femoral head-neck junction

Table SF7-9 Kruskal-Wallis test to compare Physical Therapists vs other stakeholder groups

	Physical Therapists vs Orthopaedic surgeons		Physical therapists vs PPI		Physical Therapists vs physicians		Physical Therapists vs radiologists		Physical Therapists vs researchers	
Statement	Round 1	Round 2	Round 1	Round 2	Round 1	Round 2	Round 1	Round 2	Round 1	Round 2
13_Cam morphology is the preferred term to use for a bone/cartilage bump at any location around the femoral head-neck junction	.005	.001	.507	.673	.339	.251	.450	.532	.075	.012
14_Cam lesion is the preferred term to use for a bone/cartilage bump at any location around the femoral head-neck junction	.030	.014	.126	.022	.619	.277	.968	.884	.013	.000
15_Cam deformity is the preferred term to use for a bone/cartilage bump at any location around the femoral head-neck junction	.003	.028	.161	.093	.770	.849	.907	.069	.045	.010
16_Cam abnormality is the preferred term to use for a bone/cartilage bump at any location around the femoral head-neck junction	.110	.059	.616	.472	.789	.737	.263	.145	.113	.070
17_Cam-type deformity is the preferred term to use for a bone/cartilage bump at any location around the femoral head-neck junction	.216	.099	.449	.208	.789	.981	.907	.069	.027	.065
18_Cam-type abnormality is the preferred term to use for a	.434	.035	.837	.352	.666	.679	.756	.144	.265	.172

bone/cartilage bump at any location around the femoral head-neck junction										
19_Cam-type lesion is the preferred term to use for a bone/cartilage bump at any location around the femoral head-neck junction	.069	.007	.416	.170	.673	.679	.320	.144	.028	.172
20_Pistol grip deformity is the preferred term to use for a bone/cartilage bump at any location around the femoral head-neck junction	.957	.329	.829	.972	.899	.742	.436	.203	.069	.558
21_Pistol grip lesion is the preferred term to use for a bone/cartilage bump at any location around the femoral head-neck junction	.830	.687	.829	.972	.899	.742	.968	.203	.074	.558
22_Pistol grip abnormality is the preferred term to use for a bone/cartilage bump at any location around the femoral head-neck junction	.915	.239	.781	.739	.728	1.000	.689	.915	.103	.143
23_Cam-type impingement is the preferred term to use for hip-related pain due to a bony bump at any location around the femoral head-neck junction	.006	.022	.091	.171	.089	.331	.759	.389	.003	.033
24_Cam femoroacetabular impingement (FAI) is the preferred term to use for hip-related pain due to a bony bump at any location around the femoral head-neck junction	.463	.611	.029	.019	.489	.183	.825	.109	.000	.001
25_Cam-type femoroacetabular impingement (FAI) is the preferred	.789	.628	.302	.243	.853	.730	.913	.441	.191	.672

term to use for hip-related pain due to a bony bump at any location around the femoral head-neck junction										
26_Femoroacetabular impingement (FAI) Syndrome with cam morphology is the preferred term to use for hip-related pain due to a bony bump at any location around the femoral head-neck junction	.250	.009	.934	.592	.104	.328	.124	.569	.974	.349
27_Femoroacetabular impingement (FAI) Syndrome with cam deformity is the preferred term to use for hip-related pain due	.018	.010	.175	.192	.180	.308	.968	.101	.138	.217
28_Femoroacetabular impingement (FAI) Syndrome with cam abnormality is the preferred term to use for hip-related pain due to a bony bump at any location around the femoral head-neck junction	.081	.030	.509	.486	.180	.433	.968	.102	.183	.306
29_Femoroacetabular impingement (FAI) Syndrome with cam lesion is the preferred term to use for hip-related pain due to a bony bump at any location around the femoral head-neck junction	.052	.006	.125	.081	.144	.378	.901	.142	.048	.045
30_Femoroacetabular impingement (FAI) Syndrome with cam-type abnormality is the preferred term to use for hip-related pain due to a bony bump at any location around the femoral head-neck junction	.129	.022	.236	.040	.261	.451	.905	.101	.232	.261
31_Femoroacetabular impingement (FAI) Syndrome with cam-type	.041	.006	.186	.092	.196	.282	.968	.144	.064	.054

deformity is the preferred term to use for hip-related pain due to a bony bump at any location around the femoral head-neck junction

Table SF7-10 Kruskal-Wallis test to compare Physicians vs other stakeholder groups (p-values)

	Physicians vs Orthopaedic surgeons		Physicians vs PPI		Physicians vs Physical Therapists		Physicians vs radiologists		Physicians vs researchers	
Statement	Round 1	Round 2	Round 1	Round 2	Round 1	Round 2	Round 1	Round 2	Round 1	Round 2
13_Cam morphology is the preferred term to use for a bone/cartilage bump at any location around the femoral head-neck junction	.025	.004	.835	.514	.339	.251	.884	.663	.413	.089
14_Cam lesion is the preferred term to use for a bone/cartilage bump at any location around the femoral head-neck junction	.287	.291	.538	.347	.619	.277	.873	.523	.231	.045
15_Cam deformity is the preferred term to use for a bone/cartilage bump at any location around the femoral head-neck junction	.042	.119	.345	.246	.770	.849	.873	.089	.171	.062
16_Cam abnormality is the preferred term to use for a bone/cartilage bump at any location around the femoral head-neck junction	.327	.228	.937	.770	.789	.737	.264	.140	.282	.227
17_Cam-type deformity is the preferred term to use for a bone/cartilage bump at any location around the femoral head-neck junction	.464	.195	.787	.408	.789	.981	.709	.140	.200	.207

18_Cam-type abnormality is the preferred term to use for a bone/cartilage bump at any location around the femoral head-neck junction	.695	.205	.817	.743	.666	.679	.571	.140	.564	.455
19_Cam-type lesion is the preferred term to use for a bone/cartilage bump at any location around the femoral head-neck junction	.253	.119	.723	.503	.673	.679	.264	.140	.158	.506
20_Pistol grip deformity is the preferred term to use for a bone/cartilage bump at any location around the femoral head-neck junction	.913	.321	1.000	.814	.899	.742	.455	.324	.110	.428
21_Pistol grip lesion is the preferred term to use for a bone/cartilage bump at any location around the femoral head-neck junction	.971	.568	.966	.814	.899	.742	.867	.324	.148	.496
22_Pistol grip abnormality is the preferred term to use for a bone/cartilage bump at any location around the femoral head-neck junction	.726	.341	.597	.814	.728	1.000	.522	.945	.366	.231
23_Cam-type impingement is the preferred term to use for hip-related pain due to a bony bump at any location around the femoral head-neck junction	.247	.217	.512	.706	.089	.331	.265	.156	.213	.351
24_Cam femoroacetabular impingement (FAI) is the preferred term to use for hip-related pain due to a bony bump at any location around the femoral head-neck junction	.610	.953	.242	.376	.489	.183	.731	.036	.003	.023

25_Cam-type femoroacetabular impingement (FAI) is the preferred term to use for hip-related pain due to a bony bump at any location around the femoral head-neck junction	.545	.658	.185	.241	.853	.730	.961	.366	.275	.777
26_Femoroacetabular impingement (FAI) Syndrome with cam morphology is the preferred term to use for hip-related pain due to a bony bump at any location around the femoral head-neck junction	.028	.003	.133	.168	.104	.328	.883	.760	.179	.098
27_Femoroacetabular impingement (FAI) Syndrome with cam deformity is the preferred term to use for hip-related pain due	.255	.155	.940	.762	.180	.308	.451	.055	1.000	.908
28_Femoroacetabular impingement (FAI) Syndrome with cam abnormality is the preferred term to use for hip-related pain due to a bony bump at any location around the femoral head-neck junction	.704	.275	.623	.837	.180	.433	.482	.055	.862	.783
29_Femoroacetabular impingement (FAI) Syndrome with cam lesion is the preferred term to use for hip-related pain due to a bony bump at any location around the femoral head-neck junction	.658	.159	.882	.537	.144	.378	.452	.089	.729	.409
30_Femoroacetabular impingement (FAI) Syndrome with cam-type abnormality is the preferred term to use for hip-related pain due to a bony bump at any location around the femoral head-neck junction	.705	.312	.971	.373	.261	.451	.482	.088	.828	.658

31_Femoroacetabular impingement (FAI) Syndrome with cam-type deformity is the preferred term to use for hip-related pain due to a bony bump at any location around the femoral head-neck junction	.468	.312	.911	.655	.196	.282	.421	.089	.729	.555

Table SF7-11 Kruskal-Wallis test to compare Radiologists vs other stakeholder groups (p-values)

	Radiologists vs Orthopaedic surgeons		Radiologists vs PPI		Radiologists vs Physical Therapists		Radiologists vs Physicians		Radiologists vs Researchers	
Statement	Round 1	Round 2	Round 1	Round 2	Round 1	Round 2	Round 1	Round 2	Round 1	Round 2
13_Cam morphology is the preferred term to use for a bone/cartilage bump at any location around the femoral head-neck junction	.044	.014	1.000	.853	.450	.532	.884	.663	.335	.059
14_Cam lesion is the preferred term to use for a bone/cartilage bump at any location around the femoral head-neck junction	.271	.190	.480	.230	.968	.884	.873	.523	.172	.058
15_Cam deformity is the preferred term to use for a bone/cartilage bump at any location around the femoral head-neck junction	.100	.009	.418	.011	.907	.069	.873	.089	.236	.004
16_Cam abnormality is the preferred term to use for a bone/cartilage bump at any location around the femoral head-neck junction	.064	.018	.231	.087	.263	.145	.264	.140	.061	.024
17_Cam-type deformity is the preferred term to use for a bone/cartilage bump at any location	.301	.018	.561	.024	.907	.069	.709	.140	.157	.010

around the femoral head-neck junction										
18_Cam-type abnormality is the preferred term to use for a bone/cartilage bump at any location around the femoral head-neck junction	.383	.018	.738	.087	.756	.144	.571	.140	.321	.052
19_Cam-type lesion is the preferred term to use for a bone/cartilage bump at any location around the femoral head-neck junction	.057	.008	.205	.048	.320	.144	.264	.140	.022	.052
20_Pistol grip deformity is the preferred term to use for a bone/cartilage bump at any location around the femoral head-neck junction	.533	.105	.462	.258	.436	.203	.455	.324	.451	.173
21_Pistol grip lesion is the preferred term to use for a bone/cartilage bump at any location around the femoral head-neck junction	.906	.174	.833	.258	.968	.203	.867	.324	.345	.171
22_Pistol grip abnormality is the preferred term to use for a bone/cartilage bump at any location around the femoral head-neck junction	.768	.348	.888	.750	.689	.915	.522	.945	.103	.255
23_Cam-type impingement is the preferred term to use for hip-related pain due to a bony bump at any location around the femoral head-neck junction	.058	.033	.326	.104	.759	.389	.265	.156	.029	.038
24_Cam femoroacetabular impingement (FAI) is the preferred term to use for hip-related pain due to	.675	.081	.206	.017	.825	.109	.731	.036	.011	.003

a bony bump at any location around the femoral head-neck junction										
25_Cam-type femoroacetabular impingement (FAI) is the preferred term to use for hip-related pain due to a bony bump at any location around the femoral head-neck junction	.959	.276	.507	.178	.913	.441	.961	.366	.385	.162
26_Femoroacetabular impingement (FAI) Syndrome with cam morphology is the preferred term to use for hip-related pain due to a bony bump at any location around the femoral head-neck junction	.063	.021	.261	.382	.124	.569	.883	.760	.067	.173
27_Femoroacetabular impingement (FAI) Syndrome with cam deformity is the preferred term to use for hip-related pain due	.174	.009	.477	.047	.968	.101	.451	.055	.298	.023
28_Femoroacetabular impingement (FAI) Syndrome with cam abnormality is the preferred term to use for hip-related pain due to a bony bump at any location around the femoral head-neck junction	.295	.009	.739	.086	.968	.102	.482	.055	.365	.052
29_Femoroacetabular impingement (FAI) Syndrome with cam lesion is the preferred term to use for hip-related pain due to a bony bump at any location around the femoral head-neck junction	.295	.009	.480	.047	.901	.142	.452	.089	.208	.024
30_Femoroacetabular impingement (FAI) Syndrome with cam-type abnormality is the preferred term to use for hip-related pain due to a bony	.296	.009	.418	.012	.905	.101	.482	.088	.327	.052

bump at any location around the femoral head-neck junction										
31_Femoroacetabular impingement (FAI) Syndrome with cam-type deformity is the preferred term to use for hip-related pain due to a bony bump at any location around the femoral head-neck junction	.210	.009	.442	.048	.968	.144	.421	.089	.208	.023

Table SF7-12 Kruskal-Wallis test to compare Researchers vs other stakeholder groups (p-values)

	Researchers vs Orthopaedic surgeons		Researchers vs PPI		Researchers vs Physical Therapists		Researchers vs Physicians		Researchers vs Radiologists	
Statement	Round 1	Round 2	Round 1	Round 2	Round 1	Round 2	Round 1	Round 2	Round 1	Round 2
13_Cam morphology is the preferred term to use for a bone/cartilage bump at any location around the femoral head-neck junction	.117	.065	.342	.037	.075	.012	.413	.089	.335	.059
14_Cam lesion is the preferred term to use for a bone/cartilage bump at any location around the femoral head-neck junction	.925	.637	.869	.539	.013	.000	.231	.045	.172	.058
15_Cam deformity is the preferred term to use for a bone/cartilage bump at any location around the femoral head-neck junction	.337	.967	.665	.290	.045	.010	.171	.062	.236	.004
16_Cam abnormality is the preferred term to use for a bone/cartilage bump at any location around the femoral head-neck junction	.853	.764	.372	.317	.113	.070	.282	.227	.061	.024
17_Cam-type deformity is the preferred term to use for a	.781	.832	.224	.610	.027	.065	.200	.207	.157	.010

bone/cartilage bump at any location around the femoral head-neck junction										
18_Cam-type abnormality is the preferred term to use for a bone/cartilage bump at any location around the femoral head-neck junction	.814	.698	.537	.732	.265	.172	.564	.455	.321	.052
19_Cam-type lesion is the preferred term to use for a bone/cartilage bump at any location around the femoral head-neck junction	.926	.437	.441	.962	.028	.172	.158	.506	.022	.052
20_Pistol grip deformity is the preferred term to use for a bone/cartilage bump at any location around the femoral head-neck junction	.156	.957	.159	.555	.069	.558	.110	.428	.451	.173
21_Pistol grip lesion is the preferred term to use for a bone/cartilage bump at any location around the femoral head-neck junction	.141	.863	.158	.598	.074	.558	.148	.496	.345	.171
22_Pistol grip abnormality is the preferred term to use for a bone/cartilage bump at any location around the femoral head-neck junction	.156	.641	.158	.331	.103	.143	.366	.231	.103	.255
23_Cam-type impingement is the preferred term to use for hip-related pain due to a bony bump at any location around the femoral head-neck junction	.713	.646	.046	.459	.003	.033	.213	.351	.029	.038
24_Cam femoroacetabular impingement (FAI) is the preferred	.019	.081	.052	.236	.000	.001	.003	.023	.011	.003

term to use for hip-related pain due to a bony bump at any location around the femoral head-neck junction										
25_Cam-type femoroacetabular impingement (FAI) is the preferred term to use for hip-related pain due to a bony bump at any location around the femoral head-neck junction	.613	.890	.667	.428	.191	.672	.275	.777	.385	.162
26_Femoroacetabular impingement (FAI) Syndrome with cam morphology is the preferred term to use for hip-related pain due to a bony bump at any location around the femoral head-neck junction	.271	.119	.626	.879	.974	.349	.179	.098	.067	.173
27_Femoroacetabular impingement (FAI) Syndrome with cam deformity is the preferred term to use for hip-related pain due	.270	.129	.869	.674	.138	.217	1.000	.908	.298	.023
28_Femoroacetabular impingement (FAI) Syndrome with cam abnormality is the preferred term to use for hip-related pain due to a bony bump at any location around the femoral head-neck junction	.889	.522	.542	.695	.183	.306	.862	.783	.365	.052
29_Femoroacetabular impingement (FAI) Syndrome with cam lesion is the preferred term to use for hip-related pain due to a bony bump at any location around the femoral head-neck junction	.963	.445	.829	.888	.048	.045	.729	.409	.208	.024
30_Femoroacetabular impingement (FAI) Syndrome with cam-type abnormality is the preferred term to	.963	.639	.871	.712	.232	.261	.828	.658	.327	.052

use for hip-related pain due to a bony bump at any location around the femoral head-neck junction										
31_Femoroacetabular impingement (FAI) Syndrome with cam-type deformity is the preferred term to use for hip-related pain due to a bony bump at any location around the femoral head-neck junction	.614	.525	.957	1.000	.064	.054	.729	.555	.208	.023

Taxonomy - Delphi domain 3

Stakeholder group analysis indicated the average scores for taxonomy statement 32 were statistically significant different for PPI group compared to the: (1) Orthopaedic Surgeon stakeholder group (round 2, p<0.005); (2) Physical Therapist stakeholder group (round 1 and 2, p<0.002); (3) Radiologist stakeholder group (round 1, p<0.003; round 2, p<0.002), and (4) Researcher stakeholder group (round 2, p<0.002). The difference in how the PPI stakeholder group compared to the Physical Therapist stakeholder group scored statement 34, was statistically significant (round 1, p<0.005; round 2, p<0.003).

Table SF7-13 Kruskal-Wallis test to compare Orthopaedic Surgeons vs other stakeholder groups (p-values)

	Orthopaedic surgeons vs PPI		Orthopaedic surgeons vs physical therapists		Orthopaedic surgeons vs physicians		Orthopaedic surgeons vs radiologists		Orthopaedic surgeons vs researchers	
Statement	Round 1	Round 2	Round 1	Round 2	Round 1	Round 2	Round 1	Round 2	Round 1	Round 2
32_We should distinguish between primary and secondary cam morphology in clinical practice	.011	.003	.847	.772	.526	.293	.918	.469	.564	.326
33_We should distinguish between primary and secondary cam morphology in research	.637	.144	.509	.590	.346	1.000	.516	1.000	.325	.473
34_We should distinguish between primary and secondary cam morphology in patients with femoroacetabular impingement syndrome	.030	.007	.829	.631	.324	.222	.325	.227	.721	.854
35_We should distinguish between primary and secondary cam morphology in research participants with femoroacetabular impingement syndrome	.178	.032	.810	.250	.922	.351	.955	.336	.450	.698

Table SF7-14 Kruskal Wallis test to compare Patient & Public Involvement Group (PPI) vs other stakeholder groups

	PPI vs Orthopaedic surgeons		PPI vs physical therapists		PPI vs physicians		PPI vs radiologists		PPI vs researchers	
Statement	Round 1	Round 2	Round 1	Round 2	Round 1	Round 2	Round 1	Round 2	Round 1	Round 2
32_We should distinguish between primary and secondary cam morphology in clinical practice	.011	.003	.001	.001	.005	.003	.002	.001	.006	.001

33_We should distinguish between primary and secondary cam morphology in research	.637	.144	.279	.255	.156	.084	.290	.133	.219	.017
34_We should distinguish between primary and secondary cam morphology in patients with femoroacetabular impingement syndrome	.030	.007	.003	.002	.031	.012	.122	.017	.024	.004
35_We should distinguish between primary and secondary cam morphology in research participants with femoroacetabular impingement syndrome	.178	.032	.114	.161	.089	.086	.150	.133	.025	.016

Table SF7-15 Kruskal-Wallis test to compare Physical Therapists vs other stakeholder groups (p-values)

	Physical Therapists vs Orthopaedic surgeons		Physical therapists vs PPI		Physical Therapists vs physicians		Physical Therapists vs radiologists		Physical Therapists vs researchers	
Statement	Round 1	Round 2	Round 1	Round 2	Round 1	Round 2	Round 1	Round 2	Round 1	Round 2
32_We should distinguish between primary and secondary cam morphology in clinical practice	.847	.772	.001	.001	.175	.299	.695	.446	.123	.275
33_We should distinguish between primary and secondary cam morphology in research	.509	.590	.279	.255	.714	.451	.938	.619	.899	.150
34_We should distinguish between primary and secondary cam morphology in patients with femoroacetabular impingement syndrome	.829	.631	.003	.002	.070	.242	.070	.084	.286	.948
35_We should distinguish between primary and secondary cam morphology in research participants with femoroacetabular impingement syndrome	.810	.250	.114	.161	.981	.722	.907	.904	.553	.279

Table SF7-16 Kruskal-Wallis test to compare Physicians vs other stakeholder groups (p-values)

	Physicians vs Orthopaedic surgeons		Physicians vs PPI		Physicians vs Physical Therapists		Physicians vs radiologists		Physicians vs researchers	
Statement	Round 1	Round 2	Round 1	Round 2	Round 1	Round 2	Round 1	Round 2	Round 1	Round 2
32_We should distinguish between primary and secondary cam morphology in clinical practice	.526	.293	.005	.003	.175	.299	.496	.852	.646	.908
33_We should distinguish between primary and secondary cam morphology in research	.346	1.000	.156	.084	.714	.451	.814	.665	.668	.815
34_We should distinguish between primary and secondary cam morphology in patients with femoroacetabular impingement syndrome	.324	.222	.031	.012	.070	.242	.580	.510	.651	.349
35_We should distinguish between primary and secondary cam morphology in research participants with femoroacetabular impingement syndrome	.922	.351	.089	.086	.981	.722	.774	.772	.729	.508

Table SF7-17 Kruskal-Wallis test to compare Radiologists vs other stakeholder groups (p-values)

	Radiologists vs Orthopaedic surgeons		Radiologists vs PPI		Radiologists vs Physical Therapists		Radiologists vs Physicians		Radiologists vs Researchers	
Statement	Round 1	Round 2	Round 1	Round 2	Round 1	Round 2	Round 1	Round 2	Round 1	Round 2
32_We should distinguish between primary and secondary cam morphology in clinical practice	.918	.469	.002	.001	.695	.446	.496	.852	.343	.705
33_We should distinguish between primary and secondary cam morphology in research	.516	1.000	.290	.133	.938	.619	.814	.665	.942	.352
34_We should distinguish between primary and secondary cam morphology in patients with femoroacetabular impingement syndrome	.325	.227	.122	.017	.070	.084	.580	.510	.315	.102

35_We should distinguish between primary and secondary cam morphology in research participants with femoroacetabular impingement syndrome	.955	.336	.150	.133	.907	.904	.774	.772	.524	.270

Table SF7-18 Kruskal-Wallis test to compare Researchers vs other stakeholder groups (p-values)

	Researchers vs Orthopaedic surgeons		Researchers vs PPI		Researchers vs Physical Therapists		Researchers vs Physicians		Researchers vs Radiologists	
Statement	Round 1	Round 2	Round 1	Round 2	Round 1	Round 2	Round 1	Round 2	Round 1	Round 2
32_We should distinguish between primary and secondary cam morphology in clinical practice	.564	.326	.006	.001	.123	.275	.646	.908	.343	.705
33_We should distinguish between primary and secondary cam morphology in research	.325	.473	.219	.017	.899	.150	.668	.815	.942	.352
34_We should distinguish between primary and secondary cam morphology in patients with femoroacetabular impingement syndrome	.721	.854	.024	.004	.286	.948	.651	.349	.315	.102
35_We should distinguish between primary and secondary cam morphology in research participants with femoroacetabular impingement syndrome	.450	.698	.025	.016	.553	.279	.729	.508	.524	.270

Imaging outcomes – Delphi domain 4

There was no statistically significant difference in how stakeholder groups scored the imaging outcomes statements in round 1 and 2 (stakeholder group analysis).

Table SF7-19 Kruskal-Wallis test to compare Orthopaedic Surgeons vs other stakeholder groups (p-values)

	Orthopaedic surgeons vs PPI		Orthopaedic surgeons vs physical therapists		Orthopaedic surgeons vs physicians		Orthopaedic surgeons vs radiologists		Orthopaedic surgeons vs researchers	
Statement	Round 1	Round 2	Round 1	Round 2	Round 1	Round 2	Round 1	Round 2	Round 1	Round 2
36_The main imaging modality for research on how primary cam morphology develops should be magnetic resonance (MR) with radial imaging (1.5T or 3 T)	.958	.553	1.000	.502	.787	.305	.713	1.000	.490	.883
37_The minimum acceptable number of radial sequence magnetic resonance (MR) imaging slices for research on how primary cam morphology develops should be 12 slices (30° intervals, in all 12 clock face positions from 12 o'clock to 11 o'clock positions)	.755	.390	.656	.426	.749	.174	.437	.177	.381	.208
38_Referring to precisely quantifying the asphericity of the femoral head-neck junction on radial sequence magnetic resonance (MR) imaging: use either radial sequences along the axis of the femoral neck (providing higher resolution images) or radial reconstructions from 3-dimensional acquisitions	.705	.944	.133	.251	.441	.272	.034	.026	.117	.142
39_ The magnetic resonance (MR) imaging protocol for research on how primary cam morphology develops	.388	.536	.256	.232	.546	.394	.082	.171	.731	.849

should include: (i) unilateral small field-of-view (FOV) sequences and radial images of a randomly selected or both hips, as well as (ii) femoral torsion assessment (fast axial sequences of the distal knee—femoral condyles—and proximal femoral neck), and (iii) a fluid sensitive sequence covering the whole pelvis (in axial or coronal planes, to screen for soft-tissue and bone marrow edema beyond the hip)										
40_The magnetic resonance (MR) imaging for prospective research on how primary cam morphology develops should be repeated every 18 to 24 months	.222	.270	.228	.382	.172	.215	.719	.620	.434	.780
41_In primary cam morphology epidemiological research (e.g.; when regression is being used in aetiology or prognosis research), continuous imaging outcome measures (variables), like the alpha angle, should be kept continuous	.759	.639	.170	.098	.971	.912	.809	.900	.248	.146
42_The cam morphology magnetic resonance (MR) imaging outcome measure for research on how primary cam morphology develops (aetiology), should be the alpha angle for bone and cartilage as a continuous variable, reported for all the o'clock locations around the femoral head-neck junction, regardless of the	.909	.960	1.000	.773	.679	.865	.956	1.000	.543	.920

symptomatic state of the research participant										
43_For research on how primary cam morphology develops it is important to quantify the epiphyseal morphology magnetic resonance (MR) imaging outcome measure using epiphyseal extension	.950	.803	.464	.424	.672	.900	.251	.490	.797	.342
44_ For research on how primary cam morphology develops the epiphyseal morphology magnetic resonance (MR) imaging outcome measure should also be quantified using epiphyseal tilt	.613	.559	.801	.538	.317	.843	.219	.173	.304	.208
45_The main imaging modality for longitudinal primary cam morphology prognosis research should be anteroposterior (AP) pelvis and Dunn 45° view radiographs repeated at least every 5 years	.104	.086	.314	.268	.189	.129	.150	.150	.202	.202
46_The radiographic imaging outcome measure for research on primary cam morphology prognosis should be the alpha angle as a continuous variable reported for anteroposterior (AP) pelvis and Dunn 45° view radiographs.	.130	.076	.170	.053	.588	.474	.093	.102	.216	.173
47_In addition to reporting alpha angles as continuous in studies on aetiology or prognosis, the following quantitative and qualitative imaging outcome measures, to categorise cam morphology, can be useful in research or clinical practice: (i) Alpha angle ≥ 60° (preferred) (ii) Head-neck offset <	.236	.332	.439	.816	.681	.723	.118	.248	.150	.102

8mm AND head-neck offset ratio ≤ 0.15 usually at the anterior (3 o'clock) location around the femoral head-neck junction (in addition to (i)); Osseous or cartilage convexity of the femoral head neck junction at any location (in addition to (i) and (ii))	

Table SF7-20 Kruskal-Wallis test to compare Patient & Public Involvement Group (PPI) vs other stakeholder groups

	PPI vs Orthopaedic surgeons		PPI vs physical therapists		PPI vs physicians		PPI vs radiologists		PPI vs researchers	
Statement	Round 1	Round 2	Round 1	Round 2	Round 1	Round 2	Round 1	Round 2	Round 1	Round 2
36_The main imaging modality for research on how primary cam morphology develops should be magnetic resonance (MR) with radial imaging (1.5T or 3 T)	.958	.553	.733	.625	.557	.503	.652	.447	.489	.916
37_The minimum acceptable number of radial sequence magnetic resonance (MR) imaging slices for research on how primary cam morphology develops should be 12 slices (30° intervals, in all 12 clock face positions from 12 o'clock to 11 o'clock positions)	.755	.390	1.000	.820	.940	.588	.456	.407	.439	.502
38_Referring to precisely quantifying the asphericity of the femoral head-neck junction on radial sequence magnetic resonance (MR) imaging: use either radial sequences along the axis of the femoral neck (providing higher resolution images) or radial	.705	.944	.443	.256	.714	.318	.081	.020	.139	.105

reconstructions from 3-dimensional acquisitions										
39_ The magnetic resonance (MR) imaging protocol for research on how primary cam morphology develops should include: (i) unilateral small field-of-view (FOV) sequences and radial images of a randomly selected or both hips, as well as (ii) femoral torsion assessment (fast axial sequences of the distal knee—femoral condyles—and proximal femoral neck), and (iii) a fluid sensitive sequence covering the whole pelvis (in axial or coronal planes, to screen for soft-tissue and bone marrow edema beyond the hip)	.388	.536	.725	.614	.508	.877	.433	.443	.637	.539
40_The magnetic resonance (MR) imaging for prospective research on how primary cam morphology develops should be repeated every 18 to 24 months	.222	.270	.905	.311	.848	.794	.371	.351	.801	.545
41_In primary cam morphology epidemiological research (e.g.; when regression is being used in aetiology or prognosis research), continuous imaging outcome measures (variables), like the alpha angle, should be kept continuous	.759	.639	.285	.196	.772	.379	.675	.622	.332	.207
42_The cam morphology magnetic resonance (MR) imaging outcome measure for research on how primary cam morphology develops (aetiology),	.909	.960	.966	.605	.366	.792	1.000	1.000	.405	.842

should be the alpha angle for bone and cartilage as a continuous variable, reported for all the o'clock locations around the femoral head-neck junction, regardless of the symptomatic state of the research participant										
43_For research on how primary cam morphology develops it is important to quantify the epiphyseal morphology magnetic resonance (MR) imaging outcome measure using epiphyseal extension	.950	.803	.453	.779	.608	.357	.135	.153	.879	.582
44_ For research on how primary cam morphology develops the epiphyseal morphology magnetic resonance (MR) imaging outcome measure should also be quantified using epiphyseal tilt	.613	.559	.493	.235	.595	.742	.209	.329	.279	.373
45_The main imaging modality for longitudinal primary cam morphology prognosis research should be anteroposterior (AP) pelvis and Dunn 45° view radiographs repeated at least every 5 years	.104	.086	.479	.313	.586	.533	1.000	.868	.667	.562
46_The radiographic imaging outcome measure for research on primary cam morphology prognosis should be the alpha angle as a continuous variable reported for anteroposterior (AP) pelvis and Dunn 45° view radiographs.	.130	.076	.776	.831	.455	.179	.707	.869	.636	.566
47_In addition to reporting alpha angles as continuous in studies on aetiology or prognosis, the following	.236	.332	.120	.114	.330	.170	.735	.788	.041	.031

quantitative and qualitative imaging outcome measures, to categorise cam morphology, can be useful in research or clinical practice: (i) Alpha angle ≥ 60° (preferred) (ii) Head-neck offset < 8mm AND head-neck offset ratio ≤ 0.15 usually at the anterior (3 o'clock) location around the femoral head-neck junction (in addition to (i)); Osseous or cartilage convexity of the femoral head neck junction at any location (in addition to (i) and (ii))	

Table SF7-21 Kruskal-Wallis test to compare Physical Therapists vs other stakeholder groups (-values)

	Physical Therapists vs Orthopaedic surgeons		Physical therapists vs PPI		Physical Therapists vs physicians		Physical Therapists vs radiologists		Physical Therapists vs researchers	
Statement	Round 1	Round 2	Round 1	Round 2	Round 1	Round 2	Round 1	Round 2	Round 1	Round 2
36_The main imaging modality for research on how primary cam morphology develops should be magnetic resonance (MR) with radial imaging (1.5T or 3 T)	1.000	.502	.733	.625	.841	.630	.522	.319	.348	.672
37_The minimum acceptable number of radial sequence magnetic resonance (MR) imaging slices for research on how primary cam morphology develops should be 12 slices (30° intervals, in all 12 clock face positions from 12 o'clock to 11 o'clock positions)	.656	.426	1.000	.820	.940	.365	.784	.258	.360	.364

38_Referring to precisely quantifying the asphericity of the femoral head-neck junction on radial sequence magnetic resonance (MR) imaging: use either radial sequences along the axis of the femoral neck (providing higher resolution images) or radial reconstructions from 3-dimensional acquisitions	.133	.251	.443	.256	.711	.975	.289	.210	.423	.419
39_ The magnetic resonance (MR) imaging protocol for research on how primary cam morphology develops should include: (i) unilateral small field-of-view (FOV) sequences and radial images of a randomly selected or both hips, as well as (ii) femoral torsion assessment (fast axial sequences of the distal knee—femoral condyles—and proximal femoral neck), and (iii) a fluid sensitive sequence covering the whole pelvis (in axial or coronal planes, to screen for soft-tissue and bone marrow edema beyond the hip)	.256	.232	.725	.614	.513	.671	.446	.609	.486	.292
40_The magnetic resonance (MR) imaging for prospective research on how primary cam morphology develops should be repeated every 18 to 24 months	.228	.382	.905	.311	.862	.372	.543	.823	.752	.968
41_In primary cam morphology epidemiological research (e.g.; when regression is being used in aetiology or prognosis research), continuous	.170	.098	.285	.196	.187	.117	.177	.181	.908	.936

imaging outcome measures (variables), like the alpha angle, should be kept continuous										
42_The cam morphology magnetic resonance (MR) imaging outcome measure for research on how primary cam morphology develops (aetiology), should be the alpha angle for bone and cartilage as a continuous variable, reported for all the o'clock locations around the femoral head-neck junction, regardless of the symptomatic state of the research participant	1.000	.773	.966	.605	.471	.448	.966	.682	.490	.854
43_For research on how primary cam morphology develops it is important to quantify the epiphyseal morphology magnetic resonance (MR) imaging outcome measure using epiphyseal extension	.464	.424	.453	.779	.160	.386	.061	.130	.795	.713
44_ For research on how primary cam morphology develops the epiphyseal morphology magnetic resonance (MR) imaging outcome measure should also be quantified using epiphyseal tilt	.801	.538	.493	.235	.220	.301	.116	.051	.221	.066
45_The main imaging modality for longitudinal primary cam morphology prognosis research should be anteroposterior (AP) pelvis and Dunn 45° view radiographs repeated at least every 5 years	.314	.268	.479	.313	.760	.715	.420	.395	.801	.734
46_The radiographic imaging outcome measure for research on primary cam	.170	.053	.776	.831	.540	.185	.525	.735	.833	.701

morphology prognosis should be the alpha angle as a continuous variable reported for anteroposterior (AP) pelvis and Dunn 45° view radiographs.										
47_In addition to reporting alpha angles as continuous in studies on aetiology or prognosis, the following quantitative and qualitative imaging outcome measures, to categorise cam morphology, can be useful in research or clinical practice: (i) Alpha angle ≥ 60° (preferred) (ii) Head-neck offset < 8mm AND head-neck offset ratio ≤ 0.15 usually at the anterior (3 o'clock) location around the femoral head-neck junction (in addition to (i)); Osseous or cartilage convexity of the femoral head neck junction at any location (in addition to (i) and (ii))	.439	.816	.120	.114	.197	.370	.054	.074	.584	.066

Table SF7-22 Kruskal-Wallis test to compare Physicians vs other stakeholder groups (p-values)

	Physicians vs Orthopaedic surgeons		Physicians vs PPI		Physicians vs Physical Therapists		Physicians vs radiologists		Physicians vs researchers	
Statement	Round 1	Round 2	Round 1	Round 2	Round 1	Round 2	Round 1	Round 2	Round 1	Round 2
36_The main imaging modality for research on how primary cam morphology develops should be magnetic resonance (MR) with radial imaging (1.5T or 3 T)	.787	.305	.557	.503	.841	.630	.391	.266	.290	.515
37_The minimum acceptable number of radial sequence magnetic	.749	.174	.940	.588	.940	.365	.642	.726	.386	.817

resonance (MR) imaging slices for research on how primary cam morphology develops should be 12 slices (30° intervals, in all 12 clock face positions from 12 o'clock to 11 o'clock positions)										
38_Referring to precisely quantifying the asphericity of the femoral head-neck junction on radial sequence magnetic resonance (MR) imaging: use either radial sequences along the axis of the femoral neck (providing higher resolution images) or radial reconstructions from 3-dimensional acquisitions	.441	.272	.714	.318	.711	.975	.129	.335	.213	.530
39_ The magnetic resonance (MR) imaging protocol for research on how primary cam morphology develops should include: (i) unilateral small field-of-view (FOV) sequences and radial images of a randomly selected or both hips, as well as (ii) femoral torsion assessment (fast axial sequences of the distal knee—femoral condyles—and proximal femoral neck), and (iii) a fluid sensitive sequence covering the whole pelvis (in axial or coronal planes, to screen for soft-tissue and bone marrow edema beyond the hip)	.546	.394	.508	.877	.513	.671	.186	.484	.896	.451
40_The magnetic resonance (MR) imaging for prospective research on how primary cam morphology	.172	.215	.848	.794	.862	.372	.424	.554	.634	.443

develops should be repeated every 18 to 24 months										
41_In primary cam morphology epidemiological research (e.g.; when regression is being used in aetiology or prognosis research), continuous imaging outcome measures (variables), like the alpha angle, should be kept continuous	.971	.912	.772	.379	.187	.117	.923	.589	.248	.117
42_The cam morphology magnetic resonance (MR) imaging outcome measure for research on how primary cam morphology develops (aetiology), should be the alpha angle for bone and cartilage as a continuous variable, reported for all the o'clock locations around the femoral head-neck junction, regardless of the symptomatic state of the research participant	.679	.865	.366	.792	.471	.448	.619	.885	.307	.692
43_For research on how primary cam morphology develops it is important to quantify the epiphyseal morphology magnetic resonance (MR) imaging outcome measure using epiphyseal extension	.672	.900	.608	.357	.160	.386	.179	.302	.655	.369
44_ For research on how primary cam morphology develops the epiphyseal morphology magnetic resonance (MR) imaging outcome measure should also be quantified using epiphyseal tilt	.317	.843	.595	.742	.220	.301	.432	.099	.529	.144
45_The main imaging modality for longitudinal primary cam morphology	.189	.129	.586	.533	.760	.715	.809	.737	.892	.850

prognosis research should be anteroposterior (AP) pelvis and Dunn 45° view radiographs repeated at least every 5 years										
46_The radiographic imaging outcome measure for research on primary cam morphology prognosis should be the alpha angle as a continuous variable reported for anteroposterior (AP) pelvis and Dunn 45° view radiographs.	.588	.474	.455	.179	.540	.185	.501	.414	.632	.414
47_In addition to reporting alpha angles as continuous in studies on aetiology or prognosis, the following quantitative and qualitative imaging outcome measures, to categorise cam morphology, can be useful in research or clinical practice: (i) Alpha angle ≥ 60° (preferred) (ii) Head-neck offset < 8mm AND head-neck offset ratio ≤ 0.15 usually at the anterior (3 o'clock) location around the femoral head-neck junction (in addition to (i)); Osseous or cartilage convexity of the femoral head neck junction at any location (in addition to (i) and (ii))	.681	.723	.330	.170	.197	.370	.153	.211	.054	.019

Table SF7-23 Kruskal-Wallis test to compare Radiologists vs other stakeholder groups (p-values)

	Radiologists vs Orthopaedic surgeons		Radiologists vs PPI		Radiologists vs Physical Therapists		Radiologists vs Physicians		Radiologists vs Researchers	
Statement	Round 1	Round 2	Round 1	Round 2	Round 1	Round 2	Round 1	Round 2	Round 1	Round 2

36_The main imaging modality for research on how primary cam morphology develops should be magnetic resonance (MR) with radial imaging (1.5T or 3 T)	.713	1.000	.652	.447	.522	.319	.391	.266	.733	.724
37_The minimum acceptable number of radial sequence magnetic resonance (MR) imaging slices for research on how primary cam morphology develops should be 12 slices (30° intervals, in all 12 clock face positions from 12 o'clock to 11 o'clock positions)	.437	.177	.456	.407	.784	.258	.642	.726	.892	.892
38_Referring to precisely quantifying the asphericity of the femoral head-neck junction on radial sequence magnetic resonance (MR) imaging: use either radial sequences along the axis of the femoral neck (providing higher resolution images) or radial reconstructions from 3-dimensional acquisitions	.034	.026	.081	.020	.289	.210	.129	.335	.855	1.000
39_ The magnetic resonance (MR) imaging protocol for research on how primary cam morphology develops should include: (i) unilateral small field-of-view (FOV) sequences and radial images of a randomly selected or both hips, as well as (ii) femoral torsion assessment (fast axial sequences of the distal knee—femoral condyles—and proximal femoral neck), and (iii) a fluid sensitive	.082	.171	.433	.443	.446	.609	.186	.484	.219	.219

sequence covering the whole pelvis (in axial or coronal planes, to screen for soft-tissue and bone marrow edema beyond the hip)										
40_The magnetic resonance (MR) imaging for prospective research on how primary cam morphology develops should be repeated every 18 to 24 months	.719	.620	.371	.351	.543	.823	.424	.554	.659	.926
41_In primary cam morphology epidemiological research (e.g.; when regression is being used in aetiology or prognosis research), continuous imaging outcome measures (variables), like the alpha angle, should be kept continuous	.809	.900	.675	.622	.177	.181	.923	.589	.208	.170
42_The cam morphology magnetic resonance (MR) imaging outcome measure for research on how primary cam morphology develops (aetiology), should be the alpha angle for bone and cartilage as a continuous variable, reported for all the o'clock locations around the femoral head-neck junction, regardless of the symptomatic state of the research participant	.956	1.000	1.000	1.000	.966	.682	.619	.885	.604	.882
43_For research on how primary cam morphology develops it is important to quantify the epiphyseal morphology magnetic resonance (MR) imaging outcome measure using epiphyseal extension	.251	.490	.135	.153	.061	.130	.179	.302	.208	.167

44_ For research on how primary cam morphology develops the epiphyseal morphology magnetic resonance (MR) imaging outcome measure should also be quantified using epiphyseal tilt	.219	.173	.209	.329	.116	.051	.432	.099	.586	.899
45_The main imaging modality for longitudinal primary cam morphology prognosis research should be anteroposterior (AP) pelvis and Dunn 45° view radiographs repeated at least every 5 years	.150	.150	1.000	.868	.420	.395	.809	.737	.711	.711
46_The radiographic imaging outcome measure for research on primary cam morphology prognosis should be the alpha angle as a continuous variable reported for anteroposterior (AP) pelvis and Dunn 45° view radiographs.	.093	.102	.707	.869	.525	.735	.501	.414	.415	.572
47_In addition to reporting alpha angles as continuous in studies on aetiology or prognosis, the following quantitative and qualitative imaging outcome measures, to categorise cam morphology, can be useful in research or clinical practice: (i) Alpha angle ≥ 60° (preferred) (ii) Head-neck offset < 8mm AND head-neck offset ratio ≤ 0.15 usually at the anterior (3 o'clock) location around the femoral head-neck junction (in addition to (i)); Osseous or cartilage convexity of the femoral head neck junction at any location (in addition to (i) and (ii))	.118	.248	.735	.788	.054	.074	.153	.211	.007	.009

Table SF7-24 Kruskal-Wallis test to compare Researchers vs other stakeholder groups (p-values)

	Researchers vs Orthopaedic surgeons		Researchers vs PPI		Researchers vs Physical Therapists		Researchers vs Physicians		Researchers vs Radiologists	
Statement	Round 1	Round 2	Round 1	Round 2	Round 1	Round 2	Round 1	Round 2	Round 1	Round 2
36_The main imaging modality for research on how primary cam morphology develops should be magnetic resonance (MR) with radial imaging (1.5T or 3 T)	.490	.883	.489	.916	.348	.672	.290	.515	.733	.724
37_The minimum acceptable number of radial sequence magnetic resonance (MR) imaging slices for research on how primary cam morphology develops should be 12 slices (30° intervals, in all 12 clock face positions from 12 o'clock to 11 o'clock positions)	.381	.208	.439	.502	.360	.364	.386	.817	.892	.892
38_Referring to precisely quantifying the asphericity of the femoral head-neck junction on radial sequence magnetic resonance (MR) imaging: use either radial sequences along the axis of the femoral neck (providing higher resolution images) or radial reconstructions from 3-dimensional acquisitions	.117	.142	.139	.105	.423	.419	.213	.530	.855	1.000
39_ The magnetic resonance (MR) imaging protocol for research on how primary cam morphology develops should include: (i) unilateral small field-of-view (FOV) sequences and radial images of a randomly selected	.731	.849	.637	.539	.486	.292	.896	.451	.219	.219

or both hips, as well as (ii) femoral torsion assessment (fast axial sequences of the distal knee—femoral condyles—and proximal femoral neck), and (iii) a fluid sensitive sequence covering the whole pelvis (in axial or coronal planes, to screen for soft-tissue and bone marrow edema beyond the hip)										
40_The magnetic resonance (MR) imaging for prospective research on how primary cam morphology develops should be repeated every 18 to 24 months	.434	.780	.801	.545	.752	.968	.634	.443	.659	.926
41_In primary cam morphology epidemiological research (e.g.; when regression is being used in aetiology or prognosis research), continuous imaging outcome measures (variables), like the alpha angle, should be kept continuous	.248	.146	.332	.207	.908	.936	.248	.117	.208	.170
42_The cam morphology magnetic resonance (MR) imaging outcome measure for research on how primary cam morphology develops (aetiology), should be the alpha angle for bone and cartilage as a continuous variable, reported for all the o'clock locations around the femoral head-neck junction, regardless of the symptomatic state of the research participant	.543	.920	.405	.842	.490	.854	.307	.692	.604	.882

43_For research on how primary cam morphology develops it is important to quantify the epiphyseal morphology magnetic resonance (MR) imaging outcome measure using epiphyseal extension	.797	.342	.879	.582	.795	.713	.655	.369	.208	.167
44_ For research on how primary cam morphology develops the epiphyseal morphology magnetic resonance (MR) imaging outcome measure should also be quantified using epiphyseal tilt	.304	.208	.279	.373	.221	.066	.529	.144	.586	.899
45_The main imaging modality for longitudinal primary cam morphology prognosis research should be anteroposterior (AP) pelvis and Dunn 45° view radiographs repeated at least every 5 years	.202	.202	.667	.562	.801	.734	.892	.850	.711	.711
46_The radiographic imaging outcome measure for research on primary cam morphology prognosis should be the alpha angle as a continuous variable reported for anteroposterior (AP) pelvis and Dunn 45° view radiographs.	.216	.173	.636	.566	.833	.701	.632	.414	.415	.572
47_In addition to reporting alpha angles as continuous in studies on aetiology or prognosis, the following quantitative and qualitative imaging outcome measures, to categorise cam morphology, can be useful in research or clinical practice: (i) Alpha angle ≥ 60° (preferred) (ii) Head-neck offset < 8mm AND head-neck offset ratio ≤ 0.15 usually at the anterior (3 o'clock)	.150	.102	.041	.031	.584	.066	.054	.019	.007	.009

location around the femoral head-neck junction (in addition to (i)); Osseous or cartilage convexity of the femoral head neck junction at any location (in addition to (i) and (ii))	

References

1 Beiderbeck D, Frevel N, von der Gracht HA, *et al.* Preparing, conducting, and analyzing Delphi surveys: Cross-disciplinary practices, new directions, and advancements. *MethodsX* 2021;**8**:101401. doi:10.1016/j.mex.2021.101401

2 Beiderbeck D, Frevel N, von der Gracht HA, *et al.* The impact of COVID-19 on the European football ecosystem – A Delphi-based scenario analysis. *Technol Forecast Soc Change* 2021;**165**:120577. doi:10.1016/j.techfore.2021.120577

3 Wasserstein RL, Schirm AL, Lazar NA. Moving to a World Beyond "p < 0.05". *Am Stat* 2019;**73**:1–19. doi:10.1080/00031305.2019.1583913